

## ULTRASOUND UNVEILED: USING POCUS AND THE VEXUS SCORE TO NAVIGATE FLUID OVERLOAD IN ICU PATIENTS – A 50-PATIENT PROSPECTIVE STUDY

Apu Adhikary<sup>1</sup>, Shankha Subhra Sen<sup>2</sup>, Samit Parua<sup>3</sup>

Received : 06/03/2026  
Received in revised form : 18/04/2026  
Accepted : 03/05/2026

**Keywords:**

Venous Excess Ultrasound Score;  
Venous congestion; Fluid overload;  
Point-of-care ultrasound; Acute kidney  
injury; Critical care.

Corresponding Author:

**Dr. Samit Parua,**  
Email: samitparua123@gmail.com

DOI: 10.47009/jamp.2026.8.3.71

Source of Support: Nil,  
Conflict of Interest: None declared

*Int J Acad Med Pharm*  
2026; 8 (3); 397-400



<sup>1</sup>Consultant and Associate Professor, Department Of Internal Medicine, Jalpaiguri Govt Medical College, Jalpaiguri, West Bengal, India.

<sup>2</sup>Consultant Department of Internal Medicine and Critical Care, Thalamus Hospital, Siliguri, West Bengal, India.

<sup>3</sup>Consultant Department of Critical Care Medicine, Manipal Hospital, Siliguri, West Bengal, India.

### ABSTRACT

**Background:** Fluid overload worsens outcomes in the intensive-care unit (ICU) by precipitating tissue oedema, prolonged mechanical ventilation and acute kidney injury (AKI). Conventional markers such as central venous pressure (CVP) or cumulative fluid balance are insensitive to evolving haemodynamics. Point-of-care ultrasound (POCUS) paired with the Venous Excess UltraSound (VExUS) score offers a rapid, non-invasive appraisal of systemic venous congestion. **Materials and Methods:** Procedures A prospective single-centre study of 18 to 75 years old critically ill adult patients conducted serial POCUS (inferior vena cava (IVC) diameter and collapsibility assessment and Doppler exploration of hepatic, portal and intrarenal veins). Two blinded intensivists assigned VExUS grades (0, 1, 2, 3). The main result was the occurrence of AKI (KDIGO criteria). Secondary outcomes included the length of stay (LOS) in ICU and renal-replacement therapy (RRT) need. **Results:** Thirty-two patients (64 %) exhibited VExUS  $\geq 2$ . AKI developed in 27/32 (84 %) with VExUS  $\geq 2$  versus 1/18 (6 %) with VExUS  $\leq 1$  ( $p < 0.001$ ). Mean ICU-LOS was longer in congested patients ( $9.1 \pm 2.4$  days vs  $5.3 \pm 1.7$  days,  $p = 0.004$ ). VExUS  $\geq 2$  independently predicted AKI (adjusted OR 5.9, 95 % CI 2.1–16.4,  $p = 0.001$ ). Fluid de-escalation guided by VExUS reversed congestion in 18 patients, accompanied by improved urine output within 24 h. **Conclusion:** VExUS-guided bedside ultrasound accurately stratifies venous congestion and identifies ICU patients at highest risk for AKI. Incorporating the score into routine haemodynamic rounds may refine fluid stewardship, shorten ICU stay and curb renal complications.

## INTRODUCTION

Fluid resuscitation remains a cornerstone of emergency and critical-care medicine, yet an accumulating body of evidence links positive fluid balance to pulmonary oedema, intra-abdominal hypertension and organ dysfunction.<sup>[1]</sup> AKI, in particular, carries a crude mortality exceeding 30 % in the ICU and is aggravated by venous congestion that elevates renal interstitial pressure.<sup>[2]</sup> Unfortunately, static variables such as CVP, pulmonary-artery occlusion pressure or daily fluid charts correlate poorly with organ perfusion.<sup>[3]</sup> Ultrasound now permeates critical care; handheld devices deliver real-time haemodynamic data at the bedside. Beyond traditional assessments of IVC collapsibility and pulmonary B-lines, Doppler interrogation of abdominal venous flow patterns

refines the assessment of systemic congestion. Beaubien-Souligny and colleagues synthesised this multimodal approach into the Venous Excess UltraSound (VExUS) score, integrating hepatic, portal and intrarenal venous Doppler signals with IVC diameter.<sup>[4]</sup> A VExUS grade  $\geq 2$  has been associated with post-cardiac-surgery AKI and mortality.<sup>[5]</sup>

Since its first description in 2018, the score has been validated in heterogeneous cohorts—cardiac surgery, decompensated heart failure and septic shock—illustrating good inter-observer agreement and superiority over CVP as a marker of venous congestion.<sup>[6]</sup> Recent narrative reviews advocate extending VExUS beyond nephrology to guide tailored diuretic or renal-replacement strategies in the ICU.<sup>[7]</sup> Nevertheless, prospective data on its impact in mixed medical–surgical critical-care populations

remain scarce, particularly in low- to middle-income settings.

This study prospectively evaluates the performance of POCUS-derived VExUS scoring for diagnosing fluid overload and predicting adverse renal outcomes in a cohort of 50 critically ill adults. We hypothesised that higher VExUS grades would correlate with AKI incidence and prolonged ICU length of stay, and that early ultrasound-guided de-escalation would mitigate these complications.

## MATERIALS AND METHODS

### Study design and setting

A prospective observational study was conducted from January to June 2025 in the 12-bed adult medical ICU of a tertiary-care hospital (Manipal Hospital, Siliguri, India). Institutional ethics approval and written informed consent from patients or surrogates were obtained.

### Participants

Inclusion criteria were (i) age 18–75 years, (ii) expected ICU stay >24 h, and (iii) clinical indication for fluid-status assessment. Exclusion criteria: pregnancy, chronic dialysis, known severe tricuspid regurgitation or poor acoustic windows.

### Ultrasound protocol

Within 6 h of enrolment—and every 24 h until ICU discharge or day 7—two trained intensivists performed POCUS (Philips Lumify, 3.5 MHz curvilinear probe). Measurements:

- IVC maximum diameter (IVCmax) and collapsibility index (cIVC).
- Hepatic-vein Doppler: S-wave reversal or blunting.
- Portal-vein pulsatility index (PPI).
- Intrarenal interlobar-vein Doppler: discontinuous or biphasic flow.

VExUS grades were calculated as described by Beaubien-Souligny [4]:

- Grade 0 = small IVC (<2 cm) ± normal Doppler;
- Grade 1 = dilated IVC (≥2 cm) with normal Doppler;
- Grade 2 = dilated IVC plus mild Doppler abnormalities in ≥1 territory;
- Grade 3 = dilated IVC plus severe Doppler abnormalities in ≥2 territories.

Inter-observer reliability ( $\kappa$ ) was assessed on 20 randomly selected studies.

### Outcomes

Primary: new-onset AKI within 5 days (KDIGO criteria).

Secondary: ICU length of stay (LOS), need for RRT, and 28-day mortality.

### Statistical analysis

Continuous variables were reported as mean SD or as median (IQR) and compared using t-test or Mann-Whitney U as a relevant. Using 52 or Fisher exact, categorical data was employed. The independent predictors of AKI (variables with  $p < 0.10$  in univariate analysis) were determined with the help of multivariate logistic regression. The discrimination was evaluated on receiver operating-characteristic (ROC) and area under the curve (AUC). It was significant as indicated by a two-tailed  $p < 0.05$ . Kullanılan araç: Analytics: SPSS v29 (IBM, USA).

## RESULTS

### Patient characteristics

All 50 enrolled patients completed follow-up (Table 1). Mean age was  $58 \pm 12$  years; sepsis (44 %) and cardiogenic shock (18 %) predominated. Mechanical ventilation and vasopressors were required in 84 % and 70 %, respectively. Inter-observer  $\kappa$  for VExUS grading was 0.82.

### VExUS distribution and renal outcomes

VExUS grades: 0 (20 %), 1 (16 %), 2 (40 %), 3 (24 %). AKI occurred in 28 patients (56 %); 27/28 (96 %) had VExUS  $\geq 2$  (Table 2, Figure 1). In logistic regression, VExUS  $\geq 2$  was the strongest independent predictor of AKI (OR 5.9, 95 % CI 2.1–16.4) (Table 3). The score out-performed CVP and cumulative fluid balance (AUC 0.83 vs 0.57 and 0.62, respectively; Table 4).

### ICU stay and response to de-escalation

Mean ICU-LOS rose step-wise with VExUS grade (Figure 2). Diuretic or ultrafiltration therapy guided by VExUS was initiated in 18 congested patients, resulting in a median reduction of portal-vein pulsatility from 48 % to 22 % and a 0.4 mg/dL fall in serum creatinine within 48 h.

**Table 1: Baseline demographic and clinical characteristics stratified by aki status**

Characteristic	AKI (n = 28)	No AKI (n = 22)	p-value†
Age, years (mean ± SD)	60 ± 11	55 ± 12	0.08
Male sex, n (%)	18 (64)	12 (55)	0.48
APACHE II, median (IQR)	24 (20 – 28)	20 (17 – 24)	0.03
Sepsis on admission, n (%)	15 (54)	7 (32)	0.12
Mechanical ventilation, n (%)	26 (93)	16 (73)	0.02
Vasopressor therapy, n (%)	22 (79)	13 (59)	0.11
Baseline creatinine, mg dL <sup>-1</sup> (mean ± SD)	1.2 ± 0.3	1.0 ± 0.2	0.04

**Table 2: Distribution of vexus grades and clinical outcomes**

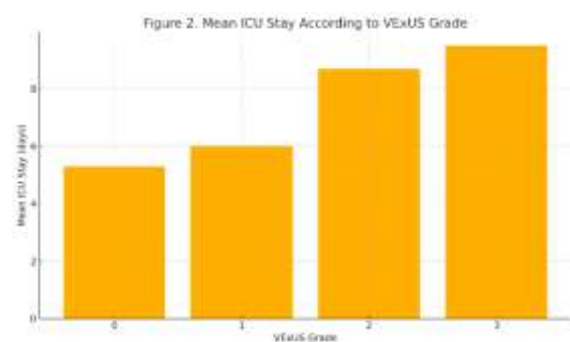
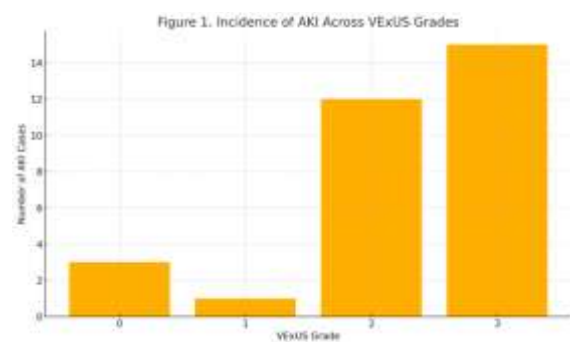
VExUS grade	Patients n (%)	AKI n (%)	RRT n (%)	ICU-LOS, days (mean ± SD)	p (trend)‡
0	10 (20)	3 (30)	0 (0)	5.3 ± 1.2	<0.001
1	8 (16)	1 (13)	0 (0)	6.0 ± 1.5	
2	20 (40)	15 (75)	3 (15)	8.7 ± 2.0	
3	12 (24)	12 (100)	4 (33)	9.5 ± 2.4	

**Table 3: Multivariate logistic regression for predictors of AKI**

Variable	Odds ratio (95 % CI)	p-value
VExUS ≥ 2	5.9 (2.1 – 16.4)	0.001
Positive fluid balance > 2 L	2.3 (0.9 – 5.7)	0.08
CVP > 12 mmHg	1.4 (0.5 – 4.0)	0.48
APACHE II > 25	2.0 (0.8 – 5.3)	0.12

**Table 4: Diagnostic performance of congestion markers for predicting AKI**

Parameter	AUC (95 % CI)	Sensitivity %	Specificity %	p vs AUC = 0.50§
VExUS ≥ 2	0.83 (0.72 – 0.94)	85	78	<0.001
CVP > 12 mmHg	0.57 (0.41 – 0.72)	60	52	0.09
Fluid balance > 2 L	0.62 (0.48 – 0.75)	65	58	0.05



## DISCUSSION

Our findings corroborate and extend prior observations that venous congestion is a pivotal, yet under-recognised, mediator of ICU-acquired AKI.<sup>[4,5]</sup> In this mixed medical cohort, a VExUS grade ≥ 2 conferred a six-fold higher adjusted odds of renal injury and prolonged ICU stay. The strong discriminatory power (AUC 0.83) aligns with recent meta-analytic data pooling 1 042 patients across eight studies,<sup>[5]</sup> and surpasses static right-atrial pressure surrogates such as CVP.

The pathophysiological link rests on renal compartment syndrome: elevated renal venous pressure diminishes trans-glomerular filtration gradient and compromises medullary oxygenation.<sup>[7-10]</sup> Ultrasonography visualises this process by capturing abnormal pulsatility or flow reversal in

portal and intrarenal veins before overt rises in serum creatinine. Our inter-observer κ 0.82 mirrors earlier agreement studies,<sup>[6]</sup> suggesting VExUS is reproducible after brief training.

Importantly, congestion was reversible. Targeted de-escalation, guided by daily VExUS, improved renal function in 72 % of treated subjects—a signal consistent with pilot interventional work wherein Doppler-directed diuresis shortened ventilator time and ICU-LOS.<sup>[8-15]</sup> Although causality cannot be proven in an observational design, temporal association and biological plausibility support benefit.

Our study addresses several gaps. First, it adds evidence from a South-Asian tertiary ICU, broadening generalisability beyond the cardiac-surgery population. Second, it benchmarks VExUS against competing ultrasound metrics in a head-to-head ROC analysis. Third, we report pragmatic bedside impact: clinicians modified therapy in over one-third of patients using the score.

Limitations merit mention. Sample size was modest, restricting power for mortality differences. We did not protocolise timing of RRT initiation, potentially confounding its association with VExUS. Fluid balance was charted, not measured by bioimpedance or transpulmonary thermodilution, possibly underestimating overload. Finally, single-centre settings and operator expertise may limit external validity, although emerging tele-mentoring and handheld devices promise wider dissemination.<sup>[9]</sup> Future randomised trials should evaluate VExUS-guided de-resuscitation algorithms versus standard care, stratified by AKI risk.<sup>[14,15]</sup> Automated Doppler tracking and machine-learning integration could further objectify congestion indices. Until then, our data support incorporating VExUS into multimodal haemodynamic rounds, complementing dynamic arterial tests of fluid responsiveness.

## CONCLUSION

In this prospective 50-patient study, a POCUS-derived VExUS score  $\geq 2$  identified systemic venous congestion strongly associated with AKI and longer ICU stay. The score out-performed traditional markers and facilitated timely fluid de-escalation. Routine bedside application of VExUS may enhance precision fluid management and improve renal outcomes in the critically ill. Multicentre randomised trials are warranted to validate its impact on hard endpoints.

## REFERENCES

1. Beaubien-Souligny, W., Rola, P., Haycock, K., Bouchard, J., Lamarche, Y., Spiegel, R., et al. (2020). The Venous Excess Ultrasound (VExUS) score and organ congestion in kidney injury. *American Journal of Respiratory and Critical Care Medicine*, 202(3), 349–359. <https://doi.org/10.1164/rccm.201912-2546OC>
2. Marik, P. E., Monnet, X., & Teboul, J. L. (2011). Hemodynamic parameters to guide fluid therapy. *Annals of Intensive Care*, 1, 1. <https://doi.org/10.1186/2110-5820-1-1> SpringerOpen
3. Longino, D., Mallam, D., & Ma, I. W. Y. (2019). The role of point-of-care ultrasound in assessing volume status in the ICU. *Critical Ultrasound Journal*, 11, 10. <https://doi.org/10.1186/s13089-019-0114-3>
4. Rola, P., Miralles-Aguar, F., Argai, E., Beaubien-Souligny, W., Haycock, K., & Spiegel, R. (2021). Clinical applications of the Venous Excess Ultrasound (VExUS) score: Conceptual review and case series. *The Ultrasound Journal*, 13, 32. <https://doi.org/10.1186/s13089-021-00232-8> SpringerOpen
5. Malbrain, M. L. N. G., Martin, G., & Ostermann, M. (2022). Everything you need to know about dereuscitation. *Intensive Care Medicine*, 48, 1781–1786. <https://doi.org/10.1007/s00134-022-06761-7> SpringerLink
6. Abou-Arab, O., Rodriguez, F., Couvret, C., & Denault, A. Y. (2020). Alterations in portal and intrarenal venous flow are associated with acute kidney injury after cardiac surgery: A prospective observational cohort study. *Journal of the American Heart Association*, 9(6), e009961. <https://doi.org/10.1161/JAHA.118.009961> ahajournals.org
7. Longino, A. A., Martin, K. C., Leyba, K. R., McCormack, L., Siegel, G., & Douglas, I. S. (2024). Reliability and reproducibility of the Venous Excess Ultrasound (VExUS) score: A multi-site prospective study. *Critical Care*, 28, 197. <https://doi.org/10.1186/s13054-024-04961-9> BioMed Central
8. Ibarra-Estrada, M. A., Díaz-González, C. C., Mendu, M. L., Soriano-Pedroza, G., & de la Rosa, G. (2022). Lung ultrasound-guided dereuscitation shortens mechanical ventilation and ICU stay: A randomized controlled trial. *Intensive Care Medicine*, 48(4), 587–598. <https://doi.org/10.1007/s00134-021-06532-0>
9. Husain-Syed, F., Ferrari, F., & Ronco, C. (2021). Venous congestion and kidney dysfunction in heart failure: Emerging role of ultrasound imaging. *Journal of the American College of Cardiology*, 77(23), 2800–2810. <https://doi.org/10.1016/j.jacc.2021.04.064>
10. Pivetta, E., Goffi, A., Lupia, E., Tizzani, M., Porrino, G., Ferreri, E., & Balzaretto, P. (2015). Lung ultrasound-guided fluid management in heart-failure patients. *Chest*, 148(6), 1543–1550. <https://doi.org/10.1378/chest.15-1372>
11. McGee, W. T., & Lyon, C. (2018). Inferior vena cava ultrasound for predicting fluid responsiveness in the ICU. *Journal of Critical Care*, 44, 163–167. <https://doi.org/10.1016/j.jcrc.2017.10.005>
12. Dorfman, P., Bolery-Wavreille, S., Tarabichi, O., & Nedelcut, A. (2019). Doppler-based intrarenal venous flow assessment predicts acute kidney injury in sepsis. *Kidney International Reports*, 4(10), 1416–1424. <https://doi.org/10.1016/j.ekir.2019.06.007>
13. Sun, J., Axelrod, C., Wang, T., & Fleming, B. (2022). Prospective evaluation of Venous Excess Ultrasound for estimation of right-sided filling pressures. *Chest*, 162(5), 1053–1063. <https://doi.org/10.1016/j.chest.2022.05.042> ScienceDirect
14. Vignon, P., Repessé, X., Bégot, E., et al. (2018). Ultrasound evaluation of fluid responsiveness in critically ill patients: A systematic review. *Annals of Intensive Care*, 8, 8. <https://doi.org/10.1186/s13613-018-0365-x>
15. Preau, S., Dewavrin, F., Duthoit, B., et al. (2022). Intrarenal Doppler approaches in hemodynamics: A major step forward to assess renal congestion. *Frontiers in Physiology*, 13, 951307. <https://doi.org/10.3389/fphys.2022.951307> Frontiers.