

ULTRASONOGRAPHIC STUDY IN DIAGNOSIS OF APPENDICITIS IN RAJASTHAN POPULATION

Milind Mukund Sule¹, Sagun Nayak², Divyesh Goswami³

¹Assistant Professor, Department of Radiology, Pacific Medical College and hospital, Bhilon ka Bedla Pratap pura, Girwa Rajasthan, India

²3rd Year Resident, Department of Radiology, Pacific Medical College and hospital, Bhilon ka Bedla Pratap pura, Girwa Rajasthan, India

³Associate Professor, Department of Pathology, Nootan Medical College and Research Center, Visnagar, India

Received : 31/12/2024
Received in revised form : 20/02/2025
Accepted : 07/03/2025

Keywords:
USG, MHz curvilinear transducer, acute appendicitis, USG grading, Rajasthan.

Corresponding Author:
Dr. Sagun Nayak,
Email: ?

DOI: 10.47009/jamp.2025.7.2.51

Source of Support: Nil,
Conflict of Interest: None declared

Int J Acad Med Pharm
2025; 7 (2); 252-255



Abstract

Background: Acute appendicitis is the most common emergency. Hence, imaging methods such as Ultrasound are safer to predict the fatal consequences in case of pain in Right Iliac fossa, in all age groups at the earliest. **Materials and Methods:** 96 (ninety-six) patients with acute appendicitis (AA) of different age groups were studied using the USG machine. The USG of the abdomen was done, based on the American Institute of Ultrasound in Medicine practice guidelines which includes imaging of appendix on Samsung V8 USG machine by 2-5 MHz curvilinear transducer, 4.12 MHz, and a standardized protocol involving graded compression techniques described by Puylaet. Longitudinal and transverse images of the appendix in right lower quadrant were obtained. Compression sonography was performed with documentation of the appearance of the appendix, including the tip. USG findings were retrospectively graded using five-point scales. Grades I and II were classified as negative, and grades 3-5 to 5 were as positive sonographic diagnoses. Surgical and pathological findings were compared. **Result:** In USG grading, 5 patients were highest in 1-10 years, 13 patient's numbers were highest in 5th grade in 11-20 years, 7 patient's numbers were highest in 5th grade in 21-30 years, 5 patients were highest in 2nd grade of USG in 41-50 years of age, 2 were quite common in 2nd, 3rd, and 5th grade in above 50 years of age, sonographically positive 5, negative 35, and surgically 15 positives, 41 negative. In sonographic 48 (50%) proved histopathologically, 64 (66.6%) true positive, 25 (26%) true negative, and 1 (1.04%) false negative. **Conclusion:** USG imaging study is safer, cost-effective, and affordable to lower middle-class patients, above all reliable if correlated to clinical manifestations.

INTRODUCTION

As appendix and pharynx are the most constricted parts of the gastrointestinal tract, hence they are hence more prone to getting infected. Acute appendicitis is the most common indicator for emergency abdominal surgery.^[1] Early appendicitis may present itself atypically and be difficult to distinguish from a myriad of gastrointestinal, genitourinary, and gynecological conditions.^[2] The diagnosis of acute appendicitis (AA) is a constellation of history, physical examination coupled with laboratory investigation, and selective focused imaging.^[3] The role of diagnostic imaging USG in Acute Appendicitis is a good technique, but the accuracy of USG depends on an experienced radiologist. The base of the appendix is connected to the cecum, but its head can be placed in different situations to combat infection.^[4] The diversity of

location is categorized into six positions: retrocecal, pelvic, sub-cecal, pre-ileal, retroileal, and ectopic.^[5] Potential pitfalls in the sonographic diagnosis of Acute Appendicitis include an incomplete investigation of appendicitis resulting in failure to identify segmental or tip of appendicitis and overestimation of increased appendiceal diameter leading to false positive diagnosis; moreover, anatomical variations can also complicate the diagnosis. Hence, an attempt is made to evaluate the Acute Appendicitis by comparing clinical manifestations.

MATERIALS AND METHODS

96 patients of different age groups admitted to Pacific Medical College and Hospital, Bhilon ka Bedla, Pratap Pura, Girwa, Rajasthan—313001 were studied.

Inclusive Criteria

All patients, irrespective of age and sex, clinically suspected of having acute appendicitis were included in the study.

Exclusion Criteria

The patients who needed urgent surgery were excluded as no image was possible due to the urgent need for surgery.

Method:

Out of 96 patients, 11 were between 1 to 10 years of age, 43 were aged between 11-20 years, 15 were aged between 21-30 years, 12 were aged between 31-40 years, 9 were aged between 41-50 years, and 6 were above 50 years of age, after a detailed history and clinical examination. The USG of the abdomen was done, based on the American Institute of Ultrasound in Medicine practice guidelines (5) which includes imaging of appendix on Samsung V8 USG machine by 2.5-5 MHz curvilinear and 6-15 MHz linear transducer and a standardized protocol involving graded compression techniques described by Puylaet (6). Longitudinal and transverse images of the appendix in right lower quadrant were obtained. Compression sonography was performed, with documentation of the appearance of the appendix during compression. A normal appendix compresses. The complete appendix was visualized, including the tip. Doppler imaging was helpful to evaluate for hyperemia; however, a necrotic appendix had decreased or no blood flow. The maximal outer wall diameter and wall thickness were measured along with the course of the appendix. The ultrasonographic (USG) findings were retrospectively graded using a 5 (five) point scale.

Scale-I: Represented normal appendix

Scale-II: indicated that the appendix was not seen, but no inflammation or free fluids were evident.

Scale III: indicated that the appendix was not seen, but secondary signs of appendicitis were present, such as fecolith, pericecal fluid, or increased pericecal echogenicity consistent with infiltration of the mesenteric.

Scale-IV: represents the identification of an appendix of borderline enlarged size (5-6 mm).

Scale-V: indicated acute appendicitis (AA), defined as an enlarged, non-compressible appendix with an outer diameter greater than 6 mm.

Findings graded 1 to 2 were classified as negative, and 3 to 5 were graded as positive for AA. The original reports were reviewed and graded using the same criteria. USG findings were compared with subsequent and pathological findings to determine the sensitivity and specificity of the sonographic examination.

The duration of the study was June 2024 to February 2025.

Statistical analysis: Various findings of USG, grading comparison with surgery, or pathological findings were classified. The statistical analysis was carried out in SPSS software, and the ratio of males and females was 2:1.

RESULTS

[Table-1] Ultrasonographic grading of Acute appendicitis with reference to age –

- 1 – 10 years of age had 3, 2nd grade-3, 3rd grade 5 were 5th grade, total 11 patients.
- 11-20 years of age: 11, 2nd grade 8, 3rd grade 11, 4th grade 13, 5th grade, total 43 patients
- 21-30 years of age: 5, 2nd grade, 3, 4th grade 7, 5th grade, total 15 patients
- 31-40 years of age: 5, 2nd grade 2, 3rd grade 3, 4th grade 2, 5th grade and total 12 patients.
- 41-50 years: 5, 2nd grade 4, 5th grade, total 9 patients
- 50 > years of age: 2, 2nd grade 2, 3rd grade 2, 5th grade, total 6 patients

[Table 2] Comparison of sonographic diagnosis with surgical pathological findings in who had undergone surgical

- In sonographically 5 negative, 15 positives in surgery, total 20
- In sonography 35 negative, 41 positives in surgically and total 76
- Sonographic negative 46, surgical positive 56, total 96.

[Table 3] Results of sonographic studies on acute appendicitis – 48 (50%) proved histo-pathologically positive, 66 (66.6%) true positive, 25 (26%) true negative, 6 (6.2%) false positive, 1 (1.4%) were false negative.

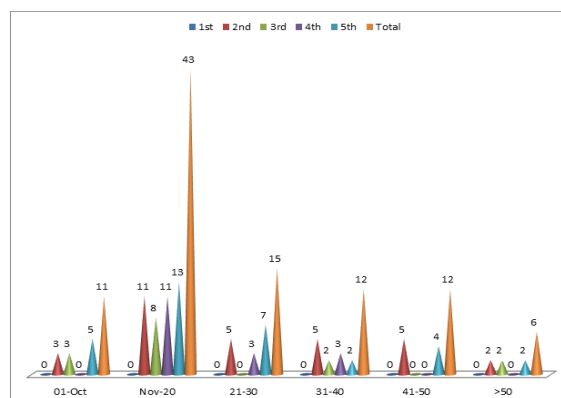


Figure 1: Ultra sonographic grading of Acute appendicitis with reference to age

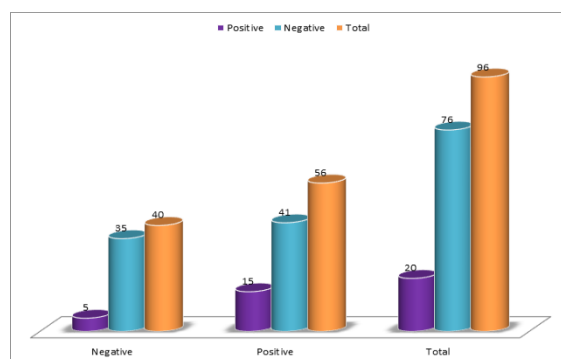


Figure 2: Comparison of sonographic diagnosis with surgical pathological findings in who had underwent surgery

Table 1: Ultra sonographic grading of Acute appendicitis with reference to age.

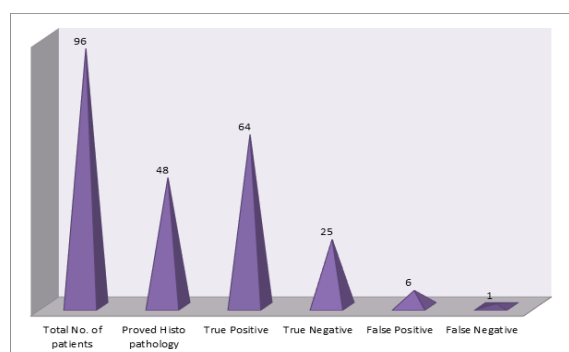
US grade	1-10	11-20	21-30	31-40	41-50	>50
1st	0	0	0	0	0	0
2nd	3	11	5	5	5	2
3rd	3	8	0	2	0	2
4th	0	11	3	3	0	0
5th	5	13	7	2	4	2
Total	11	43	15	12	12	6

Table 2: Comparison of sonographic diagnosis with surgical pathological findings in who had underwent surgery.

Sonography	Surgery		Total
	Negative	Positive	
Positive	5	15	20
Negative	35	41	76
Total	40	56	96

Table 3: Results of sonographic studies on acute appendicitis

Total No. of patients	Proved Histo pathology	True Positive	True Negative	False Positive	False Negative
96	48 (50%)	64 (66.6%)	25 (26%)	6 (6.2%)	1 (1.04)

**Figure 3: Results of sonographic studies on acute appendicitis**

DISCUSSION

Ultrasonographic study in diagnosis of Acute Appendicitis in Rajasthan Population at different age groups: 11 in 1-10 years, 43 patients between 11-20 years of age, 15 in 21-30 years of age, 12 patients in 31-40 years, and 9 patients above 50 years of age [Table 1]. Sonographically, 5 positive, 35 negative, surgically 15 positives, and 41 negative [Table 2]. The sonographic results were of 48 (50%) proved histo-pathologically 64 (66.6%) true positive, 25 (26%) true negative 1 (1.04%) false (Table 3). These findings are more or less in agreement with previous studies.^[7-9] Appendix being a lymphoid organ, is prominent in children because other lymphatic organs are not well developed in childhood. The length of the appendix is longer in children than in adults. The appendix is popularly called the soldier of the abdomen because it moves towards the infections by changing its various positions and gets infected and inflamed, probably due to luminal obstruction, which may result from fecaliths, lymphoid hyperplasia, foreign bodies, parasites, and primary neoplasms or metastasis.^[10] Acute Appendicitis is commonly observed in children due to the greater length of the appendix and the back of the development of the omentum in young children. It has been suggested that the peak of development of lymphoid tissue, which occurs during adolescence,

leads to an increased liability of the appendix to obstruct and so accounts for the high incidence of the disease.^[11] A failure to recognize other presentations of Acute Appendicitis will lead to delayed diagnosis and increased patient morbidity. Patients with retrocecal Acute Appendicitis or those presenting in the later months of pregnancy may have pain limited to the right flank or Costo-vertebral angle. Male patients with a retrocecal appendix may complain of a right testicular path. Pelvic or retroileal locations of an inflamed appendix will have been referred to in the pelvis, rectum, adnexa, or rarely in the left lower quadrant; may sub-cecal and pelvic supra-pubic pain and urinary frequency predominate.^[12] Physical examination reveals a generally soft abdomen with localized tenderness at or about MC Burney's point. Pathological Acute Appendicitis is divided into 3 types: (1) catarrhal appendicitis; (2) phlegmonous appendicitis; and (3) gangrenous appendicitis. The laboratory markers for the diagnosis of Acute Appendicitis include elevation of WBC, C-reactive protein, the proportion of polymorphonuclear cells, and abnormal urine analysis in 19% to 40% of patients with Acute Appendicitis. Abnormalities include pyuria, bacteriuria, and hematuria.^[13]

CONCLUSION

Acute Appendicitis is the most common acute abdominal condition, requiring emergency surgery. As Acute Appendicitis is predominantly in children and young adults, USG is quite a safer technique to confirm the diagnosis because imaging radiation from CT or MRI will have an adverse impact on the viscera of growing children. USG and co-morbid clinical symptoms of Acute Appendicitis will be an ideal approach to treating Acute Appendicitis surgically or conservatively.

REFERENCES

1. Puyaert J: Acute appendicitis: US evaluation using graded compression. *Radiology* 1986, 158, 355-360.

2. Addiss DG, Shafer N: The epidemiology of appendicitis and appendectomy in United States Am. J. Epidemiology 1990, 132; 910–25.
3. Pacharn P, Ying J: Sonographic findings in the evaluation of acute appendicitis: are negative sonographic findings good enough? J. Ultrasound Med. 2010, 29; 1749–1755.
4. Gwynn LK: The diagnosis of acute appendicitis: clinical versus computed tomography evaluation J. Emergency Med. 2010, 29; 1749–1755.
5. Murphy J: Two thousand operations for appendicitis with deductions from personal experience. Am. J. Med. Sc. 1904, 129; 187–211.
6. Hudson HW and Chamberlin SW: Acute appendicitis in childhood: a statistical study of 848 cases from children's hospitals. Baston J. Paed, 1939, 15; 408–411.
7. Leann E, Martha Mundon: Sonography as the first line of evaluation in children with suspected acute appendicitis. J. Ultrasound Med. 2012, 31; 1153–1157.
8. Andy pertoianu: Diagnosis of Acute Appendicitis, Int. J. of Surgery, 212, 115–119.
9. Des plantes CMP, Van Veen MJF der Palen JV: The effect of unenhanced MRI on the surgeon's decision-making process in females with suspected appendicitis. J. Surg. 2106, 40; 2881–2887.
10. Lee JH, Jeong YK: Operator-dependent techniques for graded compression sonography to detect the appendix and diagnose acute appendicitis AJR Am. J., Roentgenol 2005, 184; 91–97.
11. Ghabani A, Forouzes A: Variation in Anatomical Position of Vermiform Appendix among Iranian Population, Hindawi Publishing Corporation 2014, 255 (1), 3–7.
12. Most Beck G, Adam EJ: How to Diagnose Acute Appendicitis: Ultrasound First Insights Imaging Journal 2016, 7 (2), 255-265.
13. American Institute of Ultrasound Medicine (AIUM) practice guideline for the performance of an ultrasonic examination of the abdomen J. Ultrasound Med. 2008, 27; 319–326.