

STUDY OF FUNCTIONAL OUTCOME OF MIDDLE ONE THIRD FRACTURE OF CLAVICLE IN ADULT'S CONSERVATIVE VERSES SURGICAL METHODS

Rohit Ranjolkar¹, Anand Jabshetty²

¹Assistant Professor, Department of Orthopaedics, BRIMS Bidar, Karnataka, India.

²Professor and Head, Department of Orthopaedics, BRIMS Bidar, Karnataka, India.

Received : 09/02/2025
Received in revised form : 03/04/2025
Accepted : 18/04/2025

Keywords:

Conservative, Kirschner wires, titanium elastic nail, pre-countered, clavicle plate.

Corresponding Author:

Dr. Rohit Ranjolkar,
Email: rohitranjolkar@gmail.com

DOI: 10.47009/jamp.2025.7.2.203

Source of Support: Nil,
Conflict of Interest: None declared

Int J Acad Med Pharm
2025; 7 (2); 1015-1018



Abstract

Background: The clavicle is a curved bone without a medullary cavity and is more prone to getting fractured during shoulder girdle injury. Its reunion, maintenance of the same length, is a great challenge to orthopedic surgeon hence, conservative and surgical approaches have been used. **Materials and Methods:** Out of 60 patients with mid-clavicular fractures, 30 were treated with conservative treatment and 30 with surgical techniques like Kirschner wire, the titanium elastic nail method, and the pre-contoured clavicle plate method. Follow-up was done for six months, and results were confirmed by X-ray and movements of the shoulder joint. **Result:** In the conservative method, treatment had an increased incidence of shortening, malunion. Operative methods were an effective alternative to conservative treatment of fracture of the mid-shaft clavicle. **Conclusion:** The conservative treatment had an increased incidence of shortening and malunion of the clavicle; hence, the surgical method is more preferable than the conservative because of early union and length remaining the same.

INTRODUCTION

As the clavicle ossifies in the membrane, it does not have a medullary cavity. Due to its curved structure, the middle 1/3rd is more prone to get fractured in adults during traumatic injury around the shoulder girdle due to their subcutaneous position. Fracture of clavicle: 2.5-5% of all fractures.^[1] Among the upper extremity, fractures of the clavicle comprise 15% of all adult upper extremity fractures. Fractures of the clavicle have been traditionally treated conservatively. Moreover, open reduction and internal fixation (ORIF) of mid-clavicular fractures was considered the ideal way to develop a non-union.^[2] Although many methods of closed reduction have been described, it is recognized that reduction is practically impossible to maintain, and a certain amount of deformity and disability is observed in adult patients.

Non-surgical (conservative) treatment was considered adequate to decrease pain and allow the fracture to unite.^[3] It is also reported that conservative treatment takes a longer time for the union of a fractured clavicle, which impairs the mobility of the upper limb and keeps the patient idle till the union of the fractured bone.^[4] Hence, an attempt is made to compare the fracture of the middle 1/3rd of the clavicle treated conservatively and surgically. Its pros and cons are evaluated in the

interest of an early and efficient approach to such patients.

MATERIALS AND METHODS

60 (sixty) adult patients who visited the Orthopaedic Department of BRIMS Bidar, Karnataka-585101 were studied.

Inclusion Criteria

The patients are above 18 years old, have a closed type of displaced fracture, and are medically fit to undergo surgery. The patients who gave their consent in writing for the study were selected.

Exclusion Criteria

Patients having pathological fracture, medically unfit, or a history of non-union from previous fracture. Fractures at the ends of the clavicle, open fractures, were excluded from the study.

Method: Patients were admitted to the casualty or orthopedic ward. Every patient was assessed for vascular and neurological status. Out of 60 patients, 30 were treated conservatively and 30 surgically.

(A) Conservative (non-operative method):

- Traditionally, middle-third clavicle fractures have been treated conservatively, even when substantially displaced. There are many methods to immobilize the regions that have been described.
 1. Figure-of-Eight bandage or clavicular brace
 2. Shoulder immobilizer

3. Arm Pouch

(B) Operative Methods: Kirschner wires: Drilling is considered a simple way of implanting, with many advantages, such as percutaneous and traumatic insertion. However, this technique also has its disadvantages, like temperature elevation, resulting in osteonecrosis and heat-related complications.^[5]

- Titanium elastic Nail: The use of an intramedullary device carries advantages of smaller incision, less soft tissue dissection, and load-sharing fixation with relative stability that encourages copious callus formation.^[6] The titanium ESIN has been successfully used in the fixation of pediatric long bone fractures. One advantage of titanium ESIN is that it can block itself in the bone and provide a three-point fixation within the s-shaped clavicle.
- Pre-contoured clavicle plate: The plates are designed to fit the anatomic shape of the natural clavicle, eliminating the need for plate counteracting at the time of surgery, which decreases operative time and potentially lessens the risk of plate fatigue fracture.

(Note: The patients are immobilized for 4-6 weeks.) The duration of the study was March 2024 to February 2025.

Statistical Analysis: Constant shoulder score at six months follow-up post-procedure complications in both groups were studied and classified with percentages. The statistical analysis was carried out using SPSS software. The ratio of male and female was 1:2.

RESULTS

[Graphic Table] Various movements of the shoulder joint at six months were compared in the conservative group and the operative group.

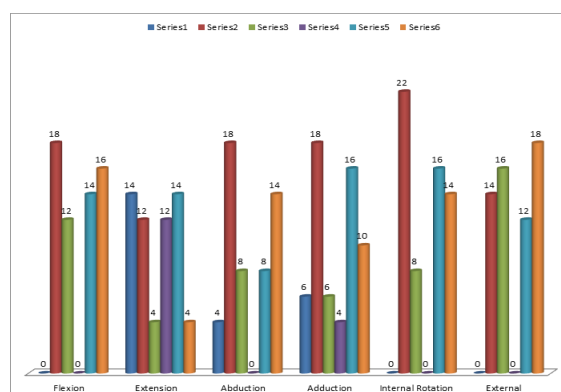
[Table 1] Constant shoulder score at 6-month follow-up:

- In conservative group 18 (60%) had 90-100 shoulder care and in operative group 28 (93.3%) patients.
- 2 (6.6%) of the conservative group and 2 (6.6%) of the operative group had scores of 80-89.
- 10 (33.3%) in the conservative group and zero (00) in the surgical group had a 70-79 shoulder score.

[Table 2] Post-procedure complications:

- 10 (33.3%) shortening of clavicle in conservative group
- 3 (20%) superficial infections in the surgical group, 14 (46.6%) shoulder stiffness in the

conservative, 18 (6%) in surgical stiffness, 2 (6.66%) non-union in the conservative method.



Graphic Figure: Movement at shoulder joint

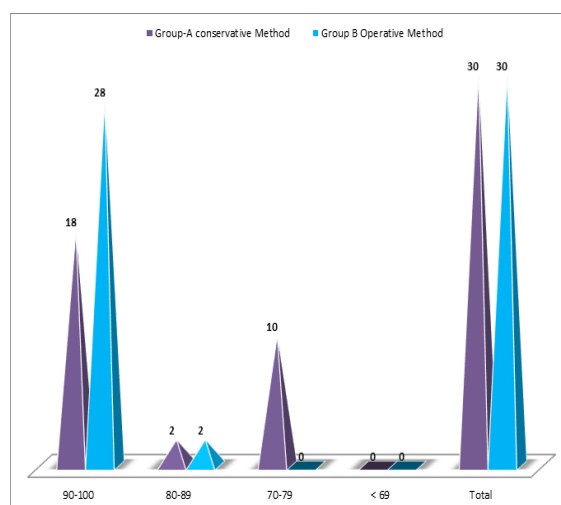


Figure 1: Constant shoulder score at 6 month study (follow up)

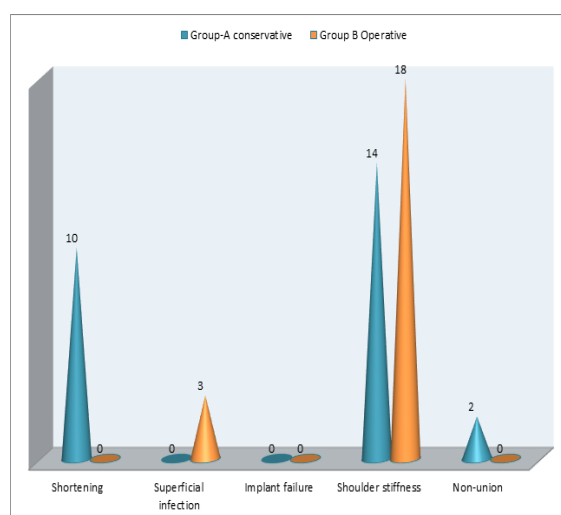


Figure 2: Post-procedure complications

Graphic Table: Movement at shoulder joint

Particular	Group A			Group B		
	0	18	12	0	14	16
Flexion	0	18	12	0	14	16
Extension	14	12	4	12	14	4
Abduction	4	18	8	0	8	14
Adduction	6	18	6	4	16	10
Internal Rotation	0	22	8	0	16	14

External	0	14	16	0	12	18
----------	---	----	----	---	----	----

Table 1: Constant shoulder score at 6 month study (follow up)

Constant shoulder score	Group-A conservative Method		Group B Operative Method	
	No of patients	Percentage (%)	No of patients	Percentage (%)
90-100	18	60%	28	93.3%
80-89	2	6.6%	2	6.6%
70-79	10	33.3%	0	0
< 69	0	0	0	0
Total	30	100%	30	100%

Table 2: Post-procedure complications

Complications	Group-A conservative		Group B Operative	
	No of patients	Percentage (%)	No of patients	Percentage (%)
Shortening	10	33.3%	0	0%
Superficial infection	0	0	3	20%
Implant failure	N/A	--	0	0%
Shoulder stiffness	14	46.6%	18	60%
Non-union	2	6.66%	0	0%

DISCUSSION

Present study of functional outcome of middle 1/3rd fracture of clavicle in adults: conservation versus surgical methods. Movements of shoulder joints were compared in both groups after six months of treatment. Group A (conservative method group) had significant results (graphic table). The constant shoulder score study at the 6th-month follow-up. Group B (surgical) had a significant score of 90-100 [Table 1]. The post-procedure complications were shortening of the clavicle in 10 (33.3%) in the conservative group and shoulder stiffness in 14 (46.6%) in the conservative group and 18 (60%) in the surgical group. Non-union was 2 (6.6%) in the conservative method only, but superficial infection was 3 (20%) in the surgical group (Table 2). These findings are more or less in agreement with previous studies.^[7-9]

The patients in the operative group improved functionally and returned to normal activities earlier than the conservative group. This factor is very important, as patients today are more active and expect to return to pain-free function following a fracture. The patient satisfaction in the operative group is more than in the conservative group regarding the appearance of the shoulder (cosmetic) and normal, pain-free movements of the shoulder because shortening 10 (33.3%) and non-union 2 (6.66%) were observed in the conservative group. It leads to dissatisfaction of patients treated with conservative methods.^[10]

Iatrogenic neurovascular injury is an imminent complication if proper operative techniques are not followed properly. Because major neurovascular structures like the subclavian vein, subclavian artery, and brachial plexus are near to the surgical area.^[11] However, only superficial infections were observed in 3 (20%) of surgical patients.

Conservative treatment was superior to surgical intervention in hardware irritation and/or prominence, infection and/or dehiscence, and hardware requiring removal. However, these results

are based on evidence from the RCT (randomized controlled trials).^[12] Hence, evidence is insufficient to indicate whether surgical or conservative treatment is best for treating a fracture of the middle 1/3rd of the clavicle that is displaced. Treatment must be individualized with careful consideration of the relative advantages of each intervention and of patient preferences. The patient's age, activity level, and fitness status have to be considered before treatment if conservative or surgical treatments are ideal.

CONCLUSION

Present study of conclusion outcome of middle one-third fracture of clavicle in adults: conservative versus surgical method. Conservative methods are associated with an increased incidence of shortening and malunion as compared to surgical intervention, but surgical methods have superficial infection and more stiffness of the shoulder. Hence, treatment should be individualized, with careful consideration of the advantages and disadvantages of each treatment method and patient preferences.

Limitation of study: Owing to remote location of research centre, lack of latest techniques and small number of patients, we have limited finding and results.

REFERENCES

1. Alikhan M.A, Lucas H.K.: Planting of fracture of the clavicle. Clin. Ortho. Relat. Res. 1994, 300; 127-32.
2. Aliman FL, Jr.: Fractures and ligament injuries of the clavicle and its articulation J. Bone Joint Surg. Am. 1967, 49; 774-84.
3. Nordqvist A, Peterson C: The incidence of fractures of the clavicle clin. Orthop. Relat. Res. 1994, 300; 127-32.
4. Bajuri MY, Maidin S: Functional outcome of conservatively treated clavicle fractures clinics (Sao Paulo) 2011, 66; 635-9.
5. Bas BGM: Franssen, one century of Kirschner wires and Kirschner wire insertion techniques; historical review. Acta Orthop. 2010, 76; 1-6.
6. Sugawara MJ: Treatment of displaced mid-shaft clavicle fractures: figure-of-eight harness versus anterior plate osteosynthesis JBJS, 2017, 99; 1159-65.

7. Robinson M, Court Brown CM: Estimating the risk of non-union following non-operative treatment of a clavicular fracture, *J. Bone Joint Surg. Am.* 2004, 86 A; 1359-65.
8. Constant CR, Murely AH: Clinical method of functional assessment of the shoulder. *Clin. Orth. Rel. Res.* 1987, 214; 160-4.
9. Ledger M, Leek N: Short malunion of the clavicle: An anatomic and functional study *J. Shoulder Elbow Surg.* 2005, 14; 349-54.
10. Eiff MP: Management of clavicle fractures. *Am. Fam. Physician Journal* 1907, 55; 121-8.
11. Pearson AM, Tosteson AN: Is surgery for displaced mid-shaft clavicle fractures in adults cost-effective? *J. Orthop. Trauma* 2010, 24; 426-33.
12. Thyagarajan DS, Day M: Treatment of mid-shaft clavicle fractures: A comparative study *Int. J. Shoulder Surg.* 2009, 3; 23-7.