

## A STUDY OF CLINICAL, IMAGING, AND PATHOLOGICAL CORRELATION OF NECK MASSES

Ramesh Kumar E<sup>1</sup>, Chithra C P<sup>1</sup>, Ramakrishnan V R<sup>1</sup>

<sup>1</sup>Department of Otorhinolaryngology, Jubilee Mission Medical College & Research Institute, Thrissur, Kerala, India

Received : 25/10/2024  
Received in revised form : 14/12/2024  
Accepted : 30/12/2024

**Keywords:**  
Neck mass, USG, FNAC,  
histopathology and clinical  
examination.

Corresponding Author:  
**Dr. Ramesh Kumar E,**  
Email: drerk@rediffmail.com

DOI: 10.47009/jamp.2025.7.1.26

Source of Support: Nil,  
Conflict of Interest: None declared

*Int J Acad Med Pharm*  
2025; 7 (1); 129-133



### Abstract

**Background:** Most of the neck masses in children are infectious and in adult are neoplastic. There is a need for appropriate evaluation of neck mass. Currently, histopathological evaluation is gold standard and can be done in limited conditions where excision of mass is done. **Materials and Methods:** It is a prospective study conducted among 86 patients who came with clinically palpable neck mass. Clinical evaluation, USG, FNAC, and histopathological evaluation was done in all cases. Diagnostic accuracy of the tests was measured using sensitivity, specificity, positive predictive value, negative predictive value, and overall diagnostic accuracy, using histo-pathological examination as gold standard. **Result:** The sensitivity, specificity, PPV and NPV of clinical examination for diagnosing severity of disease was 52.4%, 98.5%, 91.7% and 86.5%, respectively; with overall diagnostic accuracy of 87.2%. The sensitivity, specificity, PPV and NPV for ultrasound for diagnosing severity of disease was 80.9%, 76.9%, 53.1% and 92.5%, respectively; with overall diagnostic accuracy of 77.9%. Similarly, they were 90%, 100%, 100% and 97.4%, respectively; with overall diagnostic accuracy of 97.9% for FNAC. **Conclusion:** FNAC has high diagnostic accuracy compared to clinical examination and USG. However, there is a need to reduce the limitations like sampling error and unsatisfactory specimens.

## INTRODUCTION

Neck masses are abnormal lesions deep to the skin (congenital or acquired) between the mandible and the clavicle<sup>1</sup>. While infectious aetiology is the most common underlying cause among children, neoplasms are one of the commonest aetiologies for persistent neck swellings among adults.<sup>[1]</sup> Presence of asymptomatic palpable mass may be the only presenting complaints in few cases.<sup>[1-5]</sup> Timely diagnosis of the cases can improve prognosis in such cases. However, precautions need to be taken to prevent over-diagnosis of cases.<sup>[6-8]</sup> Hence neck mass needs to be timely evaluated with appropriate focused investigative inquiries.

Various methods are available for the evaluation of neck swelling. Clinical examination plays an important role in diagnosis of neck swelling based on the location and consistency of the swelling.<sup>[9,10]</sup> They are low-cost tests which provide early suspicion of the disease. In addition, they help in assessing mobility and pressure symptoms among the cases.<sup>[11]</sup> However, diagnosis based solely on clinical judgement can be challenging especially in cases of small and deep-seated lesions. Fine needle aspiration cytology (FNAC) is a rapid, simple, and minimally invasive technique that can be used to evaluate neck

masses.<sup>[12]</sup> However, higher rate of inadequate sample can reduce the efficacy of the test.<sup>[13]</sup> But techniques like ultrasound guided FNAC technique and use of Bethesda system of reporting primary thyroid lesions have increased the efficacy of the test and improved communication between the pathologist and the treating doctor on the diagnosis and severity of the disease.<sup>[14-16]</sup> Ultrasound can be used alone for evaluation of neck mass. They avoid radiation compared to CT evaluation and is non-invasive compared to FNAC.<sup>[17]</sup> However, they are currently recommended as an adjuvant evaluation technique for neck mass.<sup>[1]</sup>

Histopathological evaluation by open biopsy remains the gold standard for diagnosis of thyroid mass<sup>1</sup>. They are invasive procedure where a whole mass or part of the lesion is sent for pathological evaluation. They have advantage of macroscopic visualization of the lesion and their appropriate biopsy.

Hence there are many evaluations technique available for neck mass, each with their advantages and disadvantages. Due to the varied anatomical structures in the neck, each diagnostic tests have their own importance. With changing trends in various diseases across the globe and advancement in technology, there is a need for constant assessment of the available techniques to provide evidence-based

knowledge with the goal of effective patient management with neck mass.

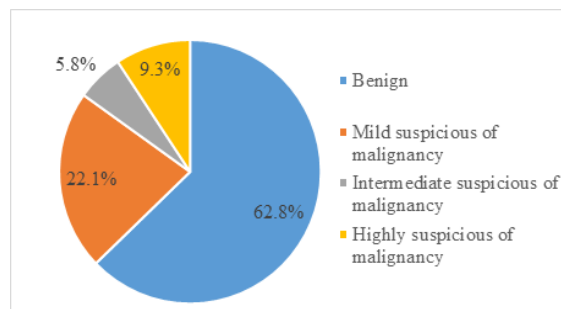
## MATERIALS AND METHODS

The study conducted over a period of one year from 01 August 2021 to 01 August 2022, patients presented with clinically palpable neck swelling and planned for surgical management, satisfying the inclusion and exclusion criteria were approached for the study. 86 patients were included in this study. The inclusion criteria include patients of both sex >10 years of age who presented with clinically palpable neck swelling. The exclusion criteria include patients with clinically undetectable neck swelling, suspected abscess, vascular tumors, and history of any neck surgery, inoperable conditions & patients not willing for surgery. The purpose and method of study was informed to them using a patient information sheet and informed consent was taken from consenting subjects. Using a preformed semi-structured questionnaire, the patient's details about socio-demographic parameters and history of neck swelling was taken, including the presenting clinical symptoms. This was followed by clinical examination of the patient with focus on site, size, mobility, consistency, and tenderness of the swelling. Based on the clinical examination, patients were categorized as benign or malignant. This was followed by Ultrasound examination of the neck. CT or MRI was done if USG was inconclusive. Fine needle aspiration cytology (FNAC) report was documented before the surgery and histopathological report was documented after the surgery. Data was entered in MS Excel and analysed using IBM-SPSS 20 software.

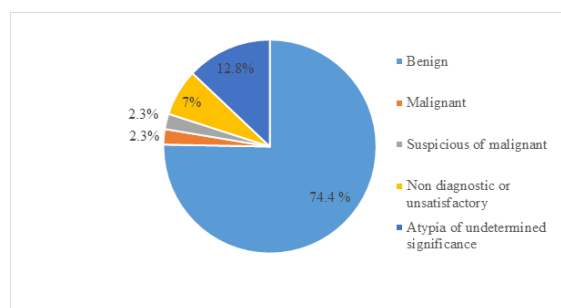
## RESULTS

On analysis the most common clinical diagnosis was multinodular goitre (48.8%). The multinodular goitre were further classified as benign or malignant based on clinical examination and associated symptoms. Solitary thyroid nodule was noted in 27.9% cases which were further classified as suspected benign or malignant based on clinical examination and symptom evaluation. Parotid swelling was clinically diagnosed in 17.4% cases. Other clinical diagnosis was cervical lymphadenopathy (2.3%), lymphoma (1.2%), and submandibular salivary gland swelling (1.2%). Based on clinical examination, it was suspected that 86% of the lesions were benign and the rest 14% were malignant. Based on USG examination, 62.8% of the cases were categorized as benign and the rest 37.2% malignant. Thyroid cases were further classified as mild suspicious (22.1%), intermediate suspicious (5.8%) and highly suspicious of malignancy (9.3%) based on TIRADS.

On FNAC, Thyroid swellings were further classified into non-diagnostic or unsatisfactory (7%), benign (74.4%), atypia of undetermined significance (12.8%), follicular neoplasm (1.2%), suspicious of malignancy (2.3%) and malignancy (2.3%) based on BETHESDA classification.

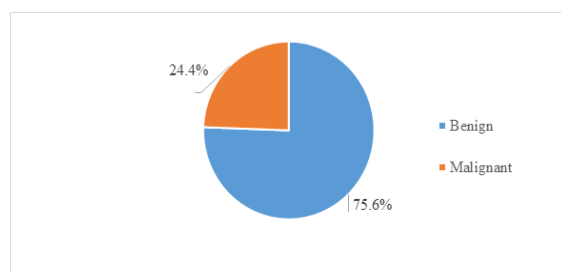


**Figure 1: Severity of lesion based on ultrasound findings**



**Figure 2: Severity of lesion based on FNAC findings**

On histopathological examination, the most common diagnosis noted were nodular colloid goitre without degeneration (25.5%), nodular colloid goitre with degeneration 16.2%), pleomorphic adenoma (15.1%) and papillary carcinoma (9.3%) of thyroid. Based on Histopathological examination, 75.6% cases were diagnosed as benign lesion and the rest 24.4% were classified as malignant lesions.



**Figure 3: Severity of lesion based on Histopathological examination**

The sensitivity, specificity, PPV (positive predictive value) and NPV (Negative predictive value) of clinical examination for diagnosing severity of disease (in comparison of gold standard evaluation using Histopathology examination) was 52.4%, 98.5%, 91.7% and 86.5%, respectively; with overall diagnostic accuracy of 87.2%.

The sensitivity, specificity, PPV and NPV for ultrasound for diagnosing severity of disease (in comparison of gold standard evaluation using

Histopathology examination) was 80.9%, 76.9%, 53.1% and 92.5%, respectively; with overall diagnostic accuracy of 77.9%.

The study noted all FNAC diagnosed cases of malignancy, and suspicion of malignancy were diagnosed as malignancy in histopathological examination. Among the 58 cases diagnosed as benign in FNAC, 56 (96.5%) were diagnosed as benign in histopathological examination. 2 of the 6 non-diagnostic or unsatisfactory case of FNAC was diagnosed as malignancy in HPE. The single case of follicular neoplasm diagnosed in FNAC was diagnosed as malignant in HPE. Of the 11 atypia of undetermined significance cases of FNAC, 6 (54.5%) cases were diagnosed as malignant in histopathological examination. The study included 13 cases of pleomorphic adenoma (benign) and one

case of secretory carcinoma (malignant). While all the cases of pleomorphic adenoma and Warthin's tumour were diagnosed as benign lesion in FNAC, the only case of secretory carcinoma was misdiagnosed as benign in FNAC.

The sensitivity, specificity, PPV and NPV for FNAC for diagnosing severity of disease (in comparison of gold standard evaluation using Histopathology examination) was 83.3%, 100%, 100% and 96.5%, respectively; with overall diagnostic accuracy of 97.0%. The sensitivity, specificity, PPV and NPV for FNAC for diagnosing malignancy of thyroid gland tumour was 90%, 100%, 100% and 97.4%, respectively; with overall diagnostic accuracy of 97.9%. The only false negative case detected was papillary microcarcinoma which was misdiagnosed as benign lesion.

**Table 1: Diagnostic accuracy of FNAC in classifying severity of thyroid gland lesions in comparison with HPE as gold standard**

FNAC (Thyroid gland)	Histopathological examination		Total
	Malignant	Benign	
Malignant	9 (TP)	0 (FP)	9
Benign	1 (FN)	38 (TN)	39
Total	10	38	48

**Table 2: Diagnostic accuracy of Ultrasound in classifying severity of disease in comparison with HPE as gold standard**

USG	Histopathological examination		Total
	Malignant	Benign	
Malignant	17 (TP)	15 (FP)	32
Benign	4 (FN)	50 (TN)	54
Total	21	65	86

**Table 3: Diagnostic accuracy of FNAC in classifying severity of disease in comparison with HPE as gold standard**

FNAC	Histopathological examination		Total
	Malignant	Benign	
Malignant	10 (TP)	0 (FP)	10
Benign	2 (FN)	56 (TN)	58
Total	12	56	68

## DISCUSSION

Neck mass in adult should evoke suspicion of neoplasms, including metastatic head and neck squamous cell carcinoma. Hence early diagnosis of neck masses is important to prevent advance in stage of disease and to improve prognosis.<sup>[1]</sup>

Clinical examination may be the only assessment technique available in peripheral setting and plays an important role in early screening of cases. Our study compared clinical evaluation technique with histopathological examination as gold standard and noted that clinical examination was 52.3% sensitive and 98.4% specific in differentiating benign from malignant lesion. The PPV and NPV of clinical examination was 91.7% and 86.5% respectively, with diagnostic accuracy of 87.2%. Our study noted a lower sensitivity compared to studies conducted by Chandak et al and Aquib et al. However, it should be noted that while our study correlated with HPE as gold standard, Chandak et al and Aquib et al compared with FNAC as gold standard and Mehta N et al studied only neck nodes. Moreover, there is no

clarity on clinical examination technique used in these studies.

Current clinical practice recommends clinicians to be suspicious of malignant neck mass if more than 1.5 cm in size, firm in consistency, fixed to adjacent structures, and/or with overlying skin ulceration. Associated symptoms and high-risk history like higher age and tobacco consumption should increase the suspicion of carcinoma. Our study included history and clinical examination in assessing neck mass. However, the sensitivity of clinical examination was low in diagnosis malignant neck mass, suggesting a high false negative cases. Hence, additional laboratory assessment should be recommended as part of evaluation of neck mass.

Compared to clinical examination, our study noted a higher sensitivity for USG in detecting malignant neck mass (80.9%). However, the study noted low positive predictive value (53.1%) suggesting a high false positive rate and chances of unnecessary higher surgical intervention if not further investigated. In addition, USG had lower specificity (76.9%) compared to clinical examination. In comparison,

Chandak et al noted higher diagnostic accuracy in detecting malignant neck mass. However, their study correlated with FNAC as gold standard. Similarly, Sardar Q et al and Jinu CL et al compared with FNAC as gold standard, and found lower sensitivity but higher specificity compared to our study. Sardar Q et al found lower PPV similar to our study. Our study has the advantage of correlating USG with HPE examination which is considered as gold standard for evaluation of majority of neck mass.

Ultrasound technique has the advantage of portability, non-radiation, and non-invasive nature of the procedure.<sup>[17]</sup> Hence, they are initial investigation modality practiced in majority of neck mass. However, high false positive results dictate further evaluation in suspected cases.

Ultrasound guided - FNAC was done in our study and we noted that 6.9% of cases were of non-diagnostic or unsatisfactory. Few of the important factors associated with non-diagnosis include inadequate aspirates, hypo-echogenicity, cystic dominance, macro-calcification, and smaller size (5-10 mm). Our study noted that 2 of 6 non-diagnostic FNAC samples were diagnosed as malignant in histo-pathological examination. This is of concern. Repeat FNAC may be needed in suspicious cases. The second issue with FNAC is the cases of atypia of undetermined significance. Our study noted that 12.7% of cases were of atypia of undetermined significance (AUS) and more than half of the cases turned malignant in HPE.

Our study assessed the diagnostic accuracy of FNAC after excluding the AUS and the follicular neoplasm. The study noted high sensitivity (83.3%), specificity (100%), PPV (100%), NPV (96.5%) and diagnostic accuracy (100%) for FNAC in detecting malignant lesion. In our study, the two cases with false negative cases were that of papillary microcarcinoma and secretory carcinoma. However, it is noted that there is no uniformity of classification of cases into benign and malignant based on FNAC results in different studies. There is a need of guidelines with regards to assessment of FNAC in evaluation of neck mass.

All the cases of Warthin's tumour and pleomorphic adenoma were appropriately diagnosed as benign in FNAC assessment. Overall, the study showed higher diagnostic accuracy for FNAC, compared to clinical examination and USG in evaluation of neck mass. However, the result should be read with caution as there are issues related to non-diagnostic / unsatisfactory diagnosis in FNAC.

## CONCLUSION

Based on our study, we concluded that while clinical examination, USG, and USG guided FNAC are important modes of investigations for neck masses, FNAC has high diagnostic accuracy compared to other two tests. However, there is a need to reduce sampling error, unsatisfactory specimen. Moreover, there is a need to counsel the patients on changes of

false positive results during pre-operative counselling.

## Acknowledgement

We would like to express our sincere gratitude to Dr. M V George, HOD, Department of Otorhinolaryngology, who provided invaluable support and guidance during the study. We are grateful to the Management, Principal and Medical Superintendent of Jubilee Mission Medical College and Research Institute, Thrissur for permitting us to utilize the resources necessary for completing this work.

## REFERENCES

1. Pynnonen MA, Gillespie MB, Roman B, Rosenfeld RM, Tunkel DE, Bontempo L et al. Clinical Practice Guideline: Evaluation of the Neck Mass in Adults. *Otolaryngol Head Neck Surg.* 2017 Sep;157(2\_suppl):S1-S30. doi: 10.1177/0194599817722550.
2. Mattiuzzi C, Lippi G. Current Cancer Epidemiology. *J Epidemiol Glob Health.* 2019 Dec;9(4):217-222. doi: 10.2991/jegh.k.191008.001.
3. Spinelli C, Ghionzoli M, Oreglio C, Sanna B, De Napoli L, Morganti R et al. Increased trend of thyroid cancer in childhood over the last 30 years in EU countries: a call for the pediatric surgeon. *Eur J Pediatr.* 2022 Nov;181(11):3907-3913. doi: 10.1007/s00431-022-04596-4.
4. Mathew IE, Mathew A. Rising Thyroid Cancer Incidence in Southern India: An Epidemic of Overdiagnosis? *J Endocr Soc.* 2017 Apr 4;1(5):480-487. doi: 10.1210/je.2017-00097.
5. Bhasker N. Review of Head and Neck Masses in the Indian Population Based on Prevalence and Etiology With an Emphasis on Primary Diagnostic Modalities. *Cureus.* 2021 Jul 7;13(7):e16249. doi: 10.7759/cureus.16249.
6. Jegerlehner S, Bulliard JL, Aujesky D, Rodondi N, Germann S, Konzelmann I, Chiolerio A; NICER Working Group. Overdiagnosis and overtreatment of thyroid cancer: A population-based temporal trend study. *PLoS One.* 2017 Jun 14;12(6):e0179387. doi: 10.1371/journal.pone.0179387.
7. Saint-Martin C, Dramé M, Dabakuyo S, Kanagaratnam L, Arveux P, Schwartz C. Overdiagnosis of thyroid cancer in the Mame and Ardennes Departments of France from 1975 to 2014. *Ann Endocrinol (Paris).* 2017 Feb;78(1):27-32. doi: 10.1016/j.ando.2016.07.005.
8. Sanabria A, Kowalski LP, Shah JP, Nixon IJ, Angelos P, Williams MD, Rinaldo A, Ferlito A. Growing incidence of thyroid carcinoma in recent years: Factors underlying overdiagnosis. *Head Neck.* 2018 Apr;40(4):855-866. doi: 10.1002/hed.25029.
9. Kikuta S, Iwanaga J, Kusukawa J, Tubbs RS. Triangles of the neck: a review with clinical/surgical applications. *Anat Cell Biol.* 2019 Jun;52(2):120-127. doi: 10.5115/acb.2019.52.2.120.
10. Singh M, Vashistha A, Chaudhary M, Kaur G. Forgotten triangles of neck. *Ann Maxillofac Surg.* 2016 Jan-Jun;6(1):91-3. doi: 10.4103/2231-0746.186149.
11. Pattashanee SK, Puri G, Kataria K, Ranjan P, Dhar A, Srivastava A, Vyas S, Gupta Y, Pandey RM. Comparison of Modified Rose Method of Thyroid Palpation Versus Other Methods for the Detection of Retrosternal and Nodular Goitre. *J ASEAN Fed Endocr Soc.* 2022;37(1):4-13. doi: 10.15605/jafes.037.01.02.
12. Ha HJ, Lee J, Kim DY, Kim JS, Shin MS, Noh I, Koh JS, Kim EJ, Lee SS. Utility and Limitations of Fine-Needle Aspiration Cytology in the Diagnosis of Lymphadenopathy. *Diagnostics (Basel).* 2023 Feb 14;13(4):728. doi: 10.3390/diagnostics13040728.
13. Domanski HA. Role of fine needle aspiration cytology in the diagnosis of soft tissue tumours. *Cytopathology.* 2020 Jul;31(4):271-279. doi: 10.1111/cyt.12836.
14. Kumari KA, Jadhav PD, Prasad C, Smitha NV, Jojo A, Manjula VD. Diagnostic Efficacy of Ultrasound-Guided Fine

- Needle Aspiration Combined with the Bethesda System of Reporting. *J Cytol.* 2019 Apr-Jun;36(2):101-105. doi: 10.4103/JOC.JOC\_168\_16.
15. Taha I, Al-Thani H, El-Menyar A, Asim M, Al-Sulaiti M, Tabea A. Diagnostic accuracy of preoperative palpation-versus ultrasound-guided thyroid fine needle aspiration cytology: an observational study. *Postgrad Med.* 2020 Jun;132(5):465-472. doi: 10.1080/00325481.2020.1741298.
  16. Yoon JH, Lee HS, Kim EK, Moon HJ, Park VY, Kwak JY. Follow-Up Strategies for Thyroid Nodules with Benign Cytology on Ultrasound-Guided Fine Needle Aspiration: Malignancy Rates of Management Guidelines Using Ultrasound Before and After the Era of the Bethesda System. *Thyroid.* 2019 Sep;29(9):1227-1236. doi: 10.1089/thy.2018.0769.
  17. Feier J, Self Q, Karabachev A, Brundage W, Sajisevi M. Assessing the role of ultrasound for the evaluation of adult neck masses. *Laryngoscope Investig Otolaryngol.* 2022 Dec 21;8(1):135-139. doi: 10.1002/liv.2.995. PMID: 36846436; PMCID: PMC9948592.