

ROLE OF IMMUNOHISTOCHEMICAL MARKERS MLH1, MSH2, PMS2 IN IDENTIFYING MICROSATELLITE INSTABILITY IN COLORECTAL CARCINOMA

R. Shobija¹, L. Mohanapriya², P. Vanipriya³, Geetha Devadas⁴, K.Vani⁵

Received : 29/10/2024
Received in revised form : 14/12/2024
Accepted : 31/12/2024

Keywords:

Microsatellite instability, Mismatch repair, Colorectal carcinomas.

Corresponding Author:

Dr. K. Vani,
Email: vanikaliappan@gmail.com

DOI: 10.47009/jamp.2025.7.1.13

Source of Support: Nil,
Conflict of Interest: None declared

Int J Acad Med Pharm
2025; 7 (1); 55-60



¹Assistant Professor, Department of Pathology, Government Thoothukudi Medical College, Tamilnadu, India

²Assistant Professor, Department of Pathology, Government Namakkal Medical College, Tamilnadu, India

³Assistant Professor, Department of Pathology, Government Thiruvallur Medical College, Tamilnadu, India

⁴Retired Professor, Institute of Pathology, Madras Medical College-Chennai, Tamilnadu, India

⁵Assistant Professor, Institute of Pathology, Madras Medical College-Chennai, Tamilnadu, India

Abstract

Background: Colorectal cancers are a leading cause of mortality and morbidity throughout the world. Up until now classic disease staging remains the main modality of predictor of prognosis and treatment options. So the need for certain easily available prognostic markers are still under search. One such indicator is by assessing the Microsatellite instability by Immunohistochemistry. In this study, we evaluate the status of MLH1,MSH2,PMS2 expression in Colorectal carcinoma and the proportion of MSI-H and MSS/MSI-low tumors thereby aiding in prognosis and immunotherapy. **Materials and Methods:** This is a retrospective and prospective study conducted in the Institute of Pathology-Madras Medical College, Rajiv Gandhi Government general hospital for a period of 2 years from June 2017- June 2019 after getting prior approval from Institution Ethics Committee with IEC Reg No.ECR/270. The Hemicolectomy specimens with the clinical details of respective patient are collected. Corresponding HPE slides are prepared from formalin fixed paraffin embedded tissue of Hemicolectomy specimens. Blocks of histopathologically proven colorectal carcinomas are taken up for MLH1,MSH2,PMS2 immunohistochemical staining. **Result:** In this study the alternative method of having 2 antibody panel of MLH 1 and MSH2 instead of the routine 4 antibody panel of MLH1 ,MSH2, MSH6,PMS2 can be considered as a preliminary step in identifying microsatellite instability in colorectal cancer since patients of MSI-H tumors respond well with immunotherapy. Testing for MSI must be done for all colorectal cancer patients, especially those younger than 50 years old and high-grade CRCs. **Conclusion:** Testing for MSI should be done for all colorectal cancer patients, especially those younger than 50 years old and high grade colorectal cancers thereby aiding in providing targeted immunotherapy to MSI-H patients.

INTRODUCTION

Colorectal carcinoma is a major cause of mortality and morbidity throughout the world. It accounts for around 9% of all cancer incidence. It is the third most common cancer worldwide and the fourth most common cause of death.^[1] There are similar incidence rates for cancer of the colon in both sexes, and a slight male predominance for rectal cancer.^[2] More than 90% of colorectal cancer cases tend to occur in people aged 50 or older.^[3,4] However, colorectal carcinomas appears to be increasing

among young persons recently.^[5] Cases occurring in the young are mostly located on the distal colon and rectum and show features associated with aggressive behavior.^[6]

Majority of colorectal cancer cases are sporadic (about 75 %) which display no evidence of having inherited disorders, whereas only 25 % of the patients tend to have family history of the disease.^[7] Both environmental and genetic factors play an important role in the aetiology of colorectal cancer.^[8] Fat is considered as the possible etiological agent because it favors the development of a bacterial flora and

capable of degrading bile salts to potentially carcinogenic N-nitroso compounds.^[9,10] In addition, some studies suggest that people having diet low in fruits and vegetable fiber may have a higher risk of colorectal cancer.^[11] Regular consumption of alcohol, lack of physical activity in daily routine, cigarette smoking attributed to the increased incidence of obesity in men and women are all associated with increased risk of colorectal cancer.^[12,13] Neoplastic polyps of the colorectum, namely tubular and villous adenomas, are considered precursor lesions of colorectal cancer.^[14] Inflammatory bowel disease tend to increase an individual's overall risk of developing colorectal cancer.^[15] Approximately 5 to 10% of colorectal cancers are considered a consequence of hereditary conditions. The most common inherited conditions are familial adenomatous polyposis (FAP) and hereditary nonpolyposis colorectal cancer (HNPCC), also called Lynch syndrome.^[1]

MSI is a kind of genomic instability arising when mutations occur in nucleotide repeat sequences throughout the genome. These repeat sequences are known as microsatellites, and the discrepancy which arises between these sequences in tumor and germline cells is known as microsatellite instability.^[17] MSI arises from defects in the DNA mismatch repair (MMR) system which corrects any errors made by DNA polymerases during the replication of DNA.^[18] Lynch Syndrome is caused by autosomal dominant heterozygous germline mutations in one of the four main MMR genes — the mutL homologue 1 (MLH1) (chromosome 3p21.3), mutS homologue 2 (MSH2) (chromosome 2p22–21), mutS homologue 6 (MSH6) (chromosome 2p16) or postmeiotic segregation increased 2 (PMS2) (chromosome 7p22.2) genes.^[19] MSI sporadic CRCs were caused primarily by somatically acquired hypermethylation of both alleles of the MLH1 promoter.^[20]

In this study we evaluated the role of immunohistochemical markers MLH1, MSH2, PMS2 in identifying microsatellite instability in colorectal carcinoma and correlated their expression with various clinico-pathologic variables like age, gender, family history, tumor site, grade, stage, histological characteristics that might help in risk stratification and patient management.

Aims and Objectives

To evaluate the role of immunohistochemical markers MLH1, MSH2, PMS2 in identifying microsatellite instability.

To correlate the immunohistochemical expression of these markers with various clinico pathological variables like age, gender, family history, tumor site, grade, stage, histological characteristics thereby aiding in prognosis and treatment.

MATERIALS AND METHODS

Study design and setting: In this study, we performed both prospective and retrospective analysis of

patients who were diagnosed to have biopsy proven Colorectal carcinoma over a period of two years from June 2017 to June 2019 in Institute of Pathology, Madras medical College, Rajiv Gandhi Government General hospital, Chennai after getting prior approval from Institution Ethics Committee with IEC Reg No.ECR/270.

During our study period, we received 23,348 specimens for Histopathological examination. Of the total specimens 234 cases of colectomy specimens and 952 cases of colonic small biopsies were received. All 234 colectomy specimens were subjected for Histopathological examination and 112 cases were reported as low grade colorectal carcinomas, 87 cases were high grade colorectal carcinomas, 9 cases diagnosed as other malignant colorectal neoplasms, 26 cases showed features of benign and nonneoplastic conditions

Inclusion Criteria

All colectomy specimens which were histologically diagnosed as colonic and colorectal carcinomas irrespective of age, gender, grade and stage was included in this study.

Exclusion Criteria

- Lack of representative tumor tissue
- Patients treated with chemotherapy or radiotherapy prior to surgery

Data Collection: Detailed history of the cases regarding age, sex, family history, associated polyposis, type of procedure done were obtained for all 199 cases reported during the study period from surgical pathology records. Representative sections were taken from Hemicolectomy, APR, Anterior Resection specimens after subjecting for routine Histopathological examination. The following clinical and pathologic parameters were evaluated: Age, Gender, Tumor site, Size, Tumor grade, Stage, Tumor invasion, Lymphovascular invasion, Perineural invasion. Colorectal Carcinomas are graded as high grade and low grade based on architecture. Among 199 cases 50 cases were selected randomly. Out of 50 cases 42 cases were low grade and 8 cases were high grade. These 50 cases were analysed for immunohistochemical expression of MLH1, MSH2, PMS2.

Immunohistochemical analysis of MLH 1, MSH 2, PMS 2 were performed in paraffin embedded tissue samples using super sensitive polymer HRP system based on non biotin polymer technology. 4 micron thick sections were cut from formalin fixed paraffin embedded tissue samples and transferred onto positively charged slides. Heat induced antigen retrieval was done. The antigen was bound with mouse monoclonal antibody against MLH 1 and rabbit monoclonal antibody against MSH2, PMS2 and then detected by adding secondary antibody conjugated with horse radish peroxidase -polymer and diaminobenzidine substrate. The antibody treated slides were analyzed for the presence or absence of reaction, localization of staining pattern, percentage of cells stained and intensity of the reaction

Evaluation of MLH1, MSH2, PMS2 Staining:

For assessing the positivity scoring system as mentioned by Venetia R Sarode et al²¹ is followed. According to this system only nuclear staining pattern with appropriate staining of internal and external controls was considered positive (Retained expression) and the level of MLH1,MSH2,PMS2 expression was assessed semi quantitatively by the intensity and percentage of cells stained on a scale of 0-3+.Cytoplasmic staining was considered nonspecific. Non-neoplastic colonic mucosa, stromal cells, infiltrating lymphocytes or the centres of lymphoid follicles, were used as positive internal controls.

Score	Localization	Intensity	Percentage of cells stained
Score 0	Nil	Nil	No cell stained
Score 1+	Nuclear	Weak	More than 10%
Score 2+	Nuclear	Moderate	More than 10%
Score 3+	Nuclear	Strong	More than 10%

There is an entity called Indeterminate when less than 10 % tumor cell nuclei show positive staining which indicates further workup in that patient. Since the immunohistochemical expression of these markers can even be focal lack of staining in a small biopsy sample may not be reliably interpreted as loss of protein in the entire tumor, thus limiting the utility of IHC in small biopsy specimens.

Cases were categorised into positive (nuclear staining within tumor cells) and negative (complete absence of nuclear staining within tumor cells with concurrent internal positive controls). Then cases were interpreted as Microsatellite stable (MSS) when all the three antibodies show positive nuclear staining of the tumor cells, as Microsatellite unstable low (MSI-L) when one antibody shows negative nuclear staining of the tumor cells and as Microsatellite unstable high (MSI-H) when two antibodies or more show negative nuclear staining of the tumor cells.

Statistical Analysis: The statistical analysis was performed with IBM-SPSS statistical package for the social sciences version 20. An initial analysis of collected variables was performed. Immunohistochemical analysis of MLH1, MSH2, PMS2 were analyzed and correlated with clinical variables like age, gender, size, site and pathologic variables like histologic grade, stage. Pearson Chi square test was used in analyzing these variables. Immunohistochemical correlation of MMR status with age, sex, site, stage, and grade were analysed. In the present study, the P value below 0.05 is considered significant.

RESULTS

Total of 50 cases were included in the final analysis. In our study youngest patient was 28 years and oldest was 70 years. Majority of cases were in between 31-40 years with male preponderance.

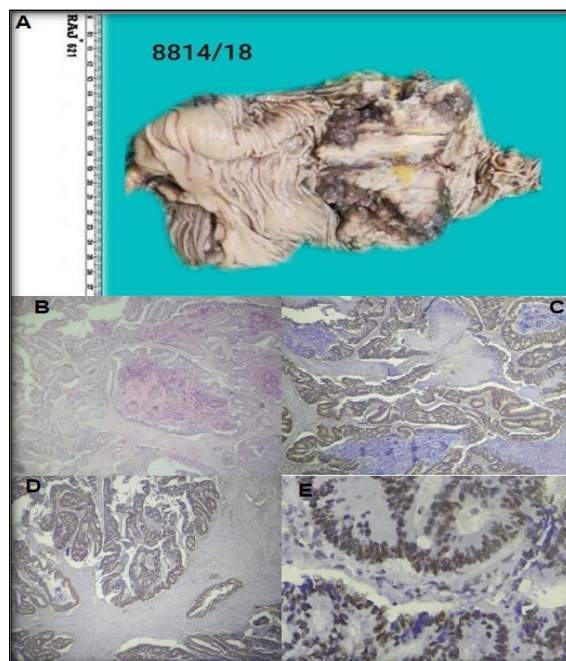


Figure 1:
A: Anterior Resection - Ulceroproliferative Growth Sigmoid Colon
B: Moderately differentiated Adenocarcinoma:50- 95% gland formation with characteristic dirty necrosis (100x)
C: MLH 1 strong nuclear positivity
D: PMS 2 strong nuclear positivity
E: MSH 2 strong nuclear positivity
Microsatellite Stable (MSS)

In our study, among 50 cases the commonest histologic subtype is Adenocarcinoma NOS constituting 74 % in 37 cases followed by poorly differentiated adeno carcinoma constituting 14% in 7 cases, mucinous adenocarcinoma constituting 10 % in 5 cases and signet ring cell adenocarcinoma constituting 2% in 1 case.

Other rare histologic subtypes like Squamous cell carcinoma, undifferentiated carcinoma and other malignant neoplasms like neuroendocrine tumor, malignant Gastrointestinal stromal tumor, Lymphoproliferative disorder was also been reported in our institute.

Both MLH-1 and PMS-2 were positive in 38% of cases (19 cases), both were lost in 56% (28 cases), and PMS-2 loss without MLH-1 loss was seen in 4%(2 cases). MLH -1 positive in 42% (21 cases),negative in 56%(28 cases),PMS 2 positive in 38%(19 cases),negative in 60%(30 cases),MSH-2 was positive in 58% of cases(29 cases) negative in 42% of cases (21 cases) MLH-1,PMS 2 shows indeterminate staining in 2%(1 case).Accordingly 30% (15cases) of cases were MSS, 12% (6 cases) were MSI-L, and 56%(28 cases) were MSI-H,1 case showed indeterminate staining-2%.

Microsatellite Stable (MSS)

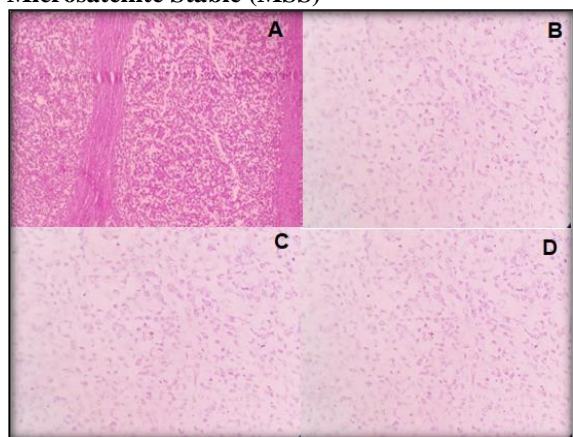


Figure 2: A) SIGNET RING CELL Adenocarcinoma: >50% Tumor cells showing signet ring cell features (100x) B) MLH 1 negative staining C) PMS 2 negative staining D) MSH 2 negative staining Microsatellite Unstable-High (MSI-H)

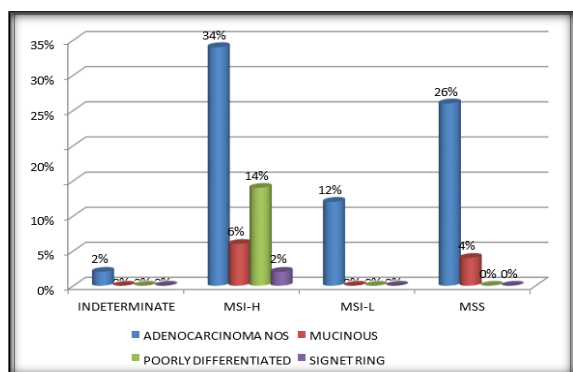


Figure 3: Correlation of MMR Status with Histologic Subtype

Pearson Chi-Square=8.799 p=0.456

In our study of 50 cases MSI-H showed predominant histologic pattern of Adenocarcinoma NOS(34% in

17 cases) followed by poorly differentiated carcinomas(14% in 7 cases) then mucinous adenocarcinoma (6% in 3 cases) and signet ring cell adenocarcinoma (2 in 1 case),MSI-L showed Adenocarcinoma NOS (12% in 6 cases),MSS showed Adenocarcinoma NOS (26 % in 13 cases),Indeterminate showed Adenocarcinoma NOS (2% in 1 case).There was no significant statistical correlation between MMR status and histologic type of colorectal carcinomas.

Pearson Chi-Square=2.103 p=0.551

In our study of 50 cases MSI-H cases were predominantly seen in proximal region (36% in 18 cases), MSI-L tumors were seen predominantly in proximal region (8% in 4 cases), MSS tumors were seen predominantly in distal region (16% in 8 cases), Indeterminate tumors were seen in proximal region (2% in 1 case). There was no significant statistical correlation between MMR status and site of colorectal carcinomas.

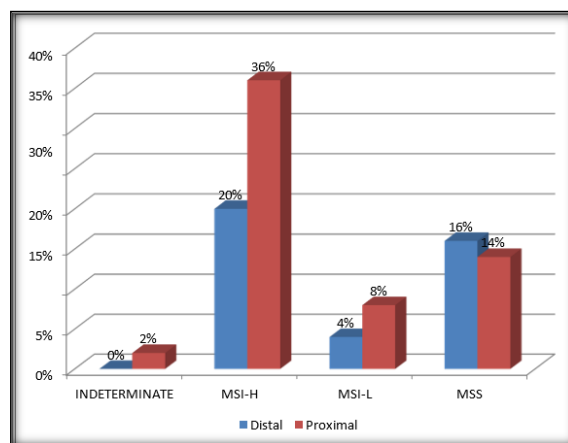


Figure 4: correlation of MMR status with site

Table 1: Age and sex wise distribution of cases.

Age group (years)	No. of cases	Males	Females
21-30	7	3	4
31-40	13	10	3
41-50	11	7	4
51-60	8	6	2
61-70	11	6	5
Total	50	32	18

Table 2: Total number of colorectal carcinomas diagnosed during study period

Histologic_type	Frequency	Percent
Adenocarcinoma NOS	37	74.0
Mucinous Adenocarcinoma	5	10.0
Poorly Differentiated Adenocarcinoma	7	14.0
Signet Ring Cell Adenocarcinoma	1	2.0
Total	50	100.0

DISCUSSION

Colorectal cancers are a leading cause of mortality and morbidity throughout the world. There are similar incidence rates for cancer of colon in both sexes and slight male predominance for rectal cancer.^[2]

Up until now classic disease staging remains the main modality of predictor of prognosis and treatment options. Though there exists various prognostic indicators like age, site, tumor histology, grade, lymphovascular invasion, perineural invasion search for certain easily available prognostic markers which could serve in the segregation of patients more likely to respond to chemotherapy and immunotherapy are

still under search. One such indicator is by assessing the Microsatellite instability by Immunohistochemistry.

Majority of colorectal cancers display chromosomal instability and follow the classical adenoma-carcinoma progressive pathway. 15% colorectal cancers display DNA mismatch repair deficiency and shows microsatellite instability. In Familial form genetic basis of instability is largely due to inherited mutations of MMR genes (MLH1, MSH 2, MSH6, PMS2). In sporadic form it is mainly due to MLH1 inactivation due to epigenetic hypermethylation of promoter.

The presence of MSI predicts a good outcome in colorectal cancer²². It was reported that the survival rate of CRC patients with MSI is up to 15% higher as compared with that of CRC patients with microsatellite stable (MSS) tumors. MSI-H tumors tend to express high level of checkpoint proteins including programmed death 1 (PD-1) and programmed death ligand 1 (PDL1) which interfere with body's antitumor T cell response. By disabling these proteins, checkpoint inhibitors enable T cells to attack and kill tumor cells indicating good prognosis with immunotherapy.

In this present study Immunohistochemistry was done on 50 cases and evaluated the status of expression of MLH1, MSH2, PMS 2 and the proportion of MSI-H, MSI-L and MSS tumors thereby aiding in prognosis and immunotherapy.

During the study period of 24 months from June 2017-June 2019 234 colectomy specimens were received. Of these 112 cases were reported as low-grade colorectal carcinomas, 87 as high-grade colorectal carcinomas, 9 as other malignant colorectal neoplasms, 26 benign and non-neoplastic conditions.

In our study of 50 cases MLH1 and PMS2 were positive in 36%, both were lost in 56% cases and PMS2 loss without MLH1 loss seen in 6% cases. According to Eman M. Salem et al MLH1 and PMS2 were positive in 61.5% cases, both were lost in 30.8% cases and PMS2 loss without MLH1 loss seen in 7.7% cases.

So with this study the alternative method of having 2 antibody panel of MLH 1 and MSH2 instead of the routine 4 antibody panel of MLH1, MSH2, MSH6, PMS2 can be considered as a preliminary step in identifying microsatellite instability in colorectal cancer.^[21]

In this present study MSI-H tumors were predominantly Adenocarcinoma NOS (34%), seen in proximal region (36%) in 30-60 years age group (42%) and stage III (26%). According to Suzaan M. Talaat et al MSI-H tumors were Predominantly Adenocarcinoma NOS (23.1%), seen in proximal region (21.2%), stage III thus correlating with our study.^[22]

In this present study MSI-L tumors were predominantly Adenocarcinoma NOS (12%), seen in proximal region (8%) in 30-60 years age group (8%) and stage II (6%). According to Suzaan M. Talaat et al

MSI-L tumors were predominantly Adenocarcinoma NOS (11.5%), seen in distal region (21.2%), stage III thus correlating with our study.^[23]

In this present study MSS tumors were predominantly Adenocarcinoma NOS (18%), seen in distal region (16%) in 30-60 years age group (8%) and stage III (14%). According to Suzaan M. Talaat et al MSI-L tumors were predominantly Adenocarcinoma NOS (48.1%), seen in distal region (45%), stage III thus correlating with our study.

Limitations of the Study

Through these discussions, limitations of the present study were also noted.

The cases were selected on the basis of Histopathological classification in a tertiary care centre and not a population-based study, which will not reflect the true prevalence of the general population

Establishing the presence of MSI requires PCR based technology by examining DNA sequences of tumor tissue. They give more accurate results in identifying microsatellite instability however the disadvantage being very expensive

Different patterns of staining have caused much confusion in interpretation-Focal staining, Lack of positive internal control and cytoplasmic staining. With experience accurate interpretation by IHC staining is still easily achievable

CONCLUSION

This is a hospital based study and may not represent the true incidence of disease in the community. As many patients present with advanced disease the need for easily available less expensive prognostic marker is increasing and this can be accomplished by using the two antibody panel of Immunohistochemical markers MLH1 and MSH2 so that MSI-H patients can be easily identified and they can be given targeted immunotherapy to which the response is very good. Further studies are needed on the molecular characteristics of certain histologic types and it will improve our understanding of their prognostic implications and contribute to the tailored treatment.

REFERENCES

1. Colorectal Cancer Epidemiology: Incidence, Mortality, Survival, and Risk Factors Fatima A. Hagggar, Robin P. Boushey Clin Colon Rectal Surg. 2009 Nov; 22(4): 191-197. doi: 10.1055/s-0029-1242458.
2. World Cancer Research Fund and American Institute for Cancer Research Food, Nutrition, Physical Activity, and the Prevention of Cancer: A Global Perspective. Washington, DC: American Institute for Cancer Research; 2007.
3. National Institutes of Health What You Need To Know About Cancer of the Colon and Rectum. Bethesda, MD: U.S. Department of Health and Human Services & National Institutes of Health; 2006.
4. Ries L AG, Melbert D, Krapcho M, et al. SEER cancer statistics review, 1975-2005. Bethesda, MD: 2008.
5. American Cancer Society Colorectal Cancer Facts & Figures Special Edition 2005. Oklahoma City, OK: American Cancer Society; 2005; Accessed May 26, 2009.

6. Yantiss RK ,Goodarzi M,Zhou XK,Rennert H,Pirog EC,Banner BF,Chen YT.Clinical,pathologic,and molecular features of early -onset colorectal carcinoma.Am J Surg Pathol 2009,33:572-582.
7. Jasperson KW, Tuohy TM, Neklason DW, Burt RW. Hereditary and familial colon cancer. *Gastroenterology*. 2010;138:2044–58.
8. Ernst J. Kuipers, William M. Grady, David Lieberman, Thomas Seufferlein, Joseph J. Sung, Petra G. Boelens, Cornelis J. H. van de Velde, Toshiaki Watanabe, „COLORECTAL CANCER”, *Nat Rev Dis Primers*. Author manuscript; available in PMC 2016 Nov 5.
9. Jackson-Thompson J, Ahmed F, German R R, Lai S M, Friedman C. Descriptive epidemiology of colorectal cancer in the United States, 1998- 2001. *Cancer*. 2006;107(5, Suppl):1103–1111.
10. Larsson S C, Wolk A. Meat consumption and risk of colorectal cancer: a meta-analysis of prospective studies. *Int J Cancer*. 2006;119(11):2657–2664.
11. National Institutes of Health What You Need To Know About Cancer of the Colon and Rectum. Bethesda, MD: U.S. Department of Health and Human Services & National Institutes of Health; 2006.
12. de Jong A E, Morreau H, Nagengast F M, et al. Prevalence of adenomas among young individuals at average risk for colorectal cancer. *Am J Gastroenterol*. 2005;100(1):139–143.
13. Campbell P T, Cotterchio M, Dicks E, Parfrey P, Gallinger S, McLaughlin J
14. R. Excess body weight and colorectal cancer risk in Canada: associations in subgroups of clinically defined familial risk of cancer. *Cancer Epidemiol Biomarkers Prev*. 2007;16(9):1735–1744.
15. Epidemiology of colorectal cancer, Janout V, Kollárová H, *Biomed Pap Med Fac Univ Palacky Olomouc Czech Repub*. 2001 Sep; 145(1):5-10.
16. National Institutes of Health What You Need To Know About Cancer of the Colon and Rectum. Bethesda, MD: U.S. Department of Health and Human Services & National Institutes of Health; 2006.
17. Worthley DL, Leggett BA. Colorectal cancer: molecular features and clinical opportunities. *Clin Biochem Rev*. 2010;31:31–38.
18. Boland CR, Goel A. Microsatellite instability in colorectal cancer. *Gastroenterology*. 2010;138(6): 2073-87. <https://doi.org/10.1053/j.gastro.2009.12.064> PMID:20420947 PMCid:PMC3037515.
19. Vilar E, Gruber SB. Microsatellite instability in colorectal cancer e the stable evidence. *Nat Rev Clin Oncol*. 2010; 7(3): 153-62. <https://doi.org/10.1038/nrclinonc.2009.237> PMID:20142816 PMCid:PMC3427139.
20. Heald B, Church J, Plessec T, et al. Detecting and managing hereditary colorectal cancer syndromes in your practice. *Cleveland clinic journal of medicine*. 2012; 79 (11): 787-796. <https://doi.org/10.3949/ccjm.79a.11165> PMID:2312532.
21. Deng G, Bell I, Crawley S, et al. BRAF mutation is frequently present in sporadic colorectal cancer with methylated hMLH1, but not in hereditary nonpolyposis colorectal cancer. *Clin Cancer Res*. 2004; 10: 191–195. <https://doi.org/10.1158/1078-0432.CCR-1118-3> PMID:14734469.
22. Sarode VR, Robinson L. Screening for Lynch Syndrome by Immunohistochemistry of Mismatch Repair Proteins: Significance of Indeterminate Result and Correlation With Mutational Studies. *Arch Pathol Lab Med*. 2019 Oct;143(10):1225-1233. doi: 10.5858/arpa.2018-0201-OA. Epub 2019 Mar 27. PMID: 30917047.
23. Gryfe R, Kim H, Hsieh ET, Aronson MD, Holowaty EJ, Bull SB, Redston M, Gallinger S, “Tumor microsatellite instability and clinical outcome in young patients with colorectal cancer”, *N Engl J Med*. 2000 Jan 13; 342(2):69-77.