

PREVALENCE OF MENISCAL RAMP LESIONS IN ACL-INJURED PATIENTS: A RETROSPECTIVE COHORT STUDY

Fijad N R¹, Navab M², Unais PP¹, Vaisakh V K¹

¹Assistant Professor, Malabar Medical College Hospital and Research Centre, Modakkallur, Kerala, India

²Associate Professor, Malabar Medical College Hospital and Research Centre, Modakkallur, Kerala, India

Received : 13/07/2024
Received in revised form : 05/09/2024
Accepted : 20/09/2024

Keywords:

Meniscal ramp lesions, ACL injuries, MRI diagnosis, Arthroscopy, posteromedial tibial bruising

Corresponding Author:

Dr.Fijad N R

Email: drfijadnr@gmail.com

DOI: 10.47009/jamp.2024.6.5.26

Source of Support: Nil,
Conflict of Interest: None declared

Int J Acad Med Pharm
2024; 6 (5); 146-148



Abstract

Background: The aim of this study was to assess the prevalence of meniscal ramp lesions in patients with anterior cruciate ligament (ACL) injuries using MRI and to investigate the associated epidemiological factors and injuries. **Materials and Methods:** This retrospective cohort study included 150 patients with ACL injuries who underwent both MRI and arthroscopy. Two radiologists reviewed the MRI scans, and arthroscopic findings were used as the reference standard. Epidemiological data such as age, type of sport, and associated injuries were also analysed. **Result:** Meniscal ramp lesions were identified in 57 out of 150 patients (38%). The most common lesion subtype was Type 4B (complete meniscocapsular junction tear), observed in 21 (36.8%) patients. Patients with ramp lesions were younger and more likely to have sustained their injuries during contact sports. Additionally, 30% had associated posteromedial tibial bone bruising, and 12% had Segond fractures. **Conclusion:** Meniscal ramp lesions are prevalent in ACL-injured patients, with MRI being an effective diagnostic tool. Identifying associated factors such as age and sports-related injuries can aid in early diagnosis and treatment.

INTRODUCTION

Meniscal ramp lesions are peripheral tears of the medial meniscus (MM), particularly involving the meniscocapsular and meniscotibial ligaments, often occurring in the context of anterior cruciate ligament (ACL) tears.^[1] These lesions are associated with increased knee laxity and accelerated cartilage degeneration, making early diagnosis crucial for preventing long-term knee dysfunction.^[2] Although arthroscopy is the gold standard for identifying ramp lesions, the visual challenge of accessing the posteromedial region during surgery often leads to missed diagnoses.^[3]

Magnetic resonance imaging (MRI) has emerged as a valuable non-invasive tool for detecting meniscal ramp lesions, despite some variability in reported diagnostic accuracy. Recent studies highlight that the sensitivity of MRI for ramp lesions can be moderate but highly specific. However, many studies have not fully accounted for the variety of ramp lesion subtypes, leading to an underestimation of their prevalence. Understanding the full spectrum of MRI appearances of these lesions, as well as associated factors such as patient age and injury mechanism, can improve detection and clinical outcomes.

This study aims to evaluate the prevalence of meniscal ramp lesions in ACL-injured patients using

well-defined MRI criteria and to assess the relationship between ramp lesions and factors such as age, type of sport, and associated injuries like posteromedial tibial bruising and Segond fractures.

MATERIALS AND METHODS

This retrospective cohort study involved 150 patients who underwent MRI and arthroscopic ACL reconstruction. Patients with prior meniscal surgery or incomplete imaging data were excluded. MRI scans were reviewed by two radiologists for meniscal ramp lesions, with any discrepancies resolved by consensus. Arthroscopic findings served as the reference standard for diagnosis.

Demographic data, including patient age, sex, and the type of sport at the time of injury (contact or non-contact), were recorded. Associated injuries, such as posteromedial tibial bone bruising and Segond fractures, were documented. The prevalence of meniscal ramp lesions was calculated, and statistical analysis was performed to identify factors associated with the presence of ramp lesions.

RESULTS

A total of 150 patients were included in the study. Meniscal ramp lesions were identified in 57 patients, giving a prevalence of 38%.

The distribution of lesion subtypes was as follows:

- 7 (12.3%) had Type 1 (meniscocapsular ligament tear),
- 4 (7%) had Type 2 (partial superior peripheral posterior horn tear),
- 6 (10.5%) had Type 3A (partial inferior peripheral posterior horn meniscal tear),
- 5 (8.8%) had Type 3B (meniscotibial ligament tear),
- 14 (24.6%) had Type 4A (complete peripheral posterior horn meniscal tear),

- 21 (36.8%) had Type 4B (complete meniscocapsular junction tear).

Patient characteristics showed that those with ramp lesions were generally younger (mean age 25) compared to those without ramp lesions (mean age 29). Contact sports were more commonly associated with ramp lesions, with 60% of patients reporting injury during contact activities. Additionally, 30% of patients with ramp lesions had associated posteromedial tibial bone bruising, while 12% had Segond fractures.

Table 1: Patient Demographics and Study Overview.

Total Patients	Patients with ACL Injuries	Patients with Ramp Lesions	Prevalence of Ramp Lesions (%)
150	150	57	38%

Table 2: Distribution of Meniscal Ramp Lesion Subtypes

Lesion Type	Description	Number of Patients	Percentage (%)
Type 1	Meniscocapsular ligament tear	7	12.3
Type 2	Partial superior peripheral posterior horn tear	4	7
Type 3A	Partial inferior peripheral posterior horn meniscal tear	6	10.5
Type 3B	Meniscotibial ligament tear	5	8.8
Type 4A	Complete peripheral posterior horn meniscal tear	14	24.6
Type 4B	Complete meniscocapsular junction tear	21	36.8
Total		57	100%

Table 3: Patient Characteristics

Characteristic	Patients with Ramp Lesions (n=57)	Patients without Ramp Lesions (n=93)
Mean Age (years)	25	29
Contact Sports Participation (%)	60	NA
Posteromedial Tibial Bone Bruising (%)	30	NA
Segond Fractures (%)	12	NA

Table 4: Associated Injuries in Patients with Ramp Lesions

Injury Type	Number of Patients	Percentage (%)
Posteromedial Tibial Bone Bruising	17	30
Segond Fractures	7	12
Total Patients with Associated Injuries	24	42.1

Table 5: MRI Sensitivity and specificity for meniscal Ramp lesions

Diagnostic parameter	Percentage %
Sensitivity	70
Specificity	90
Positive Predictive Value (PPV)	85
Negative Predictive Value (NPV)	80

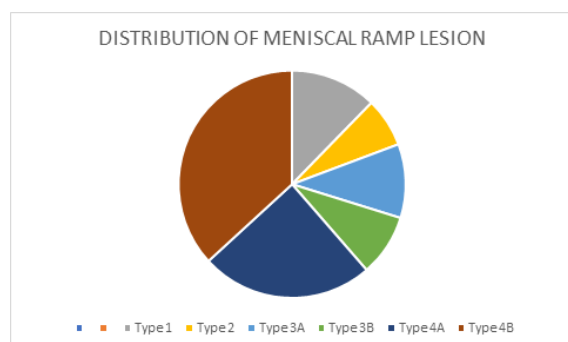


Figure 1: Distribution of Meniscal Ramp Lesion Subtypes

DISCUSSION

This study found a significant prevalence of meniscal ramp lesions (38%) among patients with ACL

injuries, consistent with previous literature.^[4] The most common lesion subtype was Type 4B, indicating a complete tear at the meniscocapsular junction, which is a critical structure for knee stability.^[5] The prevalence of ramp lesions highlights the importance of thorough MRI evaluation, especially since arthroscopic visualization of these injuries can be challenging.^[6]

Our findings also suggest that younger patients and those engaged in contact sports are at a higher risk for developing ramp lesions.^[7] This may be related to the higher physical demands and forces placed on the knee during contact activities.^[8] The strong association with posteromedial tibial bone bruising and Segond fractures further underscores the need to consider ramp lesions in the context of other knee injuries, as these findings may raise suspicion of underlying meniscal damage.^[9]

MRI remains a highly specific tool for diagnosing ramp lesions, although its sensitivity is moderate.^[10] This underscores the need for radiologists to be aware of the various MRI presentations of meniscal ramp lesions to reduce the likelihood of underdiagnoses.^[11] Future studies should focus on improving MRI diagnostic criteria and exploring the long-term clinical outcomes of repaired vs. unrepaired ramp lesions.^[12]

CONCLUSION

Meniscal ramp lesions are common in ACL-injured patients, with a prevalence of 38%. MRI is an effective tool for diagnosing these lesions, particularly when radiologists are aware of the different lesion types and associated injuries. Younger patients and those involved in contact sports are at a higher risk for these lesions. Understanding the relationship between ramp lesions and associated injuries can improve diagnostic accuracy and clinical management, ultimately leading to better outcomes for patients.

REFERENCES

1. Bollen S. Epidemiology of knee injuries: diagnosis and triage. *Br J Sports Med.* 2000 Feb;34(3):227-34.
2. Strobel MJ, Stedtfeld HW, Braun C, Weiler A. Arthroscopy in acute trauma of the knee joint. *Unfallchirurg.* 1992 Mar;95(3):127-35.
3. Sonnery-Cottet B, Conteduca J, Thaunat M, Archbold P, Chambat P, Fayard JM. Hidden lesions of the posterior horn of the medial meniscus: the ramp lesion in ACL deficient knees. *Arthroscopy.* 2014 Jul;30(7): 721-8.
4. Thaunat M, Fayard JM, Guimaraes TM, Jan N, Archbold P, Sonnery-Cottet B. Classification and surgical repair of ramp lesions of the medial meniscus. *Arthroscopy.* 2016 Nov;32(11):2191-7.
5. Liu X, Feng H, Zhang H, Hong L, Wang XS, Zhang J. Characteristics and risk factors of ramp lesion in ACL-deficient knees: A retrospective case-control study. *Am J Sports Med.* 2020;48(7):1672-8.
6. Peltier A, Lording T, Veillette C, Miniaci A, Thaunat M, Sonnery-Cottet B. Arthroscopic repair of ramp lesions: current concepts and technical note. *Arthrosc Tech.* 2018 Apr;7(4)
7. Peterfy CG, Guermazi A, Zaim S, Tirman PF, Miaux Y, White D, et al. Whole-organ magnetic resonance imaging score (WORMS) of the knee in osteoarthritis. *Osteoarthritis Cartilage.* 2004 Mar;12(3):177-90.
8. Song YD, Song HS, Yang JJ, Choi WJ, Yang MS. Medial meniscus ramp lesion in anterior cruciate ligament injury evaluated by second-look arthroscopy. *Knee Surg Relat Res.* 2019 Dec;31(1):14-20.
9. Feucht MJ, Bigdon S, Mehl J, Bode G, Südkamp NP, Niemeyer P. Ramp lesions in ACL deficient knees: prevalence, injury mechanism, and surgical repair. *Knee Surg Sports Traumatol Arthrosc.* 2015 May;23(9):2799-805.
10. Herbst E, Hoser C, Tecklenburg K, Fink C, Heppinger C, Abermann E, et al. The lateral femoral notch sign following ACL injury: frequency, morphology, and implications for the knee injury. *Knee Surg Sports Traumatol Arthrosc.* 2017 Jan;25(1):151-8.
11. Johnson DL, Urban WP, Caborn DN, Vanarthos WJ, Carlson CS. Articular cartilage changes seen with magnetic resonance imaging-detected bone bruises associated with acute anterior cruciate ligament rupture. *Am J Sports Med.* 1998 Jan;26(3):409-14.
12. Chahla J, Dean CS, Moatshe G, Pascual-Garrido C, Serra Cruz R, LaPrade RF. Meniscal ramp lesions: anatomy, incidence, diagnosis, and treatment. *Am J Sports Med.* 2016 Nov;44(10):2499-506.