

COMPARITIVE EFFICACY OF LIGNOCAINE NEBULIZATION AND AIRWAY NERVE BLOCK TECHNIQUES FOR AWAKE FIBEROPTIC OROTRACHEAL INTUBATION: A RANDOMIZED CONTROLLED STUDY

Charishma Basina¹, Rajesh Gollapalli², V. Ravi³, Anil Sarath Chandra Bura¹

Received : 07/05/2024
Received in revised form : 02/07/2024
Accepted : 17/07/2024

Keywords:

Awake fiberoptic intubation, cervical spine surgery, lignocaine nebulization, airway nerve blocks (ANB), anesthetic techniques. Hemodynamic stability.

Corresponding Author:

Dr. Anil Sarath Chandra Bura,
Email: burachandra@gmail.com.

DOI: 10.47009/jamp.2024.6.4.27

Source of Support: Nil,
Conflict of Interest: None declared

Int J Acad Med Pharm
2024; 6 (4); 128-131



¹Assistant Professor, Department of Anaesthesiology, Andhra Medical College, Visakhapatnam, Andhra Pradesh, India.

²Assistant Professor, Department of Anaesthesiology, Andhra Medical College, Visakhapatnam, Andhra Pradesh, India.

³Professor & HOD, Department of Anaesthesiology, Andhra Medical College, Visakhapatnam, Andhra Pradesh, India.

Abstract

Background: Awake fiberoptic intubation (AFOI) is a critical technique in managing difficult airways, providing a secure and visually guided method for tracheal intubation particularly in patients with cervical spine injuries.

Objective: This study aims to compare the efficacy of lignocaine nebulization and airway nerve blocks (ANBs) for achieving adequate airway anesthesia before AFOI-guided orotracheal intubation. **Materials and Methods:** The randomized study involved 40 adult patients divided into two groups: Group N (n=20) receiving 10 ml of 4% lignocaine nebulization plus transtracheal nerve block with 3ml of 4% lignocaine and Group A (n=20) undergoing ANBs with 2 ml of 2% lignocaine with adrenaline for bilateral superior laryngeal nerve block at hyoid & transtracheal instillation of 3ml of 4% lignocaine at the cricothyroid membrane. Parameters assessed include hemodynamic responses, quality of anesthesia, and adverse events. **Results:** The findings indicated no significant differences in demographic variables (age, weight and gender) between the groups and also no significant difference in hemodynamic parameters or anesthesia quality between the groups, suggesting both techniques are effective when supplemented with transtracheal injection. **Conclusion:** In conclusion, both the methods are effective for airway anesthesia when supplemented with transtracheal injection. The study suggests that lignocaine nebulization is a viable alternative. Further large-scale and multicentric studies are recommended to validate these findings and refine airway anesthesia techniques.

INTRODUCTION

The leading cause of morbidity and mortality related to anesthesia is airway management failures, with one-third of all anesthetic deaths attributed to the inability to intubate and ventilate.^[1] Despite advancements, flexible fiberoptic-guided intubation remains a primary approach for difficult airways,^[2,3] particularly in patients with cervical spine injuries.^[4] Awake intubation is often preferred to minimize risks.^[5] This study aims to compare the efficacy of nebulization and nerve block techniques in achieving upper airway anesthesia for awake fiberoptic intubation in cervical spine surgeries.

MATERIALS AND METHODS

This double-blind randomized controlled study was approved by the Institutional Ethical Committee of Andhra Medical College, Visakhapatnam and was conducted from October 2022 to May 2024.

Inclusion Criteria: Patients of age 20-60 years, Patients belong to ASA status I & II, Patients undergoing elective cervical spine surgery, Male and Female patients who provided Informed consent.

Exclusion Criteria: Patients of age <20 or >60 years, Patients belong to ASA status III, IV, & V, Patients with coexisting diseases (e.g., hypertension,

diabetes, seizure disorders), pulmonary pathology, pregnancy, coagulopathies and allergic to lignocaine.

Forty patients scheduled for elective cervical spine surgeries with difficult airways were randomly assigned to two groups: Group N (Nebulization) and Group A (ANB or Nerve Block).

Group N (Nebulization): 20 Patients received Nebulization of 4% lignocaine (10 ml) and transtracheal injection of 4% lignocaine (3 ml).

Group A (Nerve Block): 20 patients received Bilateral superior laryngeal nerve blocks with 2% lignocaine with adrenaline (2 ml) and transtracheal injection of 4% lignocaine (3 ml).

Patients received injection glycopyrrolate 0.2 mg iv and injection midazolam 1 mg iv for sedation and mucosal secretion reduction.

Orotracheal Intubation was performed using a 5.0-mm flexible fiber-optic bronchoscope with appropriate size Flexo-metallic Endotracheal Tube with heart rate (HR), mean arterial pressure (MAP),

and oxygen saturation (SPO2) measured at specified intervals.

Statistical Analysis: Hemodynamic data were analyzed using the unpaired t-test, and the quality of anesthesia was assessed using Pearson's chi-square test. P-values ≤ 0.05 were considered statistically significant.

RESULTS

Demographic data showed no significant differences between groups in age, weight, or gender distribution. Hemodynamic responses, including heart rate and MAP, showed no significant differences between groups during or after intubation. SPO2 levels were maintained within normal ranges in both groups. Quality of anesthesia was similar across both groups, with most patients experiencing no or mild coughing/gagging in both the groups (P - value > 0.005).

Table 1: Demographic Profile

Demography	Group N (n=20)	Group A (n=20)	P-value
Age (years)	45.3 \pm 10.24	44.7 \pm 10.46	0.183
Weight (kg)	62.7 \pm 5.64	59.4 \pm 21.11	0.67

Table 2: Sex Distribution

Sex	Group N	Group A
Males	15	15
Females	5	5

Table 3: Heart Rate Characteristics

Heart Rate (beats/min)	Group N (Mean \pm SD)	Group A (Mean \pm SD)	P-value
2 Min before	75.60 \pm 7.646	74.15 \pm 7.562	0.550
During the procedure (highest)	84.80 \pm 8.076	85.90 \pm 8.705	0.681
2 min after placement of ET tube	78.30 \pm 8.040	80.40 \pm 7.330	0.393

Table 4: Mean Arterial Pressure (MAP) Characteristics

MAP (mm Hg)	Group N (Mean \pm SD)	Group A (Mean \pm SD)	P-value
2 Min before	92.035 \pm 4.138	93.065 \pm 6.416	0.550
During the procedure (highest)	102.835 \pm 4.997	102.955 \pm 4.071	0.934
2 min after placement of ET tube	97.410 \pm 4.528	98.705 \pm 4.986	0.395

Table 5: Oxygen Saturation (SPO2) Characteristics

SPO2 (%)	Group N (Mean \pm SD)	Group A (Mean \pm SD)	P-value
2 Min before	99.90 \pm 0.308	99.80 \pm 0.696	0.560
During the procedure (lowest)	99.70 \pm 0.571	99.50 \pm 0.946	0.423
2 min after placement of ET tube	99.95 \pm 0.224	99.65 \pm 0.745	0.093

Table 6: Quality of Anesthesia Grading

Quality of Anaesthesia Grading	Group N	Group A	Total
Grade 0 (No coughing/gagging)	16	16	32
Grade 1 (Mild)	4	3	7
Grade 2 (Moderate)	0	1	1
Grade 3 (Severe)	0	0	0
Grade 4 (Very severe)	0	0	0

DISCUSSION

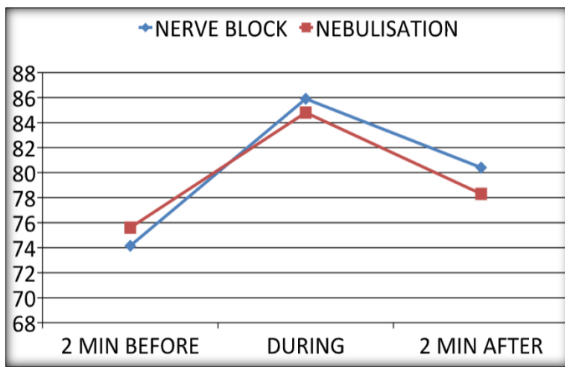


Figure 1: Line Graph Comparing Heart Rates Between Group N (Nebulization) & Group A (Nerve Block)

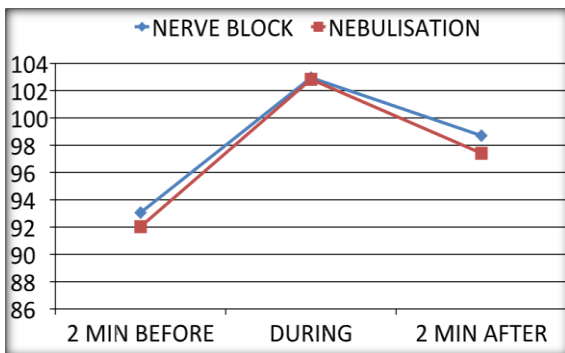


Figure 2: Line Graph Comparing Mean Arterial Pressure Characteristics between Group N (Nebulization) & Group A (Nerve Block)

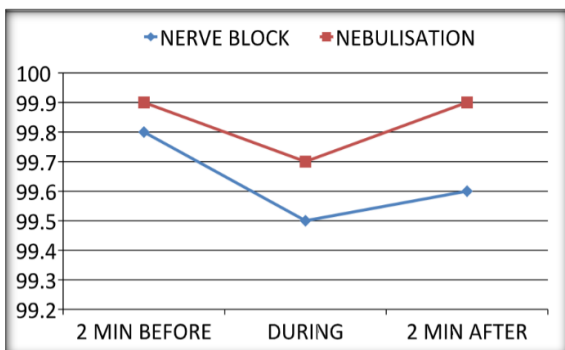


Figure 3: Line Diagram Comparing Saturation of Oxygen Characteristics Between Group N (Nebulization) & Group A (Nerve Block)

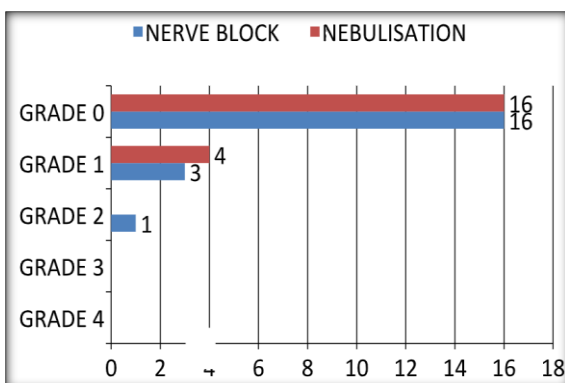


Figure 4: Bar Diagram showing the results of Quality of Anesthesia during procedure between the Group N (Nebulization) & Group A (Nerve Block)

Awake fiberoptic intubation offers a safe method for managing difficult airways, particularly in cervical spine surgeries. This study demonstrates that both nebulization and nerve block techniques, when supplemented with transtracheal lignocaine, provide effective anesthesia with comparable hemodynamic stability and patient comfort. The findings align with previous studies but highlight the importance of combining techniques to enhance anesthetic efficacy.

Airway nebulization along with transtracheal injection is straightforward and easy to administer even in obese patients, posing minimal trauma to the oropharyngeal structures. However, the use of large doses increases the risk of systemic toxicity when compared to the airway nerve blocks due to smaller doses.

Wang J et al,^[6] emphasized the safety and efficacy of nerve blocks over nebulization in reducing systemic lignocaine exposure and providing targeted anesthesia. In our study, no local anesthetic systemic toxicity occurred.

Smith et al,^[7] reported a higher incidence of coughing in nebulization without transtracheal injections, Kundra et al,^[8] observed higher mean HR, BP in the nebulization group than in the Nerve block group. But this study did not observe an increased incidence of coughing or gagging episodes in the nebulization group, and also found no significant difference in hemodynamic parameters (heart rate, mean arterial pressure, and oxygen saturation) between the two groups during and after the procedure likely due to the supplemental transtracheal lignocaine injection that enhanced anesthesia quality.

Furthermore, the quality of anesthesia, assessed by an observer, showed no significant differences between the two methods. Both techniques were effective in suppressing the gag, swallow, and cough reflexes, which are crucial for patient comfort during awake intubation. Gupta et al,^[9] found comparable efficacy between topical and nerve block methods when supplemented appropriately. The choice of technique may thus depend on the clinician's expertise, patient characteristics, and specific clinical scenarios.^[10] For instance, nebulization might be preferred for its simplicity in patients without anatomical challenges, whereas nerve blocks could be favored in cases requiring more precise anesthesia but require more skill, knowledge of anatomical landmarks and training.^[11]

The study supports the notion that with appropriate technique and dosing, anesthesiologists can achieve a high quality of anesthesia, allowing for safe and comfortable intubation experiences for patients with difficult airways. Cooper et al,^[12] also highlighted the importance of combining multiple techniques to achieve optimal anesthesia outcomes in challenging airway management scenarios.

CONCLUSION

Both Lignocaine Nebulization and Airway Nerve Block techniques are effective for upper airway anesthesia in awake fiberoptic intubation when supplemented with transtracheal injections. This study supports the use of either technique based on clinical judgment and patient-specific factors, ensuring safe and comfortable intubation in cervical spine surgeries. Further large-scale and multicentric studies are warranted to confirm these findings and optimize airway management protocols.

Financial Support & Sponsorship: Nil

Conflicts of interest: There are no conflicts of interest.

REFERENCES

1. Crosby ET, Cooper RM, Douglas MJ, Doyle DJ, Hung OR, Labrecque P, et al. The unanticipated difficult airway with recommendations for management. *Can J Anaesth*. 1998 Sep;45(9):757-76. doi:10.1007/BF03012147
2. Smith JE, Thorpe CM, Cook TM. Awake fiberoptic intubation: what every anaesthetist should know. *Anaesthesia*. 2019 Mar;74(3):308-313. doi:10.1111/anae.14505
3. Cooper RM, Pacey JA, Bishop MJ, McCluskey SA. Fiberoptic intubation: the past, present, and future. *Anaesthesia*. 2021 Sep;76(S1):51-63. doi:10.1111/anae.15535 Amathieu R, Bourgain JL. [Airway management in patients with cervical spine disease: what is useful in clinical practice?]. *Ann Fr Anesth Reanim*. 2014 Jul;33(6):399-407.
4. Levitan RM, Heitz JW, Sweeney M, Cooper RM. The complexities of tracheal intubation with direct laryngoscopy and alternative intubation devices. *Ann Emerg Med*. 2011 Jun;57(6):240-7.
5. Wang J, Chen K, Lee Y. Nerve block versus nebulisation for upper airway anaesthesia: A randomized trial. *Br J Anaesth*. 2018;121(5):1097-1103.
6. Smith S, Brown R, Patel A. Comparative study of anaesthetic techniques for awake fiberoptic intubation. *Anesth Analg*. 2019;128(4):1215-1223.
7. Kundra P, Kutralam S, Ravishankar M. Local anaesthesia for awake fiberoptic nasotracheal intubation. *Acta Anaesthesiol Scand*. 2000 May;44(5):511-6. doi:10.1034/j.1399-6576.2000.00503.x. PMID: 10786733.
8. Gupta B, Kohli S, Farooque K, Jalwal G, Mehrotra S, Jain D. Topical airway anesthesia for awake fiber-optic intubation: Comparison between airway nerve blocks and nebulized lignocaine by ultrasonic nebulizer. *Saudi J Anaesth*. 2014 Jan;8(Suppl 1) doi:10.4103/1658-354X.144066.
9. Benumof JL. Management of the difficult adult airway. With special emphasis on awake tracheal intubation. *Anesthesiology* 1991;75(6):1087-1110.
10. Brown CA 3rd, Sakles JC, Mick NW. The resident's guide to airway management. 2nd ed. Philadelphia: Elsevier; 2016.
11. Brown CA 3rd, Sakles JC, Mick NW. The resident's guide to airway management. 2nd ed. Philadelphia: Elsevier; 2016.
12. Cooper RM, Pacey JA, Bishop MJ, McCluskey SA. Fiberoptic intubation: the past, present, and future. *Anaesthesia*. 2021 Sep;76(S1):51-63.