

## A UNIQUE CASE OF NEAR MISS IN A RUPTURED RUDIMENTARY HORN ECTOPIC PREGNANCY

Rumi Bhattacharjee<sup>1</sup>, Devanshi Shah<sup>1</sup>, Jaimini Kapadia<sup>1</sup>, Sangita Pandey<sup>1</sup>, Rashmita Pal<sup>1</sup>, Sheetal Shahu<sup>1</sup>, Rakesh Khimani<sup>1</sup>

<sup>1</sup>Department of Obstetrics and Gynaecology, Affiliation: Pramukhswami medical college, Bhaikaka university, Karamsad, Anand, Gujarat, India

Received : 04/05/2024  
Received in revised form : 18/06/2024  
Accepted : 02/07/2024

**Keywords:**  
Ectopic pregnancy, rudimentary horn, hemoperitoneum, laparotomy, rupture.

Corresponding Author:  
**Dr. Rumi Bhattacharjee,**  
Email: rumigynae@gmail.com

DOI: 10.47009/jamp.2024.6.4.1

Source of Support: Nil,  
Conflict of Interest: None declared

Int J Acad Med Pharm  
2024; 6 (4); 1-4



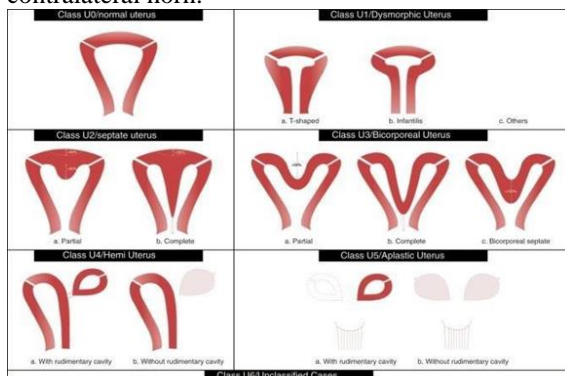
### Abstract

**Background:** Conception in uterus with mullerian anomalies is rare and has potential adverse outcomes. The high complication rates noted in these cases is related to poorly developed musculature and space constraint encountered by the developing foetus. We report a case of a 35 years old multigravida who presented to our trauma centre with a report suggestive of ruptured tubal ectopic pregnancy and massive hemoperitoneum but subsequently diagnosed with ruptured rudimentary horn pregnancy during an emergency laparotomy. The patient was successfully managed by a multidisciplinary team and timely intervention.

## INTRODUCTION

An inherited anomaly in the mullerian duct system is detected in 3.5% of the normal fertile population.<sup>[1]</sup> Classification of mullerian anomalies have been described by the American fertility society and recently by the ESHRE/ESSE system. According to the ESHRE guidelines, classification of the present case can be categorized as U4A.<sup>[2]</sup>

According to ESHRE 2013 guidelines Class U4 = hemi uterus, includes all cases of unilaterally formed uterus class U4a or hemi uterus with a rudimentary (functional) cavity characterized by the presence of a communicating or noncommunicating functional contralateral horn.



**Figure 1: ESHRE/ESGE classification of uterine anomalies: schematic representation (Class U2: internal indentation >50% of the uterine wall thickness and external contour straight or with indentation <50%, Class U3: external indentation >50% of the uterine wall thickness, Class U3b: width of the fundal indentation at the midline >150% of the uterine wall thickness).**

The typical symptoms may not manifest in most patients and the condition may evade diagnosis until a catastrophe eventualizes. Morbidity and mortality in rudimentary horn pregnancies exceed that of other ectopic due to delay in diagnosis and accelerated hemorrhage.

## CASE REPORT

**Chief complain:** A 35 years old female with 4 months amenorrhea presented to the emergency department of our hospital referred from a nearby CHC with chief complains of abdominal pain since 1 day without vaginal bleeding. Patient had an unconfirmed pregnancy and the last menstrual date escaped her memory. She developed acute abdominal pain of a non-insidious nature in the last 24 hours which was associated with abdominal distension and sudden onset of weakness and dizziness. The patient visited a local hospital where the results of a quick pelvic ultrasound concluded a live ruptured tubal ectopic pregnancy with a large hemoperitoneum. As she exhibited signs of hypovolemic shock, she was referred to a higher center. Patient visited a local CHC before she was received at our trauma center.

**History of the patient:** Patient was a multipara with previous 4 full term vaginal deliveries which were eventless save a history of two packed red cell (PCV) transfusions during her 3rd delivery, 3 years ago due to excessive intrapartum blood loss. A history of appendectomy performed 15 years ago was also elicited. Her last child birth was a year ago and she was still in her lactational amenorrhea when she conceived unwittingly. The conception remained

unnoticed and she did not avail any antenatal care until the current situation eventuated.

**Physical and laboratory examination:** The patient presented with severe abdominal pain and hemodynamic instability. Abdominal examination displayed distension with a dull note on percussion, fullness in flanks and rebound tenderness. Her shock index was 1.2 with a rapid, thready pulse, tachycardia of 126 bpm and blood pressure of 110/60 mmhg. Severe pallor was noted. Per vaginal examination exhibited a 6-8 weeks size uterus deviated towards left with right forniceal tenderness.

Blood analysis revealed a hemoglobin of 3.1gm %, total leukocyte counts of 14,100/ml, platelet counts of 2,23000/ml and hematocrit of 10%.

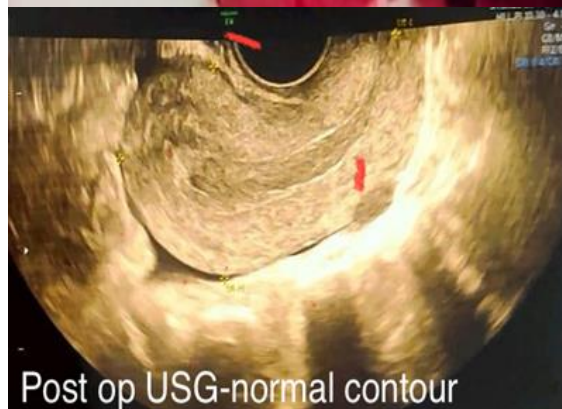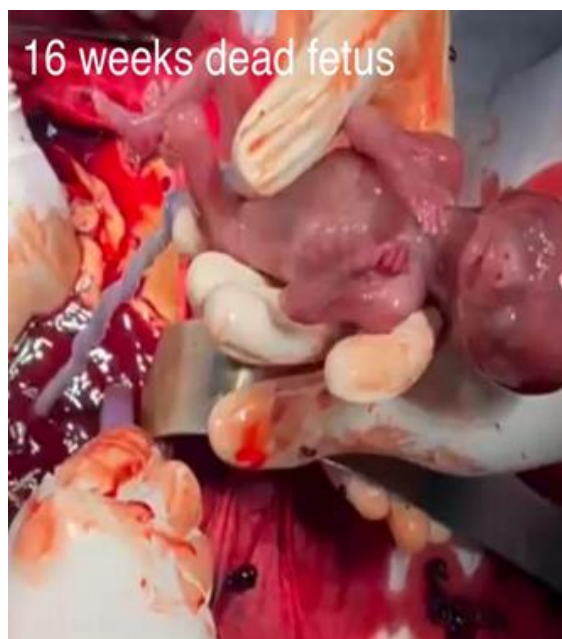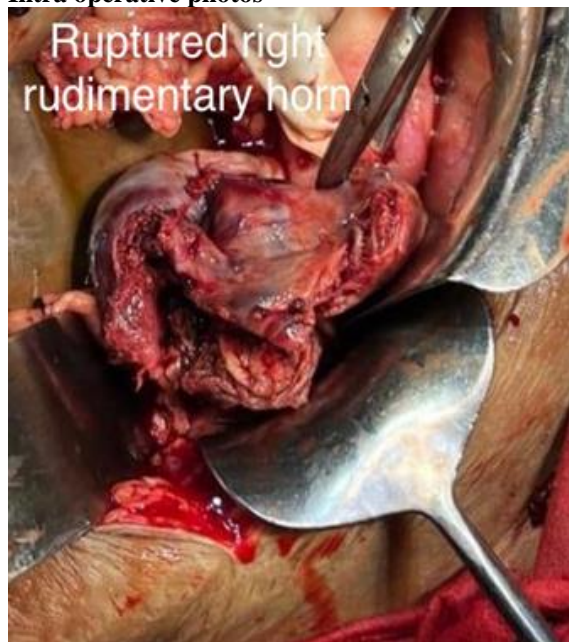
Se. Beta HCG: 33570 IU/l Se. creatinine: 1.85

PT: 12.6 sec

APTT: 21.50 sec

INR: 1.11

#### Intra operative photos



**Treatment and final diagnosis:** An emergency laparotomy was arranged which established a massive hemoperitoneum of around 1500 ml and ruptured non communicating right horn of unicornuate uterus. The dead fetus which was around 16 weeks size and weighed 110grams was extracted from the peritoneal cavity. Around 230 grams of placenta, clots and old endometriotic tissues presented as a dense pelvic mass adherent to bowels and ovary on the right side. Ureter was also encased in the mass. After adhesiolysis and ureterolysis, the pelvic mass containing the placenta was removed along with right sided fallopian tube and ovary which were all adherent and formed an amalgamated mass. The right ruptured horn of the uterus was excised and the defect was repaired. Left sided salpingectomy was done as reproductive objectives were already fulfilled. Patient received 4 units of PCV along with IV fluids during the surgery to compensate the drastic blood loss. Post operatively patient was shifted to ICU with unreversed intubation, and required 3 days of ventilatory support and a 5th unit of PCV transfusion on the 3rd post operative day (POD). Patient was shifted to ward on 4th POD and discharged on 10th day in a stable condition. A post-surgery ultrasound scan two weeks later unveiled a normal uterus.

Histopathological report confirmed ectopic gestation and serial beta HCG (human chorionic gonadotrophin) levels dropped satisfactorily.

## DISCUSSION

Pregnancy in a rudimentary horn of the uterus is a rare occurrence, and is seen in 1:76,000 to 1:1,06,000 pregnancies.<sup>[3]</sup> Congenital Mullerian anomalies occur as a result of defect in formation, fusion or resorption of the mullerian ducts. Formation of unicornuate uterus with a non-communicating rudimentary horn is due to the failure of development of the mullerian duct on one side with incomplete fusion on the contralateral side. Transperitoneal migration of spermatozoon/fertilized ovum to the non-communicating rudimentary horn is the theory put forward in favour of implantation in these cases.<sup>[4]</sup> Several studies have confirmed that around 84% of unicornuate uteri are endowed with a contralateral rudimentary horn.<sup>[5]</sup> The presence of menstrual endometrium in a rudimentary horn has been estimated to be around 82% in a literature review.<sup>[6]</sup> Adolescent and young females can present with severe dysmenorrhea, hematometra or endometriosis and can actually provide a window of opportunity in diagnosing the condition much earlier. The association of renal anomalies is estimated to be around 10%.<sup>[7]</sup> The likelihood of obstetric complications like infertility, abortion, preterm labour, PROM are compounded if she conceives. The most feared complication is a rupture which is more than often cataclysmic. Rupture can occur anytime between 5 to 35 weeks with a preponderance prior to 20 weeks.<sup>[8]</sup> Rare case of a term delivery have however been quoted in literature.<sup>[5]</sup> In spite of technical advances in the field of radio imaging, the sensitivity of ultrasound in diagnosing these cases remain restricted to 26% and lesser in advanced gestation. The advent of 3D ultrasound and colour doppler has been of much assistance in this regard.<sup>[3,9,10]</sup> MRI has a definitive role among the diagnostic modalities and Tsafir A et al has described a set of criteria for diagnosing rudimentary horn ectopic pregnancy which includes.

- 1 pseudo pattern of asymmetrical Hemi uterus
- 2 absent visual continuity between cervical canal and lumen of pregnant horn
- 3 the presence of myometrial tissue surrounding the gestational sac.<sup>[11]</sup>

Lopamudra et al described a 20 weeks live rudimentary horn pregnancy with partial rupture which was managed surgically by resecting the horn along with the foetus.<sup>[1]</sup> Another case of a full-term foetus in an unruptured horn delivered by caesarean-section has been reported by Shin JW.<sup>[12]</sup>

In a case series by Mamta Dagar, Mala Shrivastava, Indrani Ganguly et al, 2 of the 3 cases of cornual ectopic pregnancies needed surgical intervention even with early detection at less than 10 weeks of pregnancy.<sup>[13]</sup>

In another case report, Kaveh M, Mehdizadeh Kashi A reported an ectopic pregnancy in a non-communicating rudimentary horn of a unicornuate uterus that ruptured at 14 weeks and was managed by emergency laparotomy; further supporting the fact that cornual pregnancies tend to rupture when gestation advances up to second trimester.<sup>[3]</sup> Management options are not as diverse as for other ectopic pregnancies and a surgical intervention becomes necessary sooner or later. The choice between laparotomy or a laparoscopic approach depends upon the condition of the patient and the availability of experts and facilities. Such cases should be managed in a tertiary care centre or an institute with blood bank facilities and intensive care unit. Excision of a non-gravid functional non communicating horn can prevent future catastrophic events.

## CONCLUSION

Primary treatment of a rudimentary horn pregnancy is surgical excision even in unruptured cases; in the event of a rupture, the case should be dealt with by an experienced team of obstetricians and anaesthetists, supported by the department of transfusion medicine.

## REFERENCES

1. Jena L, Satapathy RN, Swain S, Mahapatra PC. Ruptured rudimentary horn pregnancy of unicornuate uterus: a case report. *Int J Reprod Contracept Obstet Gynecol* 2015; 4:259-62.
2. Grimbizis GF, Gordts S, Di Spiezio Sardo A, Brucker S, De Angelis C, Gergolet M, Li TC, Tanos V, Brölmann H, Gianaroli L, Campo R. The ESHRE/ESGE consensus on the classification of female genital tract congenital anomalies. *Human reproduction*. 2013 Aug 1;28(8):2032-44.
3. Kaveh M, Mehdizadeh Kashi A, Sadegi K, Forghani F. Pregnancy in Non- Communicating Rudimentary Horn of A Unicornuate Uterus. *Int J Fertil Steril*. 2018 Jan;11(4):318-320. doi: 10.22074/ijfs.2018.5022. Epub 2017 Oct 12. PMID:29043710; PMCID: PMC5641466.
4. Scholtz M. A full-time pregnancy in a rudimentary horn of the uterus. *Br J Obstet Gynaecol*. 1951; 58:2936.
5. Li X, Peng P, Liu X, Chen W, Liu J, Yang J, Bian X. The pregnancy outcomes of patients with rudimentary uterine horn: A 30-year experience. *PLoS One*. 2019 Jan 25;14(1):e0210788. doi: 10.1371/journal.pone.0210788. PMID: 30682068; PMCID: PMC6347212.
6. Jayasinghe Y, Rane A, Stalewski H, Grover S. The presentation and early diagnosis of the rudimentary uterine horn. *Obstet Gynecol*. 2005 Jun;105(6):1456-67. doi: 10.1097/01.AOG.0000161321.94364.56. PMID: 15932844.
7. G. Daskalakis, A. Pilalis, K. Lykeridou, and A. Antsaklis, "Rupture of noncommunicating rudimentary uterine horn pregnancy," *Obstetrics & Gynecology*, vol. 100, 5, Part 2, pp. 1108-1110, 2002.
8. O'leary JL, O'leary JA. Rudimentary horn pregnancy. *Obstet Gynaecol*. 1963; 22:371-4
9. Claudia Blancafort, Betlem G. Diagnosis and laparoscopic management of a rudimentary horn pregnancy: role of three-dimensional ultrasound. *J. Clin. Ultrasound*,45 (2) 2017, pp. 112-115, 10.1002/jcu.22393.
10. A. Yassin, S. Munaza. Tale of rudimentary horn pregnancy: case reports and literature review. *J. Maternal. Fetal. Neonatal. Med*.32 (4) 2019, pp. 671-676. 10.1080/14767058.2017.1387533.

11. Tsafirir A, Rojansky N, Sela HY, Gomori JM, Nadjari M. Rudimentary horn pregnancy: first-trimester prerupture sonographic diagnosis and confirmation by magnetic resonance imaging. *J Ultrasound Med.* 2005;24(2):219-23.
12. Shin JW, Kim HJ. Case of live birth in a non-communicating rudimentary horn pregnancy. *J Obstet Gynaecol Res.* 2005; 31(4): 329-331
13. Dagar M, Srivastava M, Ganguli I, Bhardwaj P, Sharma N, Chawla D. Interstitial and Cornual Ectopic Pregnancy: Conservative Surgical and Medical Management. *J Obstet Gynaecol India.* 2018 Dec;68(6):471-476. doi: 10.1007/s13224-017-1078-0. Epub 2017 Nov 28. PMID: 30416274; PMCID: PMC6207538.