

AUTOIMMUNE HEPATITIS – EPIDEMIOLOGICAL, CLINICAL, SEROLOGICAL AND HISTOPATHOLOGICAL CORRELATION IN A TERTIARY CARE HOSPITAL

Sairaman H¹, Selvasekaran R², Shirish N.D³, Vigneshwaran M⁴, Vijula A⁵

Received : 13/12/2023
Received in revised form : 09/02/2024
Accepted : 28/02/2024

Keywords:

Autoimmune liver disease, Overlaps, Hepatitis, Liver biopsy, Chronic liver disease.

Corresponding Author:

Dr. Sairaman H,

Email: hsr1993mdu@gmail.com.

DOI: 10.47009/jamp.2024.6.2.8

Source of Support: Nil,
Conflict of Interest: None declared

Int J Acad Med Pharm
2024; 6 (2); 39-42



¹Senior Resident, Department of Medical Gastroenterology, Government Thoothukudi Medical College, Tamilnadu, India.

²Associate Professor, Department of Medical Gastroenterology, Government Thoothukudi Medical College, Tamilnadu, India.

³Assistant Professor, Department of Medical Gastroenterology, Government Thoothukudi Medical College, Tamilnadu, India.

⁴Senior Resident, Department of Medical Gastroenterology, Government Thoothukudi Medical College, Tamilnadu, India.

⁵Senior Resident, Department of Medical Gastroenterology, Government Thoothukudi Medical College, Tamilnadu, India.

Abstract

Background: Autoimmune hepatitis (AIH) causes immune-mediated liver damage, leading to liver cirrhosis if left untreated. It presents with various clinical and laboratory abnormalities, and a liver biopsy is crucial for diagnosis and prognosis. **Aim:** To compare clinical, histological & laboratory parameters in patients of Chronic liver disease (CLD) with autoimmune etiology. **Material and Methods:** This observational study was conducted in the Department of Medical Gastroenterology, Government Thoothukudi Medical College Hospital, with a diagnosis of chronic liver disease based on clinical features and laboratory investigations. APRI and FIB 4 were calculated using laboratory values, an autoimmune hepatitis panel, and a liver biopsy was performed in all patients. **Results:** Males had a peak incidence of 11-20 years, while females had a peak incidence of 21-30 years. The clinical presentations included abdominal pain in males and UGI bleeding in females. Laboratory investigations revealed anaemia, thrombocytopenia, and an increased international normalised ratio (INR). ANA was the most commonly detected antibody in 78% of the cases. A liver biopsy showed features of autoimmune liver disease in all patients. The most common histopathological finding in Type I AIH was lymphoplasmacytic infiltration (75%). In Type II AIH, lymphoplasmacytic infiltration was observed in 100% of the cases. **Conclusion:** A high index of suspicion for autoimmune hepatitis should be considered when evaluating cases of hepatitis. A varied spectrum of presentations and overlaps is common. Liver biopsy can be used to assess the severity of the disease, along with serology.

INTRODUCTION

Autoimmune hepatitis causes immune-mediated liver damage and eventually leads to cirrhosis. If left untreated.^[1] Chronic infectious hepatitis, a prevalent cause of cirrhosis in Asian nations, as well as metabolism-associated steatosis and liver disease, should be ruled out before AIH is diagnosed.^[2] It has the clinical presentation varies from asymptomatic to non-specific clinical and laboratory abnormalities to acute hepatitis or chronic liver failure. Liver biopsy is an important tool not only for diagnosis, but also for prognosis and treatment response assessment.^[2,3] The precise

pathophysiological mechanism of AIH is less known and yet to be explored. The most widely accepted concept is that AIH develops in genetically susceptible individuals who are exposed to environmental triggers.^[4] As a result of complex interplay, autoimmune disease is maintained through molecular mimicry which is aided by the loss of regulatory T-cell control.

Triggers included drugs, viral antigens (hepatitis A, B, and C), and herbal compounds. The diagnostic criteria included clinical profile, histopathology scoring, and serology for serum ANA, smooth muscle antibody (ASMA), anti-LKM1, and serum

IgG levels. Anti-actin antibodies, anti-soluble liver antigen (SLA), pANCA, anti-liver cytosol 1 and antibodies to LKM-3 or liver pancreas antigen are the extended serological panels that may be needed for the diagnosis of AIH. AIH can present with cholestatic symptoms similar to primary sclerosing cholangitis (PSC) or primary biliary cirrhosis (PBC), or can overlap with these diseases, AIH can overlap with Wilson's disease also.^[5,6]

To compare clinical, histological & laboratory parameters in patients of CLD with autoimmune etiology.

MATERIALS AND METHODS

This observational study included 36 patients at the Department of Medical Gastroenterology, Government Thoothukudi Medical College Hospital, who were diagnosed with chronic liver disease based on clinical features and laboratory investigations for 11 months. The study was approved by the institutional ethics committee before initiation, and informed consent was obtained from all patients.

Inclusion Criteria

Patients who had evidence of chronic liver disease with positive serology for AIH and who fulfilled the criteria for diagnosing probable or definite AIH were included.

Exclusion Criteria

Patients with ethanol intake, exposure to hepatotoxic drugs, native medication, positive viral serology for hepatitis B, C, A, CMV, EBV, and HSV, and evidence for any other aetiology of chronic liver disease that does not overlap with autoimmune hepatitis were excluded.

A total of 36 patients who fulfilled the inclusion criteria were selected for this study. These patients underwent complete clinical, laboratory, and histopathological evaluations. Laboratory investigations included a complete blood count with peripheral smear, renal and liver function tests, INR, and viral serology markers for hepatitis A, B, C, and E, CMV, EBV, HSV, and USG abdomen with portal Doppler and upper GI endoscopy. APRI and FIB4 scores derived from laboratory parameters were incorporated and compared with histological findings.

Specific serological tests included ANA, AMA, ASMA, and Anti LKM-1 Ab using the newer-generation ELISA method. Liver biopsy for assessing severity and prognostication was performed in all patients, and special staining for copper and iron was performed in selected patients.

RESULTS

All 36 patients for whom we could complete the workup, including liver biopsy, were included in our study. Of the 36 patients, 14 were male and 22 were

female. Among the 36 patients, 28 had type I AIH and 8 had type II AIH.

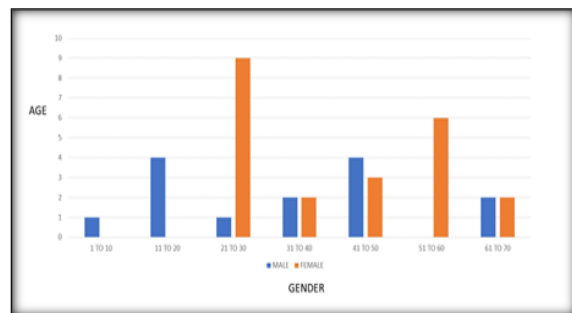


Figure 1: Age gender distribution

Our study showed bimodal age involvement in affected individuals. Males affected with AIH have a peak incidence in the age range of 11–20 years, and the second peak is from 41 to 50 years. Females affected with AIH have a peak incidence from 21 to 30 years of age and a second peak from 51 to 60 years of age.

In type I AIH, the most common clinical presentation is abdominal pain in males and UGI bleeding in females. In type II AIH, the most common clinical presentation was jaundice in males and UGI bleeding in females. Laboratory investigations revealed anaemia (70%), thrombocytopenia (90%), and an increased international normalised ratio (INR) (50%).

Transaminitis was observed in 86% of patients. IG G elevation was observed in 77% of patients with AIH. Serology for hepatitis A, B, C, and E, CMV, EBV, and HSV were negative in all cases (100%). In patients with type I AIH, ANA was the most commonly detected antibody, with high titres in 78% of type I AIH cases. This was followed by ASMA Positivity in 57% of the cases. Combined ANA and ASMA were positive in 35% of patients with type I AIH. In all patients with type II AIH Anti LKM1 was found to be positive (100%).

A liver biopsy showed features of autoimmune liver disease in all patients. The most common liver biopsy finding in Type I AIH is lymphoplasmacytic infiltration (75%), followed by interface hepatitis (68%). Hepatocyte resetting was observed in 25% of cases. Portal and periportal fibrosis are seen in 46% of type I AIH cases and are directly associated with increased oesophageal varix size, portal hypertension, and higher APRI and FIB 4 score.

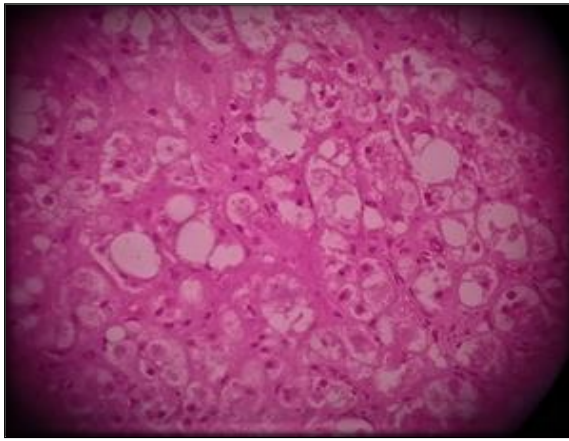


Figure 2: HPE figure showing hepatocyte Rosetting & Ballooning

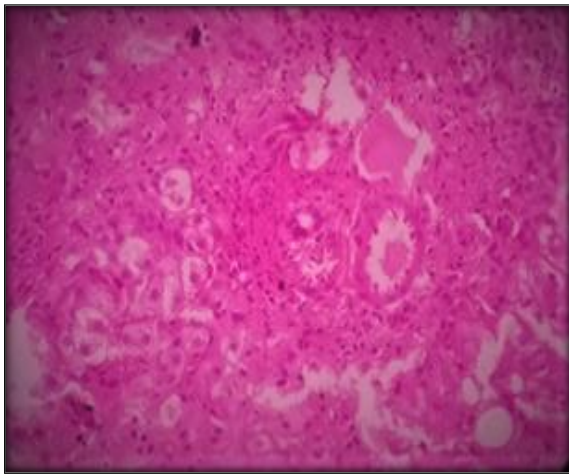


Figure 3: HPE figure showing interface hepatitis

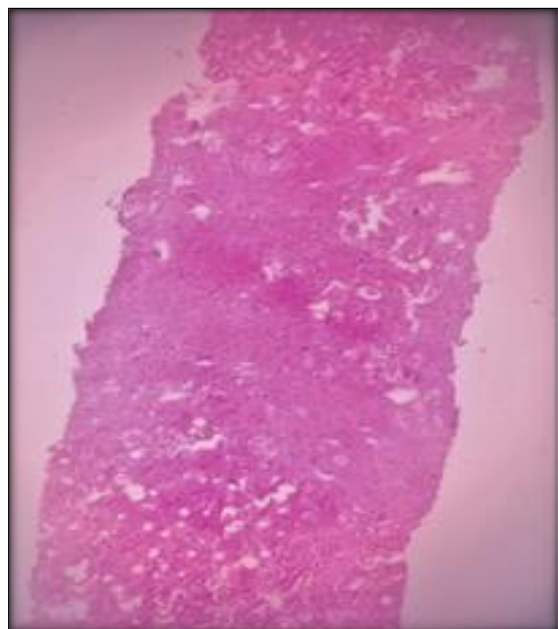


Figure 4: HPE figure showing diffuse lymphoplasmacytic infiltrates

Three patients with type 1 AIH were found to have Budd-Chiari syndrome, and the most common histopathological finding was portal triaditis and

lobulitis (100%). Two patients with type 1 AIH were found to have stainable copper in their liver tissue and were subsequently diagnosed with Wilson disease. In patients with overlap, serum IgG was markedly elevated, and in patients with UGI bleeding and portal and periportal fibrosis, serum IgG levels were within the normal range.

The most common liver biopsy finding in type II AIH was lymphoplasmacytic infiltration in 100% of cases, interface hepatitis in only 37% of cases, and hepatocyte resetting in one case. Bile ductular reactions (neutrophilic cholangitis) were observed in 25% of the patients. One patient with type II AIH had PSC overlap and one patient with type II AIH had PBC overlap. Bile duct reactions are commonly observed in patients with overlap. In patients with overlap, serum IgG was found to be markedly elevated, and in patients with portal and periportal fibrosis, serum IgG levels were within the normal range.

DISCUSSION

Autoimmune hepatitis (AIH), primary sclerosing cholangitis (PSC), and primary biliary cirrhosis (PBC) comprise the spectrum of autoimmune liver diseases. Immune-mediated liver injury leads to varied clinical presentations in this setting, ranging from an asymptomatic presentation to fulminant hepatic failure.¹ Common triggers include infection, drugs, and toxins. Human leukocyte antigen (HLA) haplotypes are more susceptible to the development of autoimmune hepatitis. Susceptible alleles are located on the short arm of chromosome 6,⁶ specifically within the DRB-1 region. Nitrofurantoin and minocycline are well-documented culprits of drug-induced autoimmune hepatitis. Tumour necrosis factor-alpha (TNF- α) drugs have recently been linked to autoimmune hepatitis.

Conditions sharing features of two different autoimmune liver diseases are grouped under the entity called 'Overlap Syndromes'.³ However, there is no current consensus regarding the specific diagnostic criteria for overlap. Type I autoimmune hepatitis has anti-nuclear antibodies (ANA) and/or anti-smooth muscle antibodies (ASMA), whereas type II autoimmune hepatitis has anti-liver kidney microsomal type-1 (anti-LKM-1) antibodies.⁴ In a genetically determined individual, environmental triggers may lead to the development of neoautoantigens, which are recognised by non-polarised T cells (through antigen-presenting cells), resulting in cellular activation.⁵ Once activated, intrahepatic T-helper cells promote the differentiation of cytotoxic T cells, Th,¹⁷ cells, and/or the differentiation of B cells into plasma cells that produce immunoglobulins, and together with the activation of monocytes, contribute to the loss of self-tolerance and increase in chronic inflammatory tissue damage.⁶

Liver histology is important for confirming the diagnosis of autoimmune hepatitis as it plays a major role in scoring systems. Liver biopsy may even reveal diagnoses other than autoimmune hepatitis.^[7] Liver biopsy may identify cases with overlapping features within the spectrum of autoimmune liver diseases and highlight possible concurrent diseases, particularly the metabolism-related spectrum of liver diseases. Histology is currently the best standard for grading necroinflammatory injury, and evaluating the extent of fibrosis (staging) and architectural remodelling in autoimmune hepatitis liver biopsy plays an important role in patient management in autoimmune hepatitis, as it dictates treatment decisions at diagnosis and assessment of disease remission or progression during treatment.⁸ Liver histology at presentation provides prognostic information for the subsequent development of progressive fibrosis/cirrhosis and the risk of liver-related death or transplantation and may yield predictive information regarding response to treatment.^[9,10]

CONCLUSION

Autoimmune hepatitis and its overlap syndromes should be considered important differentials when evaluating patients with altered LFT and chronic liver disease. The diagnostic criteria are simplified and can be easily applied to the general population worldwide to arrive at an etiological diagnosis. Patients who are not adequately treated develop cirrhosis and subsequently die of liver failure two years after diagnosis. Once the diagnosis is established, the initiation of steroids and

azathioprine will have a significant impact on controlling disease progression and reducing mortality.

REFERENCES

1. Genetic and Rare Diseases Information Centre (GARD). Autoimmune hepatitis. Gaithersburg (US): Department of Health & Human Services, National Institute of Health.
2. Trivedi PJ, Hirschfield GM. Review article: overlap syndromes and autoimmune liver disease. *Aliment Pharmacol Ther* 2012; 36:517–33. <https://doi.org/10.1111/j.1365-2036.2012.05223.x>.
3. Hübscher SG. Role of liver biopsy in autoimmune liver disease. *Diagn Histopathol (Oxf)* 2014; 20:109–18. <https://doi.org/10.1016/j.mpdhp.2014.01.009>.
4. Lohse AW, Mieli-Vergani G. Autoimmune hepatitis. *J Hepatol* 2011; 55:171–82. <https://doi.org/10.1016/j.jhep.2010.12.012>.
5. Boberg KM, Lohse AW, Hennes EM, Dienes HP, Heathcote JE, Chapman RW, et al. Assessment of 479 patients with autoimmune liver diseases according to the IAIHG scoring system for autoimmune hepatitis does not support the contention of overlap syndromes as separate diagnostic entities: 1532. *Hepatology* 2009; 50:1009A. https://journals.lww.com/hep/citation/2009/10004/assessment_of_479_patients_with_autoimmune_liver.1532.aspx.
6. Van Gerven NM, De Boer YS, Mulder CJ, Van Nieuwkerk CM, Bouma G. Auto immune hepatitis. *World J Gastroenterol* 2016; 22:4651–61. <https://doi.org/10.3748/wjg.v22.i19.4651>.
7. Guindi M. Histology of Autoimmune Hepatitis and its Variants. *Clin Liver Dis* 2010; 14:577–90. <https://doi.org/10.1016/j.cld.2010.07.003>.
8. Schiano TD, Fiel MI. To B(iopsy) or not to B(iopsy). *Clin Gastroenterol Hepatol* 2011; 9:3–4. <https://doi.org/10.1016/j.cgh.2010.09.027>.
9. Krawitt EL. Autoimmune hepatitis. *N Engl J Med* 2006; 35:54–66. <https://doi.org/10.1056/NEJMra050408>.
10. Washington MK, Manns MP. Autoimmune hepatitis; in Burt AD, Portmann B, Ferrel L (eds): *MacSween's Pathology of the Liver*. Edinburgh, Churchill Livingstone, 2012, pp 467-490.