

THE CLINICAL AND RADIOLOGICAL OUTCOME OF FOREARM FRACTURES TREATED BY INTRAMEDULLARY TENS NAILING IN A TERTIARY CARE TEACHING INSTITUTE IN KERALA

Afsal Rasheed¹, Jacob P J²¹Senior Resident, Department of Orthopaedics, Govt Medical College Thrissur, Kerala, India.²Additional Professor, Department of Orthopaedics, Govt. Medical College Thrissur, Kerala, India.

Received : 05/01/2024
 Received in revised form : 21/02/2024
 Accepted : 03/03/2024

Keywords:

Forearm fracture, tens nail, elastic nailing, prospective study, clinical and radiological outcome.

Corresponding Author:

Dr. Afsal Rasheed,

Email: afsalrasheed1992@gmail.com.

DOI: 10.47009/jamp.2024.6.2.6

Source of Support: Nil,

Conflict of Interest: None declared

Int J Acad Med Pharm

2024; 6 (2); 29-33

**Abstract**

Background: Diaphyseal forearm fractures are common in the pediatric population. Conventionally conservative management with closed reduction plaster cast has been the treatment. Intramedullary nailing has gained popularity in recent times due to its ability to prevent loss of reduction, and anatomical reduction fixation. **Objectives:** The aim of our study is to evaluate the functional and radiological outcome of both bone forearm fractures treated with closed reduction and internal fixation with Titanium Elastic nailing. Various factors affecting the clinical and radiological outcome have also been studied. **Material and Methods:** A Prospective study of cases of forearm fractures meeting the inclusion criteria who were admitted in Govt. Medical College Thrissur between 30-03-2021 and 31-01-2022 was carried out. Fractures were classified according to AO classification and anatomical reduction was attempted through closed reduction and internal fixation. After a minimum follow up period of 6 months, the functional and radiological outcomes were standardized using Price et al criteria system. **Results:** A series of 56 patients with forearm fractures were studied comprising of 40 males and 16 females. The largest contribution came from age group of 8 to 13 years (78.5%). Fall was the commonest mode of injury (69.6%). Two cases were found to develop postoperative infection and five cases developed mild degrees of loss of forearm rotation. Post operatively excellent scores were achieved in 51 cases (91.07%) and good results in three cases. Average time of union of fracture was 10.75 weeks. **Conclusions:** This single centre with small to medium size population series demonstrated good to excellent results in majority of patients after closed reduction and internal fixation of forearm fractures, with outcomes and complications comparable to other studies in literature. This study supports the finding that closed reduction and internal fixation of forearm with TENS nailing results in improved functional and radiological outcome.

INTRODUCTION

Forearm fractures are among the most common fractures in the pediatric age group, accounting for around 40% of all fractures.^[1] The Most common injury mechanism is a fall on an outstretched hand (86%), during which indirect force is transmitted. Depending on the position of the forearm (pronation or supination), the angle of the fracture can be volar or dorsal apex. Fractures in children can vary from plastic deformation and greenstick to complete fractures. Conventionally, these fractures have been treated with closed reduction and plastering. However, these came with consequences, including loss of reduction, malunion, limited range of

movements (rotations), and cosmetic deformity. Due to these reasons, reductions and intramedullary stabilization with Titanium elastic nailing (TENS) have gained popularity. The purpose of the study was to evaluate the clinical and radiological outcomes of diaphyseal forearm fractures treated with TENS nailing in children.

MATERIALS AND METHODS

This was a prospective study conducted in the Department of Orthopaedics at Govt. Medical College, Thrissur. It included all pediatric (age 8-18) diaphyseal forearm fractures treated with closed reduction and internal fixation with TENS between

01-12-2020 and 01-12-2021. All patients with unilateral closed diaphyseal forearm fracture with AO fracture classification types 22-A3 and 22-B3 and between ages 8-18 years were included in the study. Patients with bilateral fractures, open fractures, complex forearm fractures (Monteggia, Galeazzi, intraarticular elbow or wrist fractures), pathological fractures, history of trauma of the same upper extremity causing functional deficit and diseases that significantly affect the general condition of the patient or significantly impaired ability to cooperate for any reason were excluded. Demographic data was collected using a pre-tested questionnaire. This included personal data and data about injury. Serial radiographs were assessed. Functional and radiological outcome scoring was done at intervals.

Surgical technique

The patient was placed supine with the arm on a radiolucent side table. Under sterile aseptic precautions, under general anesthesia / regional anesthesia, the tourniquet was applied to the fractured limb at the level of the arm with adequate padding, and parts were painted and draped. An incision of size 1 cm was made over the distal radius above the physical line on the lateral aspect. Entry is made into the medullary cavity using bone awl over the lateral aspect of the distal radius above the physis. In another method, some surgeons prefer to make an incision over the dorsal aspect of the lister's tubercle. The entry is slightly lateral to the lister's tubercle after retracting the extensor pollicis longus. Depending on the diameter of the medullary cavity, a titanium nail of approximate size was chosen. A 30° angulation was given to the proximal tip of the nail. Then, the nail with the bent tip was introduced into the medullary cavity, where the entry was made in the distal radius. A 180° rotation was given to the nail with the T-handle, and the nail tip was brought along the axis of the medullary canal. Under c-arm guidance, the nail was advanced into the medullary canal twisting motions and then passed across the fracture site into the proximal fragment till the nail tip reached the radial head. An incision was placed over the posterolateral olecranon for the ulna, avoiding physics. Entry was made a little lateral and distal to the olecranon apophysis using a bone awl. Similar to the radius, titanium nails of approximate size were measured and similarly introduced into the medullary cavity from the proximal fragment to the distal fragment. The reduction of fracture fragments was checked under a c-arm image intensifier. If it was found to be satisfactory, protruding ends of the nail were initially bent at about 90° and were cut 1 cm away from the bone. Nail size should be filling 60-70% of the medullary cavity. If closed reduction cannot be achieved, a small incision was made over the fracture site, and the fracture was reduced, and fixation was done with a titanium nail. A wound wash was given, and skin incisions were sutured with 3-0 monofilament nonabsorbable suture.

Postoperatively, an above-elbow slab was given to encourage soft tissue healing. Parenteral antibiotics were given for three days, then oral antibiotics were changed. Active finger and elbow exercises were started at the earliest possible. Implant removal was done six months postoperatively after seeing the radiological union. The patients were followed up for a minimum period of 6 months. The subjective, objective, and radiographic findings were quantified according to Price et al.'s criteria and radiological findings.

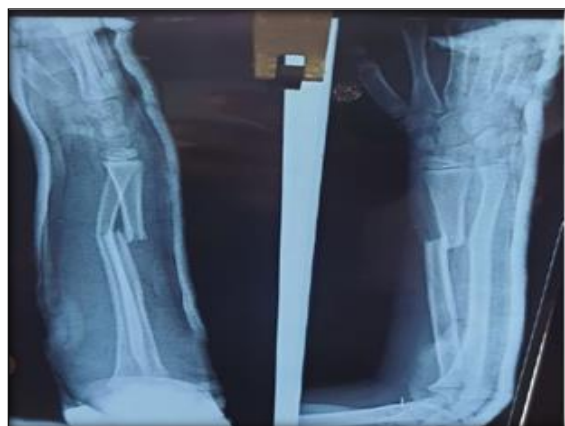

Figure 1: Pre-op x-ray showing displaced both bone forearm fracture

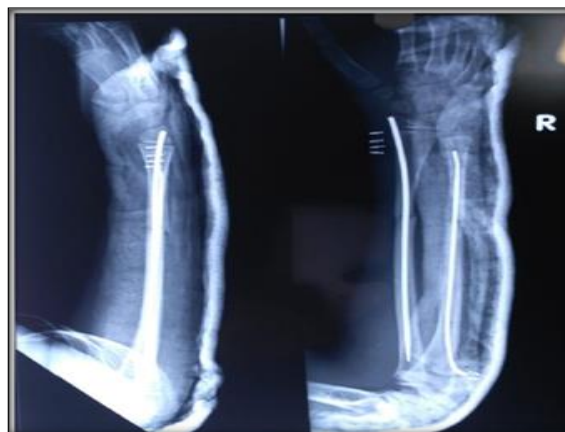

Figure 2: Post-op: TENS nailing done

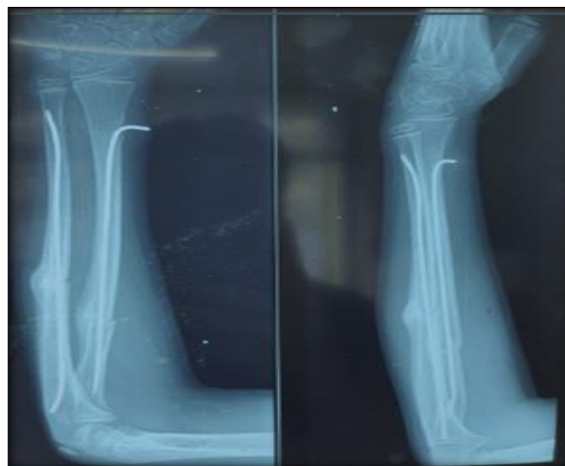

Figure 3: Post-op 4 weeks

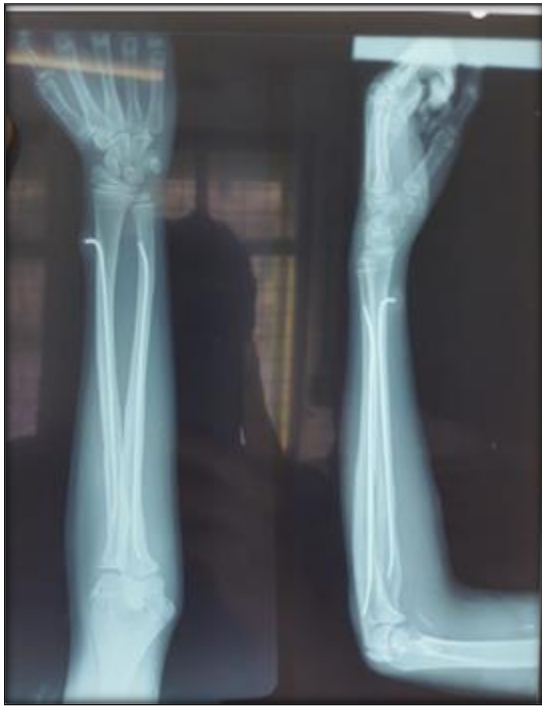

Figure 4: 3 months post-op- fracture united well. Normal ROM of wrist and elbow

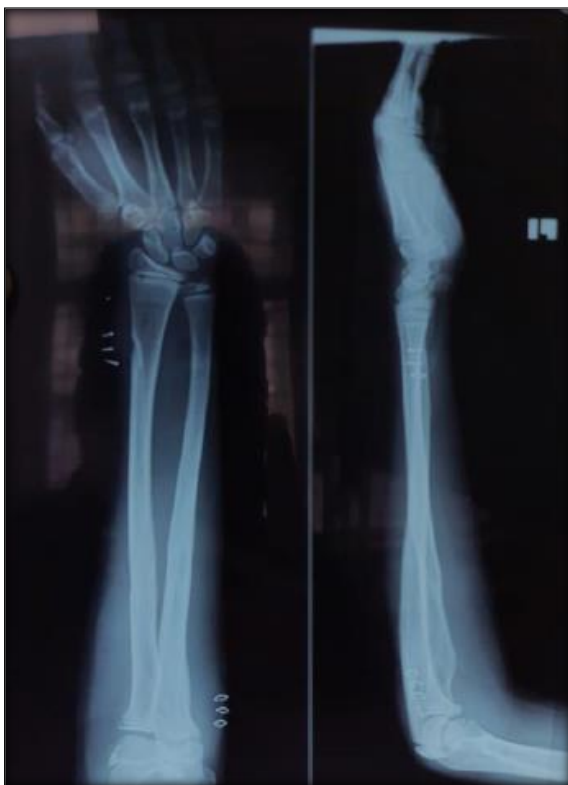

Figure 5: Post Implant removal

of the study. Informed written consent was taken. Data was entered in Excel sheets, and qualitative and quantitative analysis was done using SPSS 22.

RESULTS

The average age of the study population was 11.6 years, with a range of 8-18 years. Males were affected more (2.5:1) than females. The right side was more commonly affected, with 42 patients (75%). The most typical mode of injury was falls in 39 patients, and 17 patients had a history of road traffic accidents.

Radiological outcome was studied regarding mean time to union, which was 10.75 weeks [Table 1]. Clinical outcome in this study, 51(91%) patients had excellent results, 3(5.4% had good result, 2(3.6%) had poor results.[Table 2] Two cases with poor results had developed infection and were treated by debridement and parenteral antibiotics. One of those patients developed stiffness as well.

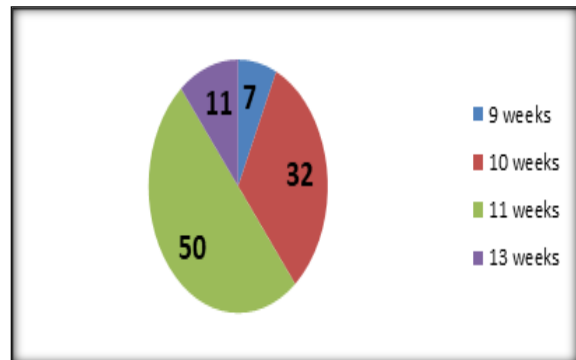


Figure 6: Fracture Union time distribution

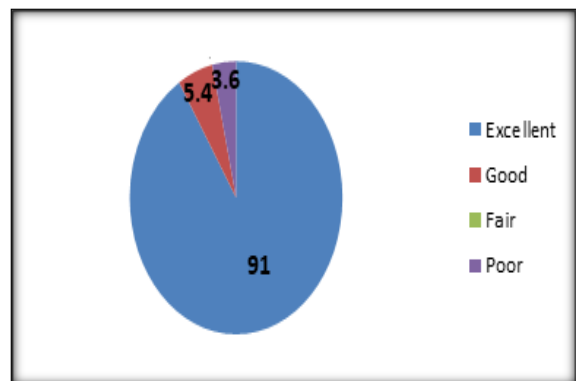


Figure 7: Distribution of Functional and radiological outcome

Institutional ethics and Institutional research board approval were obtained before the commencement

Table 1: Distribution Fracture Union time

Union time	N(56)	%
9 weeks	4	7
10 weeks	18	32
11 weeks	28	50
13 weeks	6	11

Table 2: Distribution of Functional and radiological outcome

Results	N(56)	%
Excellent	51	91
Good	3	5.4
Fair	0	0
Poor	2	3.6

DISCUSSION

Conventionally, most pediatric fractures were managed conservatively. However, there is a change in managing these fractures because of the higher complications following conservative management. These fractures tend to go for malunion due to improper reduction and re-displacement following closed reduction and casting.

A study conducted by Kay et al,^[2] concluded that children over ten years have a remarkable decrease in forearm movements due to closed reduction manoeuvres, resulting in angulation of more than 10°. Treatment of these forearm fractures through non-operative treatment had more complications than operative treatment. Surgical treatment should be considered in patients with unstable forearm fractures if acceptable alignment cannot be achieved with closed reduction manoeuvres. The remodelling potential, particularly in older children, will be limited. Hence, fractures with complete displacement are more commonly addressed by surgical treatment.

Vainionpaa et al,^[3] stated that out of 10 patients, five had restricted forearm movements with loss of functional outcome because of the soft tissue compromise, treated with plate fixation. There is a 42% rate of neurovascular complications following implant removal of plates and screws after osseous union in the forearm.

Our study grading showed no pain or complaint with strenuous work in 51 (91%) cases. In comparison, 3(5.4%) cases reported mild pain during strenuous activity. 2 cases (3.6%) developed an infection at the ulnar entry site.

Intramedullary nailing helps in early union, decreases the infection risk and synostosis and avoids long incisions required for plating and its removal but the use of Kirschner wire for fixation of these fractures intramedullary also had many disadvantages like penetration of k -wire, infection at the pin sites, restriction of movements in the involved forearm, delay in union of fractures. A titanium elastic nailing system is used to avoid these complications and to use the advantages of intramedullary fixation. They act as internal splints, providing a 3-point fixation of fractures, which helps maintain the alignment. Reduction of fracture end to end is achieved, which helps control rotational alignment and reduces motion at the fractured area, promoting external callus formation by converting shear stress into compression.

In a study of 60 patients by Amitet. Al,^[4] to evaluate clinical and radiological outcomes in paediatric bone forearm fractures using TENS, concluded

TENS is a good option because it is minimally invasive, has low complication and excellent clinical outcomes, and permits early mobilization with early return to normal activities. A study conducted by Furlan D et al,^[5,6] in unstable both-bone forearm fractures in the paediatric age group showed the advantages of intramedullary nailing. They concluded that nailing using elastic nails is the preferred method in children as it is less invasive and gives excellent functional outcomes and cosmetic results. Wall L et al,^[7] demonstrated a retrospective study on 32 cases of age group between 12- 18 years, who were treated using intramedullary nailing for fractures of both bone forearm and concluded flexible nailing in the treatment of forearm both bone fractures provides early union of fracture and shows excellent results in adolescents age group.

In our study, 5 cases developed loss of forearm rotation postoperatively, of which 2 cases(3.6%) had 30° loss of forearm rotation. These 2 cases were also associated with infection at the entry site. Out of 5, 3 cases (5.4%) had 15° loss of forearm rotation. The remaining 51 cases had forearm rotation of preoperative status with no pain on strenuous work.

In Amit,^[4] et al. series, excellent results were obtained in 95% of patients and good results in the remaining 5% of patients, with mean fracture union at nine weeks. In the Ashraf Salim et al,^[8] study, excellent results were obtained in 77.8% of patients, good results in 16.7 % and fair results in 5.6% of patients, with mean fracture union at 10.38 weeks. All these results were comparable to this study, where 51 (91%) patients had excellent results and, 3 (5.4%) had good results, 2 (3.6%) had poor results based on Price et al. criteria.^[9] The average time of union was 10.75 weeks.

CONCLUSION

This study corroborates the findings of other well-designed studies showing an association between radiographic and clinical outcomes in a patient population with forearm fractures and an improved outcome noted in those cases where good anatomical reduction could be achieved.

This study also concluded that closed reduction and internal fixation guarantee a high chance of union with a decreased complication rate. A plaster cast for three weeks does not reduce the final outcome. Rehabilitation is quick because the joint's immobilization is relatively short.

REFERENCES

1. Vopat ML, Kane PM, Christino MA, Truntzer J, McClure P, Katarincic J, Vopat BG. Treatment of diaphyseal forearm fractures in children. *Orthop Rev (Pavia)*. 2014 Jun 24;6(2):5325. doi: 10.4081/or.2014.5325. PMID: 25002936; PMCID: PMC4083309.
2. Kay S, Smith C, Oppenheim WL. Both-bone mid-shaft forearm fractures in children. *J PediatrOrthop* 1986; 6:306-10.
3. Vainiopaa S, Bostman O, Patiala H, Rokkanen P. Internal fixation of forearm fractures in children. *ActaOrthopScand* 1987; 58:121-3.
4. Amit Y, Salai M, Chechik A, Blankstein A, Horoszowski H. Closing intramedullary nailing for the treatment of diaphyseal forearm fractures in adolescence: a preliminary report. *J PediatrOrthop* 1985; 5:143-6.
5. Furlan D, Pogorelic Z, BiocicJuric, Budimir D, Todoric J, Mestrovic J et al. Elastic stable intramedullary nailing for paediatric long bone fractures: experience with 175 fractures, *Scandinavian Journal of Surgery* 2011;100(3):208-215.
6. Wall L, O'Donnell JC, Schoenecker PL, Keeler KA, Dobbs MB, Luhmann SJ, et al. Titanium elastic nailing radius and ulna fractures in adolescents. *J Pediatr Ortho B* 2012;21(5):482-88.
7. Wall L, O'Donnell JC, Schoenecker PL, Keeler KA, Dobbs MB, Luhmann SJ, et al. Titanium elastic nailing radius and ulna fractures in adolescents. *J Pediatr Ortho B* 2012;21(5):482-88.
8. Ibrahim, Ashraf &Abdelrahman, Khaled &Sebaei, Mohamed &Abdeldayem, Yamen. (2021). Intramedullary Elastic Nailing Management for Fracture of Forearm Bones in Pediatric Patients. *The Egyptian Journal of Hospital Medicine*. 85. 4108-4114. 10.21608/ejhm.2021.207255.
9. Price CT, Scott DS, Kurzner ME, Flynn JC. Malunited forearm fractures in children. *J PediatrOrthop* 1990;10(6):705-712. doi:10.1097/01241398-199011000-00001