

Received : 03/01/2024
 Received in revised form : 08/02/2024
 Accepted : 05/03/2024

Keywords:
adnexal tumors, skin tumors, eccrine, apocrine, sebaceous, porocarcinoma.

Corresponding Author:
Dr. Vivek Kharolkar,
 Email: kharolkarvivek@gmail.com.

DOI: 10.47009/jamp.2024.6.2.3

Source of Support: Nil,
 Conflict of Interest: None declared

Int J Acad Med Pharm
 2024; 6 (2); 12-16



Nirmalkumar C Nemane¹, Rahul V Taksande², Buddheshwar N Hiwale³, Vivek D Kharolkar⁴, Sneha P Janjal⁵, Sukanya Shyam⁶, Saanika Chavan⁷

¹Assistant Professor, Department of Pathology, Rajarshree Chhatrapati Shahu Maharaj Government Medical College, Kolhapur, India.

²Professor, Department of Pathology, Grant Government Medical College, Mumbai, India

³Professor and Head of department, Department of Pathology, Grant Government Medical College, Mumbai, India.

⁴Assistant Professor, Department of Pathology, Grant Government Medical College, Mumbai, India.

⁵Assistant Professor, Department of Pathology, H.B.T Medical College, Mumbai, India.

⁶Junior Resident, Department of Pathology, Grant Government Medical College, Mumbai, India.

⁷Junior Resident, Department of Pathology, Grant Government Medical College, Mumbai, India.

Abstract

Background: The skin is the largest organ of the body. Skin is affected by various neoplastic and non-neoplastic conditions. Due to various occupational hazards, rise in temperature and sun exposure there has been considerable increase in the skin disorders. The present study has been conducted to assess the incidence and histopathology of different skin adnexal tumors. **Material and Methods:** A prospective study of 50 skin biopsies was conducted over a period of 1.5 years (Nov 2019 to April 2021) at a tertiary health care hospital. Tumors and tumor like conditions of skin adnexa along with melanogenetic tumors and tumors of skin appendages were included. A novel approach was applied which included the histological arrangement and architectural pattern of tumors. An attempt was made to correlate the clinical diagnosis with histopathology. **Result:** Females were affected more than males (M: F = 1: 1.08). The incidence of benign tumors (92%) was more than malignant (8%). Head and neck region was the most common site affected. The maximum no of cases were seen in 31-40 years age group. Most of the tumors were of sweat gland differentiation type (48%), followed by hair follicular differentiation (28%), sebaceous differentiation (24%) and miscellaneous (2%). **Conclusion:** Since the clinical diagnoses made in many cases did not correlate with the microscopy, histopathology remains the gold standard for dermatopathies. Also, it has therapeutic implications and warrants follow up in cases where recurrences are anticipated.

INTRODUCTION

The skin is the largest and complex organ of the body. Besides providing protection from the external forces, skin also synthesises Vitamin D with the help of sunlight.

Like any other organ, skin is also not spared from tumorigenesis. A wide variety of tumors are encountered involving the skin and its appendages. Most of the skin tumors are benign. Malignant melanoma, squamous cell carcinoma and basal cell carcinoma are the commonest malignant tumors.^[1]

Increasing exposure to UV light is the most important predisposing factor for skin cancer. It not only causes DNA damage but also leads to generation of free radicals and defect in the p53 expression.^[1,2] Other factors involved are variations

in skin types, geographical latitudes and occupational exposure.^[3]

Skin adnexal tumors (SATs) give rise to bewildering number of neoplasms, more than accounted. Adnexal tumors are rare and so is the literature about their clinico-pathological features.^[4] The clinical presentation is often similar to malignant tumors. Sometimes, secondary changes like bleeding, ulceration panics the patient eventually leading to resort to medical help.

Literature has given some insight regarding the pathogenesis of SATs. These tumors arise from multipotent undifferentiated cells which are seen in epidermis and the adnexa.^[5] The histopathological features of SATs go hand in hand with the activating molecular pathways that are responsible for the formation of the respective adnexa.^[5]

The broad classification of SATs consists of three main categories depending on the morphology of tumors resembling sebaceous glands, sweat glands (eccrine/ apocrine) and hair follicles.^[6] Tumors with sebaceous proliferations are usually diagnosed without any difficulty owing to the presence of vacuolated sebocytes. Sweat gland tumors are characterised by formation of sweat duct. If both these tumors are ruled out then it is quite evident that we are dealing with hair follicular tumors.^[6,7]

Generally, the site, appearance, duration and histopathology are sufficient to diagnose SAT accurately. These tumors sometimes have syndromic association like Muir-Torre syndrome, Cowden syndrome.^[8] Malignant SATs are rare and sometimes may present as metastasis causing significant morbidity and mortality.^[8] So accurate reporting of SAT cannot be over-emphasized. Immunohistochemistry (IHC) can be used but its role is limited.

In this study we have attempted to assess the incidence and examine the histopathological features of different SATs.

MATERIALS AND METHODS

A prospective study of 50 cases of skin biopsies was conducted in the histopathology section of the Department of Pathology for a duration of 1.5 years from Nov 2019 - April 2021, after obtaining ethical approval from the Institutional Ethics Committee.

Biopsies showing tumors and tumor like conditions of skin adnexa along with melanogenetic tumors and tumors of skin appendages were included from all the age groups. Soft tissue tumors, haematological tumors and secondary tumors were excluded. Similarly, inadequate or non-representative biopsies were not included in the study.

All the relevant clinical details like age, gender, site, presentation, duration of complaints and clinical diagnosis were obtained from the histopathology requisition form and medical records.

All the skin biopsies were received in 10% formalin. Almost all the skin biopsies were smaller in size, hence all the tissue was processed entirely in automated tissue processor. The sections were taken from formalin fixed, paraffin embedded blocks and were 4 to 5 micron thin. The sections were stained with Hematoxylin and Eosin (H&E). Special stains like PAS (Periodic acid Schiff's) stain were used as indicated. After digitalization of the data, appropriate statistical analysis was done.

RESULTS

Out of the 50 cases taken into consideration, maximum no of cases were seen in the age group of 31-40 years (12 cases, 24%) and only one case (2%) was seen in the age group of 71-80 years. The youngest case involved was 3 years old, hence the age range was 3 to 71 years.

There was slight female preponderance (n=26, 52%) as females were affected more than males (n=24, 48%) and F: M ratio was 1.08:1.

The maximum number of lesions were found on the face (n= 20, 40%), followed by nine cases in the region of scalp (18%). Only one case was found affecting lower limb. Two malignant cases were seen in the periorbital region and both of them were sebaceous carcinoma. Other sites involved were neck, trunk and upper limb.

Histopathological study revealed various differentiation among the tumors which showed maximum number of cases (n=14) showing mixed type of differentiation (both apocrine and eccrine differentiations, hair follicle differentiation (n=13) and sebaceous differentiation (n=12). There was single case of piloleiomyoma (n= 1) showing miscellaneous type of differentiation towards smooth muscle. Majority of the cases were of benign tumors (n= 46, 92%) and out of them, 22 benign tumors were seen in males while 24 benign tumors were seen in females. There were four malignant cases in the present study (8%). Two cases were seen among males and two were seen in females. All the four cases of malignant tumors were seen in around age of 40-60 years of age and were reported as sebaceous carcinoma (n=2) in periorbital region, porocarcinoma (n= 1) seen in lower limb and microcystic adnexal carcinoma (n= 1) found in the region of scalp. As per the novel approach, tumors with proven epidermal connection were 12 (24%) – of which eleven were benign tumors and one was malignant - Porocarcinoma. Maximum number of tumors did not show any epidermal connection, (n= 38 cases, 76%) and three cases were malignant tumors among them.

Few of the benign and malignant skin adnexal tumors are seen more frequently while certain tumors are rarely encountered. Likewise, in present study, out of total 50 tumors, cases of syringocystadenoma papilleferum were maximum in numbers (n= 7), followed by steatocystoma multiplex (n= 6) and pilomatricoma (n= 6). Tumors of sebaceous differentiation were the next frequently found tumors- Sebaceoma (n= 3), sebaceous carcinoma (n= 2) and sebaceous adenoma (n= 1). Syringoma was seen next in the order according to frequency (n= 5). Out of total five cases of syringoma, the one was chondroid syringoma. Eccrine poroma, trichilemmal cysts and trichoepithelioma were seen to have occurred in same frequency (n= 3) while rest of the tumors were seen in fewer numbers. The skin adnexal tumors have shown different histological architectural arrangements like solid, solid-cystic and cystic. Out of total 50 tumors studied, 31 tumors were in solid pattern (62%), 17 tumors were in solid cystic pattern (34%) while 2 tumors were seen in cystic pattern (4%). A table (table 1) is provided which shows various characteristics of different studies including the present study. Figures 1 and 2 show

histomorphology of skin lesions in the present study.

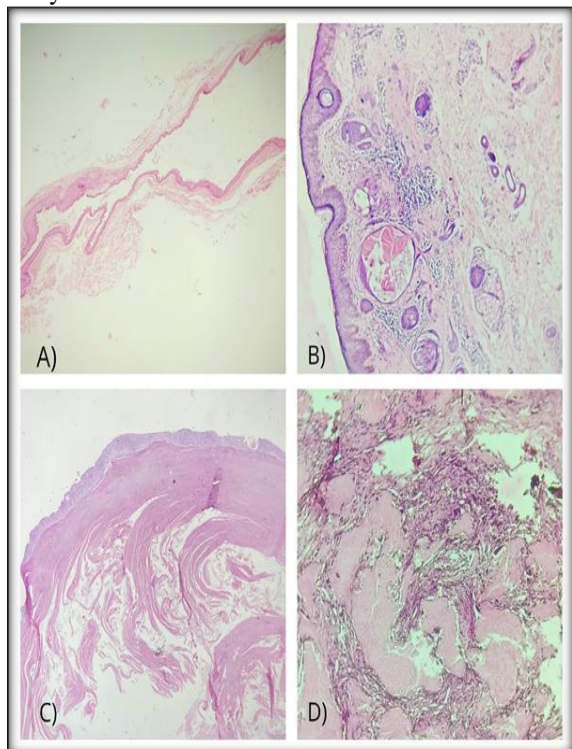


Figure1: A to D) Low power 10x, Hematoxylin & Eosin staining showing, A) Steatocystoma multiplex, B) Chondroid Syringoma, C) Trichilemmal cyst, D) Pilomatricoma.

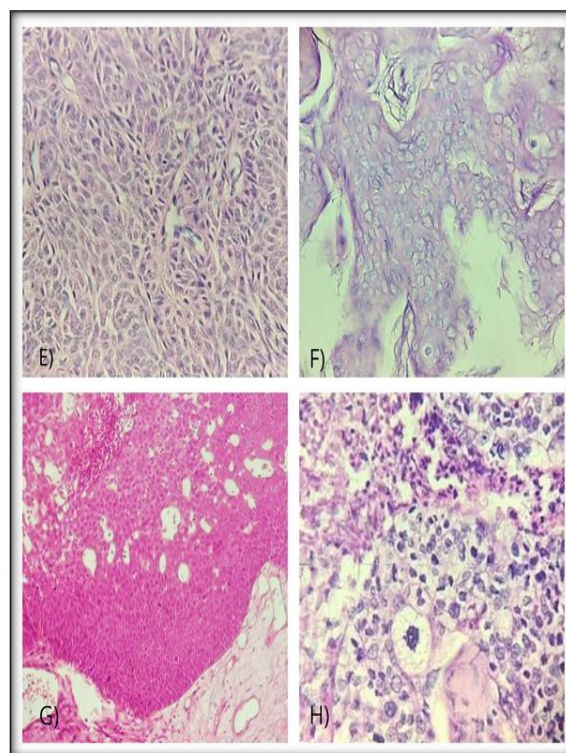


Figure 2: E to F) High power, 40x Hematoxylin & Eosin staining showing, E) Eccrine Poroma, F) Porocarcinoma, G) Sebaceoma, H) Sebaceous Carcinoma

Table 1: Comparison of various parameters seen in different studies

Study	Age group frequently affected (years)	Female: Male Ratio	Most common differentiation	Percentage of benign tumors
Kayiran A et al	40-49	1.5: 1	Sebaceous	95.4
Paudyal P et al	41-50	2.03:1	Hair Follicular	97.1
Gopidesi D et al	31-40 & 51-60	01:01.1	Eccrine	96.67
Omar M et al	31-40 & 51-60	01:01.6	Sweat glands	94.4
Longjam et al	21-30	1.42:1	Hair Follicular	94
Kawalpreet K et al	20-39	01:01.0	Hair Follicular	82.73
Present study	31-40	1.08:1	Sweat glands	92

DISCUSSION

There is a wide variation in the age group distribution of the SATs. Most of the studies have revealed that the most commonly affected age group was 40-50 years. Paudyal P et al, Kayiran A et al, Omar et al found out the same.^[9-11] Longjam D et al found that the age group of 21-30 years was most commonly affected.^[12] Similarly Kanwalpreet K et al described that the age group of 20-39 years was the most commonly affected.^[13] In our study, the most common age group affected was 31- 40 years. The age range in which cases are seen in various comparative studies has seen to be almost in matching range. In all the studies, few of cases were seen to be reported in first decade of life and few cases were reported even in elderly individuals in the 7th and 8th decade of their life. In the present study, age range was from 3 years to 71 years and

almost similar age range was seen to be affected in most of the studies like Kayiran A et al, Paudyal P et al, Omar M et al.^[9-11] Many of the comparative studies showed least number of cases in age group of 0-10 years like, Longjam D et al, Gopidesi D et al, Kanwalpreet K et al.^[12-14] In the present study, age group of 71-80 years was the least commonly affected and followed by age group of 0-10 years with minimum number of cases. Paudyal P et al, Omar M et al did not mention the least commonly affected age group in their studies.^[9,11]

The female to male ratio of incidence of SATs seen in this study was 1.08:1 which indicated slight female preponderance. The comparative studies showed similar findings with minimal variation in gender wise distribution of the cases. Kayiran A et al, Paudyal P et al and Longjam D et al had slight female preponderance of incidence among the cases, which match with the findings in the present

study.^[9,10,12] Also, Paudyal P et al had shown that female population was affected predominantly with a ratio of 2.03:1.^[9] At contrary another study by HK Manjunath et al stated that males were affected more and the male to female patient ratio was 1.47:1.^[15]

Head and neck region was the most common site affected in all the studies. The present study showed similar type of distribution of cases showing that 80% cases reported in the region of head and neck. Kayiran A et al, Paudyal P et al, Gopidesi D et al, Kanwalpreet K et al, Omar M et al and Sharma A et al found that most common region affected was head and neck.^[9-11,13,14,16] Also, Kayiran A et al, Gopidesi D et al noted that the limbs were the least commonly affected anatomical site.^[10,14] It was observed that only 6% of the cases were seen in the extremities and hence it was the least commonly affected anatomical site even in the present study.

The SATs were segregated in different groups as per their histological differentiation like hair follicular differentiation, sebaceous differentiation, sweat glands differentiation – either eccrine or apocrine or both (mixed type) and rarely tumors with miscellaneous differentiation. In the present study, 28% of the tumors had shown sweat glands differentiation of mixed type; followed by tumors with hair follicular differentiation (26%) and then followed by tumors with sebaceous differentiation (24%). Apocrine differentiation was observed in 10% of the tumors and eccrine differentiation in 10% of the tumors. Tumors with miscellaneous differentiation contributed to only 2% of the total number of cases in the present study.

The various studies when compared with present study showed that Sharma A et al, Omar M et al and Radhika K et al had similar findings in their studies; most common type of differentiation was of sweat glands.^[11,16,17] Even Gopidesi D et al found that sweat gland differentiation was the most common (but in their studies, they considered eccrine and apocrine differentiation as separate groups only and not the mixed type).^[14]

Kanwalpreet K et al, Longjam D et al and Paudyal P et al saw that the hair follicular type of differentiation was the most common type.^[9,12,13] The least common type of differentiation among the tumors studied in various studies showed variability. Radhika K et al and the present study got similar findings in the context of type of tumor differentiation.^[17] It was observed that the tumors of miscellaneous type of differentiation were showing lowest incidence among the total number of tumors in both the studies.

Studies of skin adnexal tumors showed that benign tumors always outnumbered the malignant tumors. In the present study, out of total 50 skin adnexal tumors, 46 tumors (92%) were benign while only 4 tumors (8%) were malignant. The various studies of SATs mentioned the same data stating that benign skin adnexal tumors were most commonly found as compared to their malignant counterparts.

Percentage of incidence of benign tumors was 80.36% in Sharma K et al and 97.1% in Paudyal P et al. [9,16] While in present study, it was found that 92% of the tumors were benign and this was matching with the percentage of incidence of benign tumors in other studies.^[10-17]

The incidence of malignant tumors was in range of 2.9% in Paudyal P et al to 22.85% in Radhika K et al.^[9,17] And when compared with the present study, 8% of the malignant tumors were found and it was in the same range as seen in other studies. Therefore, incidence of both benign and malignant skin adnexal tumors in the present study matched with all the comparative studies.^[10-17]

Arakeri S et al studied the various SATs in the context of their histological architectural arrangements.^[18] This was altogether a different approach in the SATs. Their study mentioned that histological architecture and cellular morphology of different SATs helped the pathologists to understand the particular details of tumor composition and thus help in diagnosis. It was seen that tumors with solid pattern are most commonly occurring while next common pattern is solid cystic.^[18] And purely cystic type of pattern, is least common in occurrence among the total tumors studied. Our study also showed similar findings.

CONCLUSION

Skin lesions and tumors are usually associated with minimal complaints, so most of the time they are ignored. Even if medical help is sought, it is for cosmetic purposes. That's why people often visit clinicians if they have lesions in exposed areas. Most of the times, it becomes difficult to assess the behaviour of tumor as the size of the tumor is small in the beginning. Any rapid increase in size, change in colour, ulceration or presence of necrotic debris is alarming to the patient. Also, at this time the diagnosis of malignant tumor is quite possible. Sometimes, the regional lymph nodes are enlarged pointing towards metastasis. The gross appearance of excisional skin biopsies is usually similar and do not aid in diagnosis.

Hence, considered non-contributory. It is always better to have a clinical diagnosis as most of the skin lesions have overlapping histomorphological features. So, histopathological examination is an important adjunct and gold standard to diagnose skin lesions and tumors.

Further, it aids in guiding the therapy and helps in the management. Also, the patients can be regularly followed up where recurrences are known.

Declaration of Patient Consent

Informed consent was obtained from the patients. The patients had given consent for the necessary clinical details including images. Efforts were taken to publish the data without revealing their identities, however anonymity could not be guaranteed.

Acknowledgments: None.

Conflicts of Interest: There are no conflicts of interest.

REFERENCES

1. Didona D, Paolino G, Bottoni U, Cantisani C. Non Melanoma Skin Cancer Pathogenesis Overview. *Biomedicines*. 2018 Jan 2;6(1):6. doi: 10.3390/biomedicines6010006. PMID: 29301290; PMCID: PMC5874663.
2. Thapa R, Gurung P, Hirachand S, Shrestha SB. Histomorphologic Profile of Skin Tumors. *JNMA J Nepal Med Assoc*. 2018 Nov-Dec;56(214):953-957. doi: 10.31729/jnma.3988. PMID: 31065142; PMCID: PMC8827607.
3. Koh, D., Wang, H., Lee, J., Chia, K.S., Lee, H.P. and Goh, C.L. (2003), Basal cell carcinoma, squamous cell carcinoma and melanoma of the skin: analysis of the Singapore Cancer Registry data 1968–97. *British Journal of Dermatology*, 148: 1161-1166.
4. Oyasiji T, Tan W, Kane J 3rd, Skitzki J, Francescutti V, Salerno K, Khushalani NI. Malignant adnexal tumors of the skin: a single institution experience. *World J Surg Oncol*. 2018 May 30;16(1):99. doi: 10.1186/s12957-018-1401-y. PMID: 29848318; PMCID: PMC5977488.
5. Parvati, M., Lekha, G. D., & Ram, M. (2020). A clinicopathological study of skin adnexal tumors - an experience at a tertiary care center in South India. *International Journal of Health and Clinical Research*, 3(8), 107–112.
6. Fulton EH, Kaley JR, Gardner JM. Skin Adnexal Tumors in Plain Language: A Practical Approach for the General Surgical Pathologist. *Arch Pathol Lab Med*. 2019 Jul;143(7):832-851. doi: 10.5858/arpa.2018-0189-RA. Epub 2019 Jan 14. PMID: 30638401.
7. Crowson AN, Magro CM, Mihm MC. Malignant adnexal neoplasms. *Mod Pathol*. 2006 Feb;19 Suppl 2: S93-S126. doi: 10.1038/modpathol.3800511. PMID: 16446719.
8. Veena, S., Susmitha, & Rameshbabu, K. (2018). Histopathologic Evaluation of Skin and Adnexal Tumors in a Tertiary Care Hospital. *Indian Journal of Pathology: Research and Practice*, 7, 109-115. Veena, S., Susmitha, & Rameshbabu, K. (2018). Histopathologic Evaluation of Skin and Adnexal Tumors in a Tertiary Care Hospital. *Indian Journal of Pathology: Research and Practice*, 7, 109-115.
9. Paudyal, Punam et al. "A clinico-histopathological study on skin appendageal tumors." *Journal of Pathology of Nepal* 6 (2016): 885-891.
10. Aslan Kayiran M et al; Are clinicians successful in diagnosing cutaneous adnexal tumors? a retrospective, clinicopathological study. *Turk J Med Sci*. 2020 Jun 23;50(4):832-843. doi: 10.3906/sag-2002-126. PMID: 32283901; PMCID: PMC7379409.
11. Omar AM, Osman NA. Four years' retrospective study of skin adnexal tumors: Histomorphology and special stain study. *Int J Med Sci Public Health* 2020;9(4):273-279.
12. Longjam, Deepa et al. "Histopathological Profile of Skin Adnexal Tumours - A Three Year Experience at a Tertiary Care Centre in Manipur." *Journal of Evolution of Medical and Dental Sciences* (2020).
13. Kaur K, Gupta K, Hemrajani D, Yadav A, Mangal K. Histopathological analysis of skin adnexal tumors: A three-year study of 110 cases at a tertiary care center. *Indian J Dermatol* 2017; 62:400-6.
14. Gopidesi, Divya Tejaswi et al. "Skin Adnexal Tumors: A Histopathological analysis of 30 Cases at a Tertiary Care Centre." (2020).
15. HK Manjunath et al, Histomorphological pattern of analysis of Skin Adnexal Tumours. *National Journal of Laboratory Medicine*. 2020 Oct, 9(4): PO39-PO42.
16. Sharma A, Paricharak DG, Nigam JS, Rewri S, Soni PB, Omhare A, Sekar P. Histopathological study of skin adnexal tumours-institutional study in South India. *J Skin Cancer*. 2014; 2014:543756. doi: 10.1155/2014/543756. Epub 2014 Feb 5. PMID: 24649367; PMCID: PMC3932724.
17. Radhika, Kondareddy et al. "A study of biopsy confirmed skin adnexal tumours: experience at a tertiary care teaching hospital." *The Journal of Clinical and Scientific Research* (2013): 132-138.
18. Arakeri, Satish et al. "Histomorphological Study of Skin Adnexal Tumors and Review." *Indian Journal of Forensic Medicine and Pathology* (2019).