

## OUTCOME OF PRE-CONTOURED ANATOMICAL FIBULA PLATE IN TREATING DISTAL FIBULAR FRACTURES

S.Senthil Sailesh<sup>1</sup>, P Kannan<sup>2</sup>, Ragav Anandham<sup>3</sup>, Jayaoviya N P<sup>4</sup>, Pinku<sup>4</sup>

<sup>1</sup>Associate Professor, Government Villupuram Medical College and Hospital, Tamil Nadu, India

<sup>2</sup>Associate Professor, Government Sivagangai Medical College and Hospital, Madurai, Tamil Nadu, India

<sup>3</sup>Assistant Professor, Government Stanley Medical College and Hospital, Chennai, Tamil Nadu, India.

<sup>4</sup>Post Graduate, Madras Medical College, Chennai, Tamil Nadu, India

Received : 16/12/2023  
Received in revised form : 23/01/2024  
Accepted : 08/02/2024

**Keywords:**

Anatomical fibula plating, distal fibula fractures, osteosynthesis, pre-contoured plates, lateral malleolus fracture.

Corresponding Author:

Dr. Jayaoviya N P,  
Email: npjoviya@gmail.com

DOI: 10.47009/jamp.2024.6.1.212

Source of Support: Nil,  
Conflict of Interest: None declared

Int J Acad Med Pharm  
2024; 6 (1); 1070-1075



### Abstract

**Background:** Orthopaedic surgeons have traditionally found treating ankle fractures to be difficult because of the intricate nature of the injury mechanism, the soft tissue damage that is inevitably caused both by trauma and surgery, and the numerous variables that can affect fracture union and cause surgeons' worst nightmares. Pre-contoured anatomical fibular plates were created in order to address a number of biological and mechanical issues that were present with traditional implants, such as fibular intramedullary nails, malleolar screws, and one-third tubular plates. We assessed the efficacy of treating distal fibula fractures with a pre-contoured anatomical fibular plate. **Materials and Methods:** Thirty patients who reported with Weber B and Weber C type ankle fractures between May 2021 and December 2022 at the Institute of Orthopaedics and Traumatology, RGGGH, Chennai, were evaluated prospectively and retrospectively after undergoing surgical fixation with a pre-contoured anatomical fibula plate. Analysis was done on a clinical, functional, and radiological level. Range of motion and clinical indications of fracture union were noted. The American Orthopaedic Foot and Ankle Society (AOFAS) - Ankle and Hindfoot scale grading method was utilised for the functional assessment, and subsequent follow-up x-rays were analysed for radiological evidence of bridging callus and consolidation of fracture line. **Result:** Thirty patients who reported with Weber B and Weber C type ankle fractures between May 2021 and December 2022 at the Institute of Orthopaedics and Traumatology, RGGGH, Chennai, were evaluated prospectively and retrospectively after undergoing surgical fixation with a pre-contoured anatomical fibula plate. Analysis was done on a clinical, functional, and radiological level. Range of motion and clinical indications of fracture union were noted. The American Orthopaedic Foot and Ankle Society (AOFAS) - Ankle and Hindfoot scale grading method was utilised for the functional assessment, and subsequent follow-up x-rays were analysed for radiological evidence of bridging callus and consolidation of fracture line. **Conclusion:** Pre-contoured anatomical locking fibula plate has proven to be an effective fixation option in managing distal fibula fracture with superior biomechanical, functional, and radiological outcomes.

## INTRODUCTION

Ankle fractures are one of the most encountered fractures involving the lower limb next to hip fractures. They account for nearly 10% of all fractures with an incidence of 137 per 100,000 persons per year.<sup>[1]</sup> Among these, isolated distal fibula fractures account for more than 50% of all ankle fractures.<sup>[2]</sup> These injuries have a bimodal distribution, with peak evidence in younger men and

older women and a 50-year gap between the peaks. Ankle fractures are primarily low-energy injuries occurring due to trivial fall sustaining twisting/rotational injury during sporting activity or road traffic accidents or self-falls in elderly patients with osteoporotic bones. Ankle dislocation may result from a high-velocity injury. Since the ankle is one of the main joints that bear weight, orthopaedic surgeons have a difficult time treating ankle fractures. Injuries around the ankle

joint cause destruction of not only the bony architecture but also the ligaments and soft tissue components.<sup>[3]</sup> Treatment options involving ankle fractures have high rates of patient dissatisfaction as they have chronic pain, instability or infection. This leaves surgeons with a narrow margin of error, which is further complicated by the intricate regional anatomy, severe oedema that develops after an injury, and the region's limited ability to repair wounds. Only slight variation from normal is compatible with good joint function and better patient outcomes.

Distal tibiofibular syndesmotic injuries account for 30% of ankle injuries and about 20% of syndesmotic injuries. These injuries when missed diagnosis and not treated may lead to ankle instability and in turn, predispose to early onset degenerative arthritis.<sup>[4]</sup>

AO principles of management of bimalleolar ankle fractures emphasise anatomical reduction of fracture, stable internal fixation, regaining full length of fibula, maintaining distal tibiofibular syndesmosis and early active pain-free mobilization, and avoiding long-term complications like joint stiffness, residual pain and post-traumatic osteoarthritis.<sup>[5]</sup>

The initial management of ankle fractures involves immediate closed reduction of ankle dislocation and immobilization with an external fixator or bivalved cast. In order to maintain stability after reduction and prevent oedema and neurovascular complications, it is imperative to elevate the affected limb while awaiting definitive osteosynthesis.

Though non-operative fractures (with a long leg cast until fracture union) are used to treat undisplaced isolated lateral malleolus fractures without syndesmotic injury, the primary treatment of ankle fractures is open reduction and internal fixation.

Surgical options include stabilising the fracture with a lag screw with or without neutralizing plate, intramedullary nails or Kirschner wire fixation.

Due to the subcutaneous nature of the distal fibula, osteosynthesis of the fibula with plates is a challenge. Plating options for distal fibula include one-third fibula plate, locking compression plate (LCP), and pre-contoured anatomical locking compression plate. Management with conventional low-profile plating methods (one-third plate) has been associated with lesser screw purchase on osteoporotic bones. Therefore, stabilising the fracture with an implant that has greater fixation strength (locking compression plate) can reduce failure rates and offer better functional treatment. However, due to the relatively increased thickness of LCP plates, there is increased concern for wound healing problems and surgical site infection.

To the best of our knowledge, there are limited studies that evaluate the outcomes of patients treated with pre-contoured anatomical fibula plates in the Indian population.

We aimed to study the patient-related outcome and effectiveness of the pre-contoured anatomical fibular locking plating in successfully treating distal fibula fractures.

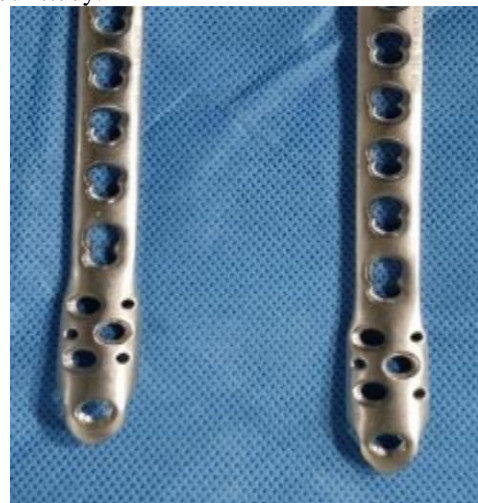## MATERIALS AND METHODS

Retrospective and prospective study was carried out in a single institution, the Institute of Orthopaedics and Traumatology, Madras Medical College and Rajiv Gandhi Government General Hospital, in 30 patients from the period of March 2021 to April 2022. After institutional ethics committee approval, patients with Weber B and Weber C type of ankle injury (Denis – Weber classification) above 18 years of age who underwent surgical fixation with a pre-contoured anatomical fibula plate were included in the study. Patients with associated ankle dislocation and medial malleolus fractures were also included in the study.

Undisplaced distal fibula fractures, Weber A type of ankle injury, and Compound fractures were not included in the study.

After initial resuscitation and radiological workup, patients were immobilized in below knee slab and limb elevation were ensured. Serial monitoring of the limb was carried out, meanwhile, patients were thoroughly evaluated for surgical fixation. All routine blood investigations were done as a part of the pre-operative planning. If the patient had any medical comorbidities, a concerned specialist opinion was obtained before taking up for surgery. Surgical fixation was planned once the oedema settled which was assessed by a positive wrinkle sign. Radiographic evaluation included AP, lateral, and mortise view. Further CT scan was carried out when needed. The classification was done using the Denis – Weber Classification. Weber B and Weber C type of ankle injury was included in our study. (Figure 3) Syndesmotic injury occurs about half in type Weber B and in all type Weber C fractures whereas syndesmotic injury without fracture accounts for 1–11% of all injuries.<sup>[6]</sup>

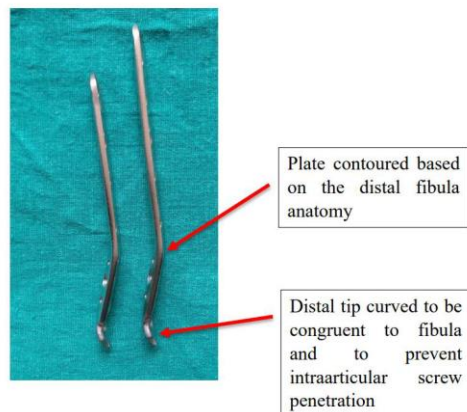
**Implant selection:** A 3.5mm pre-contoured anatomical locking fibula plate [Figure 1] was used in our study.



**Figure 1: this figure shows 3.5mm pre-contoured anatomical fibula plate used in our study**

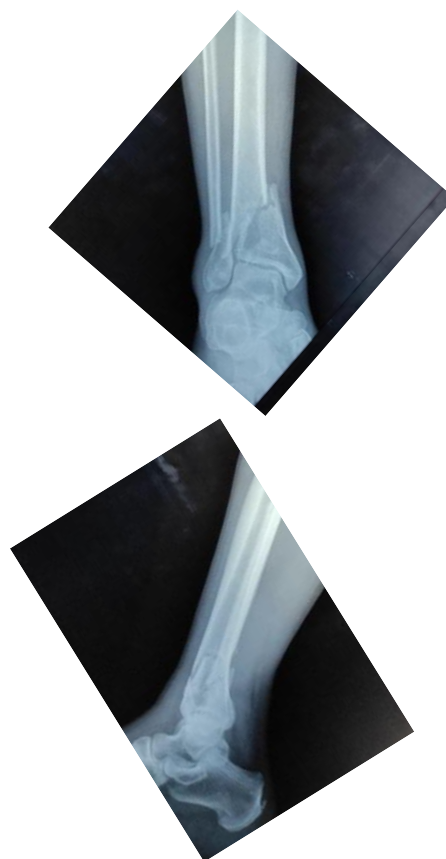They are available from 3-holed plates to 10-holed plates. The sleeve is used for applying locking screws

and a 2.7 mm drill bit was used. The lateral view of the plate shows [Figure 2] the pre-contouring done to complement the distal fibular anatomy, hence there was no need for plate bending or contouring intraoperatively. The distal tip was curved to be congruent to the fibula and to prevent intraarticular screw penetration.



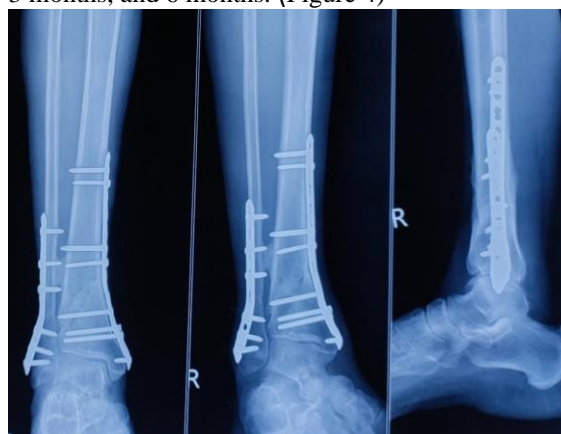**Figure 2:** this figure shows pre-contouring done to complement the distal fibular anatomy

**Surgical technique:** After administration of spinal anesthesia, the patient was positioned in a supine position on a radiolucent table with the injured extremity draped below the knee level. To allow the wounded limb to internally rotate sufficiently and allow the fibula to approach from the side, a sandbag is kept below the ipsilateral pelvis. Through a lateral approach to fibula, incision is made directly over the subcutaneous border of the fibula, the length and center of the incision was dictated by the level and type of fracture present. The superficial peroneal nerve, which passes through the deep fascia and is in the subcutaneous fat, was identified and preserved. Only the amount necessary to enable an anatomical reduction was done to elevate the periosteum away from the fracture borders. The front fascia was strategically perforated to enable the implantation of reduction clamps without undue dissection. The reduction is done with controlled traction and mild inversion of the foot and with a point reduction clamp. Reduction is checked under C- Arm and the anatomical Locking Compression Plate is placed on the fibula under C-Arm guidance and screws inserted. The reduction of the fracture and the position of the plate are checked under the c-arm. If a satisfactory result is obtained, closure is done one in layers with Allgower- Donati sutures.



**Figure 3:** A 40 year old male sustained Weber C type of distal fibula fracture

**Post-Operative Care:** The operative limb is kept elevated. Intravenous antibiotics were given for 3 days and then converted to oral antibiotics for 5 days. The dressings were checked on the 2<sup>nd</sup> and 5<sup>th</sup> postoperative days. Suture removal was done on the 12<sup>th</sup> postoperative day. Assisted ankle mobilization was initiated from 2<sup>nd</sup> week. Strict non-weight bearing after 6 weeks. Full weight bearing after 12 weeks. Subsequent follow-up was done on 6 weeks, 3 months, and 6 months. (Figure 4)



**Figure 4:** 6 months follow up of the above-mentioned patient

**Outcomes:** Clinical, functional, and radiological analysis was carried out. Clinical signs of fracture union and range of movements were documented. Functional assessment was done using the American Orthopaedic Foot and Ankle Society (AOFAS) –

Ankle and hindfoot scale scoring system, while radiological assessment was done by assessing evidence of bridging callus and consolidation of fracture line in successive follow-up x-rays. AOFAS score assesses the pain in daily activities, functional limitations and clinical alignment of the foot. The score ranges from 0 to 100. A score above 90 shows an excellent outcome and a score between 80 to 90 shows a good outcome.

Secondary outcomes were measured based on complications like non-union, malunion, implant failure, infection, neurovascular injuries etc.

## RESULTS

The collected data were analyzed with IBM SPSS Statistics for Windows, Version 23.0. (Armonk, NY: IBM Corp). To describe about the data descriptive statistics frequency analysis, and percentage analysis were used for categorical variables and the mean & SD were used for continuous variables.

According to a gender distribution analysis, amongst the study population, 53% (n = 16) were females and 47% (n = 14) were males. An analysis of age distribution (Figure 5) revealed that just 10.0% of people were under 30, 13.3% were between 31 and 40 years old, 23.3% were between 41 and 50 years old, 26.7% were between 51 and 60 years old, 23.3% were between 61 and 70 years old, and 3.3% were between 71 and 80 years old. 57% of our patients suffered fractures as a result of a self-fall, while the remaining patients experienced fractures as a result of RTA. Of our patients, 56.7% experienced injuries to their right side. Weber B type ankle injuries were the most prevalent fracture pattern seen in almost 76.7% (n=23) of patients, whereas Weber C type ankle injuries were sustained by 23.3% of patients (Figure 6). In addition to the distal fibula fracture, 76.6% of patients also had a fracture of the medial malleolus. (Figure 7)

Other associated fractures observed in our study were Distal tibia fracture (16.7%), distal tibia and femur fracture (3.3%). 20 % of patients in our study population had Type 2 diabetic mellitus, 10% had systemic hypertension, and 6.7% had both.

With scores ranging from 82 to 96, the average AOFAS score was determined to be 92.4. 13.3% (n=6) of the cases had a good outcome, while 86.7% (n=24) of the cases had an excellent outcome. (Figure 8)

In our study, we observed mean ROM at 6 months follow-up as

Ankle dorsiflexion 16.4 +/- 2.0, Ankle plantar flexion 30.1 +/- 2.3, Inversion 16.2 +/- 1.1, Eversion 16.6 +/- 1.2. With a range of 10–16 weeks, all 30 instances

reached radiological union at an average of 12.7 weeks. [Table 1].

Only 2 patients experienced complications following plating, both suffered superficial surgical site infections effectively managed with antibiotics alone. Table 2 summarizes all the continuous variables analysed in our study:

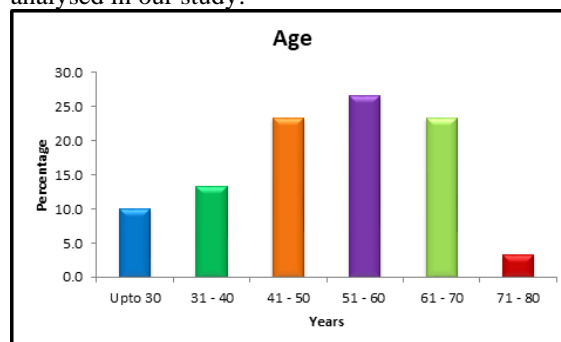


Figure 5: chart showing the age distribution of our study sample

The above table shows Age distribution were 10.0% is Upto 30 years, 13.3% is 31-40 years, 23.3% is 41-50 years, 26.7% is 51-60 years, 23.3% is 61-70 years, 3.3% is 71-80 years.

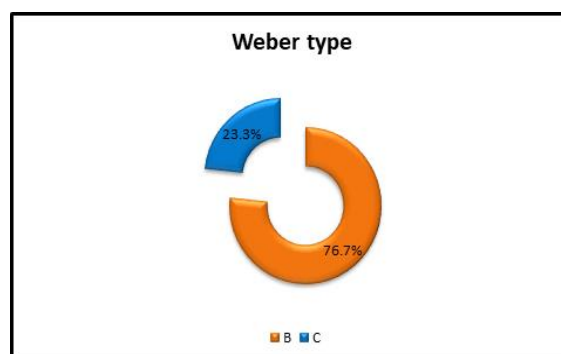


Figure 6: chart showing the distribution of type of fractures in our study

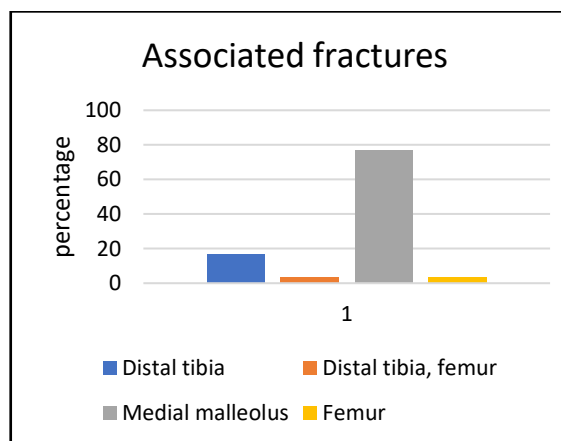


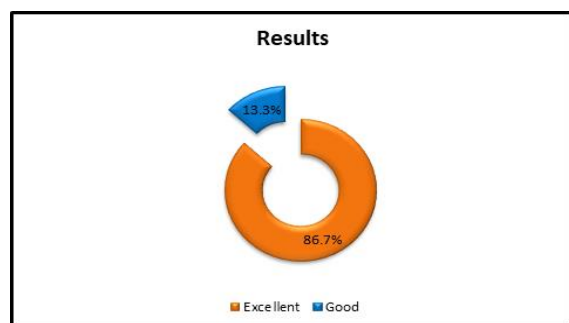
Figure 7: table shows other distribution of other fractures associated with distal fibula fracture

Table 1: time for union in weeks

Time for union in weeks		
Weeks	Frequency	Percent
10	5	16.67
12	12	40
14	10	33.33
16	3	10

**Table 2: The below table shows descriptive statistics of continuous variables.**

Descriptive Statistics					
	N	Minimum	Maximum	Mean	SD
Age	30	26.0	78.0	50.9	13.5
Duration of injury before surgery	30	6.0	21.0	10.8	3.2
Follow up in months	30	6.0	16.0	10.3	3.4
Ankle dorsiflexion	30	12.0	20.0	16.4	2.0
Ankle plantar flexion	30	24.0	32.0	30.1	2.3
Inversion	30	14.0	18.0	16.2	1.1
Eversion	30	14.0	18.0	16.6	1.2
Time of union in weeks	30	10.0	16.0	12.7	1.8
AOFAS Score	30	82.0	96.0	92.4	4.1



**Figure 8: chart showing the distribution of outcome**

## DISCUSSION

For distal fibular fractures, open reduction and internal fixation remain the standard treatment. The effectiveness of several distal fibula fixation solutions has been the subject of numerous biomechanical and clinical research due to a variety of problems, including persistent discomfort, instability, wound dehiscence, and infection. However, there are limited analyses done in the Indian population. While some studies have focused on comparing locking plates and one-third tubular plates, very few studies focus on pre-contoured anatomical fibula plate.

We analysed the effectiveness of using pre-contoured anatomical fibula plating in treating distal fibula fractures with or without associated injuries.

While the majority of participants in previous studies have been men, over half of the participants in our study were female. With a mean age of 50.9 years, more than 70% of the participants in our study were between the ages of 40 and 70. This is consistent with the research that Jae Hoon Ahn et al.<sup>[7]</sup> conducted. Their average age was 53.3 +/- 17.5. A self-fall resulted in minor injuries for 57% of the patients, with the other patients suffering fractures as a result of road traffic accidents.

Rising incidence in the late 40s and in females, with the majority of injuries sustained from minor trauma highlight the need to prioritise bone health and osteoporosis prevention.

The majority of patients (78.7%) had ankle fracture of the Weber B type, while the remaining patients had ankle fracture of the Weber C type. According to studies, syndesmotic injuries were present in more than half of Weber B fractures and all of Weber C

fractures.<sup>[6]</sup> Using Cotton's test, syndesmotic injuries were evaluated intraoperatively and properly repaired. Although our study did not do an independent analysis on the same.

Following an injury, surgery was delayed for an average of 10 days (with a minimum of 6 days and a maximum of 16 days). When comparing the time to definitive fixation for our patients to that of Thomas Giver Jensen et al., there was a noticeable delay in our study.<sup>[8]</sup> They had an average delay of 4 days. SachiYuki Tsukada et al,<sup>[9]</sup> sample group of 52 individuals experienced an average delay of 7 days. Relative delays in early definitive fixation of our patients highlight the need of effective initial care of these fractures, even if no statistically significant relationship was found between delayed surgery and outcome.

The following table shows the results of a clinical outcome analysis in which the ankle joint's range of motion at six months of follow-up from our study was compared to normal ankle range of motion as described by Stauffer et al.<sup>[10]</sup> [Table 3]

	Our study	Stauffer et al
Ankle dorsiflexion	16.4 +/- 2.0	10-20
Ankle plantar flexion	30.1 +/- 2.3	40-55
Inversion	16.2 +/- 1.1	20-23
Eversion	16.6 +/- 1.2	15-17

**Table 5: Table showing comparison of ROM**

In our study, we observed near-normal dorsiflexion and plantar flexion in comparison with normal, unoperated limbs. Plantar flexion and inversion were, nevertheless, limited. Our investigation produced results that were equivalent to those of Jae Hoon Ahn et al.<sup>[7]</sup>

ZeYu Huang et al,<sup>[11]</sup> comparative study examined the results of treating distal fibula fractures with one-third tubular plates, locking plates, and locking distal fibula plates. They concluded that locking distal fibula plates were a better option for complicated ankle injuries, particularly those of the Weber B and C variety. Jae Hoon Ahn,<sup>[7]</sup> compared one third plates and anatomical locking plates and had an average AOFAS score of 88 for anatomical locking plate which was less than that of one third tubular plate. After considering hardware issues, costs, and longer surgical times, they finally concluded that one-third

plate fixation was superior to anatomical locking plates for the distal fibula.

The AOFAS score at six months ranged from 82 to 96, with an average of 92.4 reported in our study. 13.3% (n=6) cases had good outcomes (scoring-80 to 90), while 86.7% (n=24) cases had excellent outcome (score >90). This is comparable to the 94+/-7 AOFAS score reported by Mario Herrera Perez et al,<sup>[12]</sup> and the 92.6 score reported by ZeYu Huang et al.<sup>[11]</sup>

In a research comparing locking and non-locking compression plates in 62 patients, Mario Herrera Perez et al,<sup>[12]</sup> found that the average duration for union was 12 weeks. We saw comparable results in our study, with an average of 12.7=-/ 1.8 weeks.

An analytical study was conducted by Lewis K. Moss et al,<sup>[13]</sup> to investigate the failure rates of conventional plate fixation in comparison with contoured locking compression plates. Though no failure of fibular plates were observed in either group. The locking compression plate group experienced much more complications, such as deep infections requiring surgical debridement and implant removal due to hardware irritation. These findings led the researchers to conclude that conventional plate fixation was the better choice for treating distal fibula. On the contrary, only 2 (6.7%) of the patients in our study experienced superficial surgical site infections, which were successfully treated with antibiotics. Not even one of our patients experienced hardware problems, and none of them required implant removal.

## CONCLUSION

Pre-contoured anatomical locking fibula plate has proven to be an effective fixation option in managing distal fibula fracture with superior biomechanical fixation property in osteoporotic bone, excellent

fracture union, less implant failure, and fewer complications.

## REFERENCES

1. Reference #4. Public health reports (Washington, D.C. : 1974) vol. 117 Suppl S135-45 (2002).
2. Aiyer, A. A., Zachwieja, E. C., Lawrie, C. M. & Kaplan, J. R. M. Management of Isolated Lateral Malleolus Fractures. JAAOS - J. Am. Acad. Orthop. Surg. 27, (2019).
3. Shibuya, N., Davis, M. L. & Jupiter, D. C. Epidemiology of foot and ankle fractures in the United States: an analysis of the National Trauma Data Bank (2007 to 2011). J. foot ankle Surg. Off. Publ. Am. Coll. Foot Ankle Surg. 53, 606–608 (2014).
4. Weening, B. & Bhandari, M. Predictors of functional outcome following transsyndesmotric screw fixation of ankle fractures. J. Orthop. Trauma 19, 102–108 (2005).
5. Hodgson, S. AO Principles of Fracture Management. Annals of The Royal College of Surgeons of England vol. 91 448–449 (2009).
6. Canton, G. et al. Fibula fractures management. World J. Orthop. 12, 254–269 (2021).
7. Ahn, J. H., Cho, S. H., Jeong, M. & Kim, Y. C. One-Third Tubular Plate Remains a Clinically Good Option in Danis-Weber Type B Distal Fibular Fracture Fixation. Orthop. Surg. 13, 2301–2309 (2021).
8. Giver Jensen, T., Aqeel Khudhair Almadareb, M., Booth Nielsen, M., Jesper Hansen, E. & Lindberg-Larsen, M. Outcome After Treatment of Distal Fibula Fractures Using One-Third Tubular Plate, Locking Compression Plate or Distal Anatomical Locking Compression Plate. J. Foot Ankle Surg. 62, 524–528 (2023).
9. Tsukada, S. et al. Locking versus non-locking neutralization plates for treatment of lateral malleolar fractures: A randomized controlled trial. Int. Orthop. 37, 2451–2456 (2013).
10. Stauffer, R. N., Chao, E. Y. & Brewster, R. C. Force and motion analysis of the normal, diseased, and prosthetic ankle joint. Clin. Orthop. Relat. Res. 189–196 (1977).
11. Huang, Z. et al. Comparison of three plate system for lateral malleolar fixation. BMC Musculoskelet. Disord. 15, 1–9 (2014).
12. Herrera-Pérez, M. et al. Locking versus non-locking one-third tubular plates for treating osteoporotic distal fibula fractures: a comparative study. Injury 48 Suppl 6, S60–S65 (2017).
13. K., M. L. et al. Implant Failure Rates and Cost Analysis of Contoured Locking Versus Conventional Plate Fixation of Distal Fibula Fractures. Orthopedics 40, e1024–e1029 (2017).