

## PROSPECTIVE STUDY OF FUNCTIONAL, CLINICAL AND RADIOLOGICAL OUTCOME OF OPEN REDUCTION AND INTERNAL FIXATION OF ELEMENTARY AND ASSOCIATED ACETABULAR FRACTURES INVOLVING POSTERIOR WALL

Anshuman Dutta<sup>1</sup>, Siddhartha Rai<sup>2</sup>, Prabin Ch Gogoi<sup>3</sup>

<sup>1</sup>Assistant Professor, Department of Orthopedics, Gauhati Medical College and Hospital, Assam, India.

<sup>2</sup>Assistant Professor, Department of Orthopaedics, Kokrajhar Medical College, Assam, India.

<sup>3</sup>Assistant Professor, PMR, Fakhruddin Ali Ahmed Medical College and Hospital, Barpeta, Assam, India.

Received : 15/08/2023  
Received in revised form : 20/09/2023  
Accepted : 02/10/2023

**Keywords:**

Anatomic reduction, internal fixation, acetabular fractures.

**Corresponding Author:**

**Dr. Siddhartha Rai,**  
Email: allez.sid@gmail.com

DOI: 10.47009/jamp.2024.6.1.16

Source of Support: Nil,  
Conflict of Interest: None declared

*Int J Acad Med Pharm*  
2024; 6 (1); 79-84



### Abstract

**Background:** Fractures of acetabulum and pelvis constitute only 2% of all fractures. Approximately 24–35% of all acetabular fractures have involvement of the posterior wall which is the most common pattern. The standard treatment for displaced acetabular fractures involving the posterior wall includes anatomic reduction, stable fixation and early motion. The current study was undertaken to determine the functional, clinical and radiological outcome following reconstructions and fixation of acetabular fractures involving the posterior wall. **Material & Methods:** A prospective study was done involving 20 cases who had acetabular fractures involving posterior wall. Age of the patients, fracture duration, type of acetabular fractures, post-operative fracture reduction were evaluated. All the cases were followed up for a minimum period of 6 months. Clinical results were graded using Merle d’Aubigne scale and radiological assessment was done using Matta criteria. **Results:** The reduction was anatomical in 80% cases. The functional outcome was excellent/good in 65% cases while radiological outcome was excellent/good in 75% cases. **Conclusion:** Open reduction and internal fixation is a very effective and hence is considered the gold standard of displaced and unstable posterior wall acetabular fractures.

## INTRODUCTION

Fractures of acetabulum and pelvis constitute only 2% of all fractures.<sup>[1,2]</sup> Fractures of the adult pelvis, exclusive of the acetabulum, are either stable fractures that result from low-energy trauma, such as falls in elderly patients or fractures caused by high-energy trauma that result in significant morbidity and mortality.<sup>[3]</sup>

Acetabular fractures, are typically attributable to high energy trauma associated that are difficult to treat surgically and more prone to postoperative complications.<sup>[4]</sup>

Most acetabular fractures involve the posterior wall.<sup>[5,6,7]</sup> In fact, approximately 24–35% of all acetabular fractures have involvement of the posterior wall which is the most common pattern.<sup>[6,7,8,9]</sup> Either most of the posterior wall fractures are comminuted or they are associated with an impaction injury of the articular surface into the

underlying cancellous bone along the margin of the fracture line. Even after surgery it is difficult to know the exact quality of the reduction and the shape and congruity of the articular surface of the acetabulum due to its three-dimensional complex shape.

Accurate evaluation of the resulting union and the likelihood of future osteoarthritis and differentiating between avascular necrosis (AVN) of the femoral head and true post-traumatic arthritis are also hindered. Therefore, surgeons should make every effort to obtain a stable congruous hip joint with complete union of the fragments during the primary surgery because a second operation is not feasible.<sup>[5]</sup> The establishment of specialized radiological views by Judet and Letoumel associated with advancements in diagnosis by image, allowed for better evaluations and helped in indicating the method of treatment.<sup>[10]</sup> Since Letoumel proposed that surgical treatment was associated with a better prognosis than conservative management in patients with acetabular fractures and

dislocations, open reduction with internal fixation and early ambulation have been recommended as basic management.<sup>[11]</sup> Larger posterior wall fragments lead to posterior hip instability and require fixation.<sup>[12]</sup> The standard treatment for displaced acetabular fractures involving the posterior wall includes anatomic reduction, stable fixation and early motion.<sup>[7,10]</sup>

Surgical treatment has evolved to be the treatment of choice as restoration of joint congruity is of paramount importance to reduce the incidence of early hip osteoarthritis. The quality of acetabular fracture reduction is the single most important factor in the long-term outcome of this patients.<sup>[10]</sup>

The current study was conducted to determine the functional, clinical and radiological outcome following reconstruction and fixation of acetabular fractures involving the posterior wall and associated complications thereafter during follow up of such fractures. It was also undertaken to evaluate reconstruction and restoration of anatomy of acetabular fractures and also to evaluate radiological union.

## MATERIALS AND METHODS

A prospective study was carried out for a total of 20 cases of acetabular fracture involving the posterior wall with age more than 18 years but less than 60 years attending the OPD and Emergency department of Orthopaedics, Gauhati Medical College & Hospital who met the inclusion and exclusion criteria outlined below. The study was conducted for a period of 18 months from 1st March 2016 to 31st August 2017. All the cases were followed up for a minimum period of six months.

### Inclusion Criteria

- Only those patients who gave informed consent and agreed for follow up.
- Age group- 18 to 60 years.
- Fracture of duration less than 21 days after obtaining haemodynamic stabilization and optimization of associated injuries.
- Posterior wall fracture of Elementary fractures and Posterior column with posterior wall and transverse with posterior wall fracture of Associated fractures confirmed by Clinical examination, X ray and CT scan.

### Exclusion Criteria

- Compound fractures of acetabulum.
- Associated lower limb fractures of long bones.
- Patients not fit for prolonged surgery and anaesthesia due to previous comorbid medical conditions.
- The patients which cannot be optimized due to major associated injury within 3 weeks of time.
- Pregnancy.
- Pathological fracture.

On admission, the general condition of the patient was assessed and other injuries were excluded. Basic resuscitative measures were taken as per the

Advanced Trauma Life Support (ATLS) guidelines. Posterior wall acetabular fracture if associated with dislocated femoral head, reduction with application of Thomas splint was done. Initial radiographs included Antero-Posterior view of pelvis. In all those patients who gave consent for operation, pre-operative anesthetic evaluation was done. For better understanding of fracture pattern and displacement Judet views (iliac and obturator oblique) of acetabulum were taken. CT scan with three dimensional reconstructions was done routinely to obtain detailed information about the fracture pattern. The level and pattern of fracture was determined and classified according to Judet and Letournel classification. Posterior wall fracture of Elementary fractures and posterior column with posterior wall and transverse with posterior wall fracture of associated fractures were included in the study.

### Indications for Surgery

1. Fracture with 2 mm or more of displacement traversing the dome of the acetabulum.
2. Posterior wall fractures with more than 50% involvement of the articular surface of the posterior wall with clinical instability of the hip when examined under anaesthesia with hip flexion to 90 degrees.

### Operative Procedure

The patients were placed in lateral position. The Kocher- Langenbeck approach where the acetabulum is approached posteriorly was used. Following dissection, the fracture was reduced with the help of pelvic reduction clamps. A 3.5 mm reconstruction plate was applied in buttress mode over the reduced posterior wall. It was first anchored to the ischium. The distal end of the plate was pre-contoured to fit the concavity at the base of the ischium. Next the proximal end was attached to the ilium. Depending on the age, fracture pattern, stability of fracture fixation, toe touching to partial weight bearing was allowed till first follow up (6 wks). Then unprotected full weight bearing was allowed after reviewing radiograph.

### Evaluation of Fracture Reduction in Post-Operative Radiographs

Fracture reduction was evaluated by measuring residual displacements on the three postoperative radiographs (antero-posterior and two 45° oblique Judet views) according to criteria developed by Matta.<sup>[13]</sup> According to this criteria postoperative reduction was graded as anatomical (0-1 mm of displacement), imperfect (2- to 3-mm of displacement) or poor (3-mm displacement). Follow up was carried out at 6, 12, 16, 24 weeks and then at two monthly intervals.

Evaluation of Functional and Radiological Results  
The clinical results were graded using Merle d'aubigne scale.<sup>[14]</sup> Patients functional assessment was performed based on these criteria: pain (6 points), walking (6 points), range of motion (6 points). The criteria for functional results were- Excellent-Score- 18

Good- Score- 15-17

Fair- Score- 13-14

Poor- Score- <13

Radiological assessment was done using Matta criteria.<sup>[13]</sup>

- Normal appearance of the hip is graded as excellent.
- Mild changes, small osteophytes, moderate (1mm) narrowing of joint and minimum sclerosis as good.
- Intermediate changes, moderate osteophytes, moderate (<50%) narrowing of joint and moderate sclerosis as fair.
- Advanced changes, large osteophytes, severe (>50%) narrowing of the joint, collapse or wear of the femoral head and acetabular wear as poor result.

### Statistical Analysis

Fisher's exact test was used to compare postoperative reduction quality with functional and radiological outcome at the time of final follow up and also to compare the functional with radiological outcome at the final follow-up.

## RESULTS

20 patients (Age >18 years and < 60 years) with acetabular fracture involving the posterior wall were managed with open reduction and internal fixation. The patients were followed up for a minimum of 6 months.

The observations in our study were as follows:

The youngest patient was of 22 years and the oldest was 52 years of age. The mean age was 35.5 years. The maximum numbers of cases were observed between 20-29 years.

### Type of Acetabular Fracture:

The Acetabular fractures were classified according to LETOURNEL AND JUDET classification system (1981). Only the Posterior wall fracture of Elementary Fractures and Posterior Column with Posterior wall and Transverse with Posterior wall fracture of Associated Fractures was taken in the study.

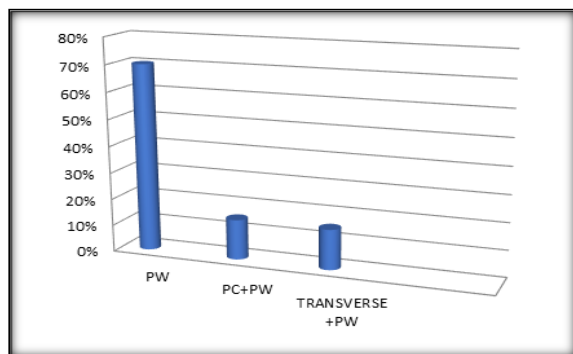


Figure 1: Type of Fracture

### Results According to Reduction

The reduction was anatomical in 16 (80 %). Anatomical reduction was achieved in only 66.33%

of complex injuries, compared 85.71% of simple injuries. The rate of anatomical reduction decreased with increase in complexity of fracture [Table 2].

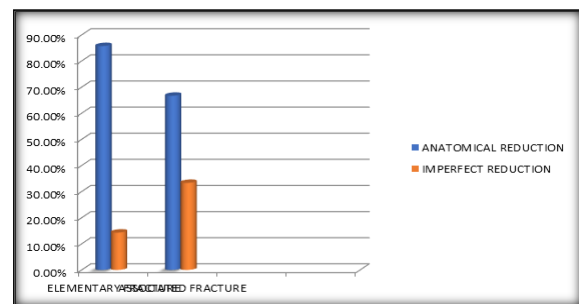


Figure 2: Results According to Reduction

### Relationship Between Quality of Reduction and Clinical Outcome

There are 16 (80%) cases of anatomical reduction out of 20. Out of which 4 (25%) had excellent, 9 (56.25%) had good, 2 (12.5%) had fair and 1 (6.25%) poor functional result. In the rest 4 cases with imperfect reduction, 3 (75%) had fair and 1 (25%) had poor functional result [Table 3].

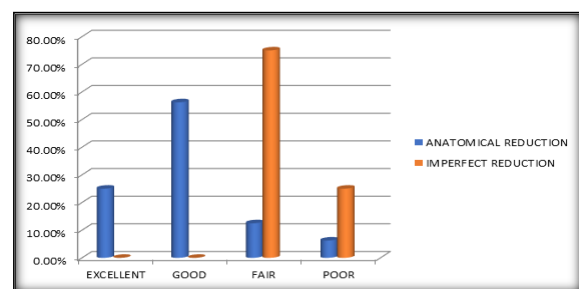


Figure 3: Relationship between quality of reduction and clinical outcome

The clinical outcome scores was found to be significant with a p-value of 0.0144 (using Fisher's exact test).

### Relationship Between Quality of Reduction and Radiological Outcome

There are 16 (80%) cases of anatomical reduction out of 20. Out of which 6 (37.5%) had excellent, 8 (50%) had good and 2 (12.5%) had fair radiological result. In the rest 4 cases with imperfect reduction 1 (25%) had good and 3 (75%) had fair radiological result [Table 4].

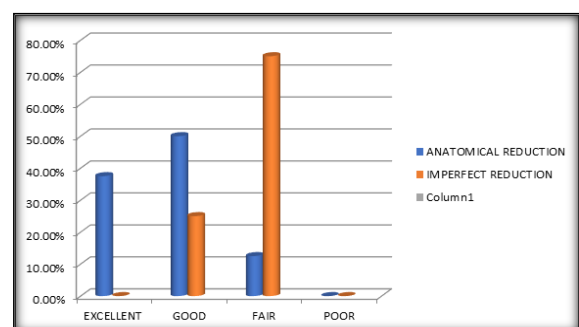


Figure 4: Relationship between quality of reduction and radiological outcome

The radiological outcome score was found to be significant with a p-value of 0.0320 (using Fisher's exact test).

**Table 1: Type of Fracture**

Fracture type		No of cases	Percentage
Elementary	Posterior wall	14	70%
Associated	Posterior column + wall	3	15%
	Transverse + posterior wall	3	15%
Total		20	100%

**Table 2: Results According to Reduction**

Fracture Type		No of cases	Anatomically reduced	Imperfect reduction
Elementary	Posterior wall	14	12	2
Associated	Posterior column + wall	3	2	1
	Transverse + posterior wall	3	2	1
Total		20	16 (80%)	4(20%)

**Table 3: Relationship between quality of reduction and clinical outcome**

Reduction	No of cases	Excellent	Good	Fair	Poor
Anatomic Reduction	16(80%)	4(25%)	9(56.25%)	2(12.5%)	1(6.25%)
Imperfect Reduction	4(20%)	-	-	3(75%)	1(25%)

**Table 4: Relationship between quality of reduction and radiological outcome**

Reduction	No of cases	Excellent	Good	Fair	Poor
Anatomical Reduction	16 (80%)	6 (37.5)	8 (50%)	2 (12.5)	-
Imperfect Reduction	4 (20%)	-	1 (25%)	3 (75%)	-

## DISCUSSION

Fractures of the acetabulum remain one of the most challenging fractures for the orthopaedic surgeon to understand and treat successfully. The goal of surgery is to restore accurately the anatomical configuration and stability of the hip, while avoiding complications.

### Type of Fracture

The Acetabular fractures were classified according to LETOURNEL AND JUDET classification system (1981). Only the Posterior wall fracture of Elementary Fractures and Posterior Column with Posterior wall and Transverse with Posterior wall fracture of Associated Fractures was taken in the study. There were 14 (70%) elementary fractures and 13 (30%) associated fractures in our study.

The following table shows a comparison of fracture types in our study with other series.

The following table shows a comparison of fracture types in our study with other series

Study (Years)	JUDET AND LETOURNEL CLASSIFICATION TYPE	
	Elementary fractures	Associated fractures
Hui Taek Kim et al. <sup>19</sup> (2011)	63.60%	34.60%
Lingayat M et al. <sup>18</sup> (2014)	87%	13%
Present Study	70%	30%

In our study, elementary posterior wall fracture constitutes 70% and in associated fractures, posterior column with posterior wall and transverse with posterior wall constitutes 15% each.

### Use of Operative Approach

In all our cases standard Kocher-Langenbeck approach is used. The standard Kocher-Langenbeck approach was used by Th. Pantazopoulos et al,<sup>15</sup> (1993), Moed BR et al,<sup>16</sup> (2000), P. V. Giannoudis et al,<sup>17</sup> (2006), Magu NK et al,<sup>7</sup> (2014) and Lingayat M et al,<sup>18</sup> (2014) for all their case in their respective studies. Moed BR et al,<sup>16</sup> (2000) and Magu NK et al,<sup>7</sup> (2014) used trochanter flip osteotomy in 3 of their respective case for better access to superior (weight bearing dome) fracture fragment.

Comparison between clinical and radiological results

In our study, functional outcome was excellent/good in 65% of the cases while radiological outcome was excellent/good in 75% of the cases. On comparing the relationship between clinical and radiological results, it was found to be statistically significant with a p-value of 0.0307 (using Fisher's exact test).

In the study of Moed BR et al,<sup>16</sup> (2000) and Magu NK et al,<sup>7</sup> (2014) radiographic congruency correlated well with functional scoring.

### Fracture Reduction

The reduction was anatomical in,<sup>16</sup> (80 %). Anatomical reduction was achieved in only 66.33% of complex injuries, compared 85.71% of simple injuries. This is comparable to the study of H. J. Kreder et al,<sup>20</sup> (2006) where anatomical reduction was achieved in only 68.2% of complex injuries, compared to 95.5% of simple injuries.



Study (Years)	ANATOMIC REDUCTION
Moed BR et al <sup>16</sup> (2000)	97.80%
H. J. Kreder et al <sup>20</sup> (2006)	84%
Hui TaekKimet al <sup>19</sup> (2011)	85%
Magu NK et al <sup>7</sup> (2014)	82%
Pascarella Ret al. <sup>21</sup> (2017)	95%
Present study	80%

### Relationship Between Quality of Reduction and Clinical Outcome:

There are 16 (80%) cases of anatomical reduction out of 20. Out of which 4 (25%) had excellent result, 9 (56.25%) had good result and 2 (12.5%) had fair results and 1 (6.25%) poor functional result. In the rest 4 (20%) cases with imperfect reduction, 3(75%) had fair and 1 (25%) had poor functional result. On comparing the relationship between quality of reduction and clinical outcome, it was found to be statistically significant with a p-value of 0.0144(using Fisher's exact test).

Pantazopoulos et al,<sup>[15]</sup> (1993), in their study reported that a close relationship was also seen between the quality of the reduction achieved at surgery and the clinical results, since all except three of the 40 cases with excellent reduction had an 'excellent' or 'very good clinical result.

Moed BR et al,<sup>[16]</sup> (2000) reported 92 (97.8%) cases of anatomical reduction out of 94 cases in their study of which 88% cases had excellent to good functional outcome.

Magu NK et al,<sup>[7]</sup> (2014) in their study reported 21 (82%) cases of anatomical reduction out of 25. Out of which 10 (40%) had excellent result, 8 (32%) had good result and 2 (8%) had fair results and 1 (4%) poor functional result.

In the study done by Pascarella Ret al<sup>[21]</sup> (2017), anatomical reduction was achieved in 95% of the cases, of which 86.8% of the cases had excellent to good functional outcome.

### Relationship Between Quality of Reduction and Radiological Outcome:

There are 16 (80%) cases of anatomical reduction out of 20. Out of which 6 (37.5%) had excellent, 8 (50%) had good and 2 (12.5%) had fair radiological result. In the rest

4 cases with imperfect reduction 1 (25%) had good and 3 (75%) had fair radiological result. On comparing the relationship between quality of reduction and radiological outcome, it was found to be statistically significant with a p-value of 0.0320 (using Fisher's exact test).

Pantazopoulos et al,<sup>[15]</sup> (1993), in their study found strict correlation between accurate reduction of the fracture and the clinical and radiological results, which were excellent or very good in 85 per cent and 87.5 per cent of the patients, respectively.

Magu NK et al,<sup>[7]</sup> (2014) in their study found that anatomic reduction leads to optimal long term functional and radiologic outcomes in patients with fractures of posterior acetabular wall.

Pascarella Ret al,<sup>[21]</sup> (2017) reported in their study that quality of surgical reduction were strong positive predictors of functional and radiographic outcomes at follow-up.

## CONCLUSION

Elementary and Associated posterior wall acetabular fractures may cause residual acetabular deformities contributing to the morbidity and decreased hip joint function. Previously these fractures were treated non-operatively leading to myriads of complications. Our study aimed at evaluating the outcome of operative management of these fractures.

Good reduction together with proper stabilization and as soon as the general condition of the patient permits allow early mobilization, prevents complications and thereby lead to a short hospital stay and to an early start of rehabilitation. Open reduction and internal fixation is the gold standard of displaced and unstable posterior wall acetabular fracture.

## REFERENCES

1. Magu, N. K., Rohilla, R. & Arora, S. Conservatively treated acetabular fractures: A retrospective analysis. Indian J. Orthop. 46, 36-45 (2012).
2. Ragnarsson, B., Jacobsson, B. & Ragnarsson, B. Acta Orthopaedica Scandinavica Epidemiology of pelvic fractures in a Swedish county Epidemiology of pelvic fractures in a Swedish county. Acta Orthop. Scand. Acta Orthop Scand 633, 297-300 (1992).
3. Guyton JL, P. E. Fractures of Acetabulum and pelvis chapter -56. In: Canale ST, Beaty JH, editors. Campbell's Operative Orthopaedics. 12th edition. VOL- 3.Philadelphia: Elsevier; .page- 2799-2800. (2007).
4. Shin, J. K., An, S. J., Go, T. S. & Lee, J. S. Analysis of Predictors of Results after Surgical Treatment of Acetabular Fractures. Hip pelvis 27, 104-9 (2015).
5. Kim, H. T., Ahn, J.-M., Hur, J.-O., Lee, J.-S. & Cheon, S.-J. Reconstruction of acetabular posterior wall fractures. Clin. Orthop. Surg. 3, 114-20 (2011).
6. Acetabular posterior wall fracture 38 cases followed for 5 years AJ Aho, UK Isberg, VK Katevuo - Acta Orthopaedica Scandinavica, 1986.
7. Magu, N. K. et al. Long term results after surgical management of posterior wall acetabular fractures. J. Orthop. Tratimatol. 15, 173-9 (2014).
8. Letournel E, Judet R. Fractures of the acetabulum. Second ed. Berlin: Sprtnger- Verlag, 1993.
9. Acetabulum - Diagnosis - Posterior wall - AO Surgery Reference. Available at: [https://www2.aofoundation.org/wps/portal/Jut/p/a/04\\_Sj9CPykssy0xPLMnMzOvMAfQjzOKN\\_AOM3D2DDbz9\\_UMMDRyDXQ3dw9wMDAzMjfuLshOVAbWjLW0!/?bone=Pelvis&classification=62-Posteriorwall&segment=Acetabulum&showPage=diagnosis&teaserTitle=Acetabulum - Posterior.](https://www2.aofoundation.org/wps/portal/Jut/p/a/04_Sj9CPykssy0xPLMnMzOvMAfQjzOKN_AOM3D2DDbz9_UMMDRyDXQ3dw9wMDAzMjfuLshOVAbWjLW0!/?bone=Pelvis&classification=62-Posteriorwall&segment=Acetabulum&showPage=diagnosis&teaserTitle=Acetabulum - Posterior.) (Accessed: 18th August 2017)

10. Anizar-Faizi, A., Hisam, A., Sudhagar, K., Moganadass, M. & Suresh, C. Outcome of Surgical Treatment for Displaced Acetabular Fractures. doi:10.5704/MOJ. 1411.001
11. Jong Ki Shin, MD, Sung Jin An, MD, Tae Sik Go, MD, Jung Sub Lee, MD, P. Analysis of Predictors of Results after Surgical Treatment of Acetabular Fractures Jong Ki Shin, MD, Sung Jin An, MD, Tae Sik Go, MD, Jung Sub Lee, MD, PhD Department of Orthopaedic Surgery, Pusan National University Hospital, Busan, Korea. *Hip Pelvts* 27(2) 104-109, 2015 [http//dx. dot. org/10.53 71 hp. 2015.27.2.104](http://dx. dot. org/10.53 71 hp. 2015.27.2.104)
12. Guyton JL, Perez EA. Fractures of Acetabulum and pelvis chapter -56. In: Canale ST, Beaty JH, editors. *Campbell's Operative Orthopaedics*, 12th edition. Philadelphia: Elsevier; 2007. Page.2785. tn.
13. Johnson, E. E., Matta, J. M., Mast, J. W. & Letoumel, E. Delayed reconstruction of acetabular fractures 21-120 days following injury. *Clin. Orthop. Relat. Res.* 20-30 (1994).
14. d'Aubigne, R. M. & Postel, M. The classic: functional results of hip arthroplasty with acrylic prosthesis. 1954. *Clin. Orthop. Relat. Res.* 467, 7-27 (2009).
15. Pantazopoulos, T., Nicolopoulos, C. S., Babis, G. C. & Theodoropoulos, T. Surgical treatment of acetabular posterior wall fractures. *Injury* 24, 319-323 (1993).
16. Moed, B. R., Carr, S. E. W. & Watson, J. T. Open Reduction and Internal Fixation of Posterior Wall Fractures of the Acetabulum. *Clin. Orthop. Relat. Res.* 377, 57-67 (2000).
17. Giaimoudis, P. V., Tzioupis, C. & Moed, B. R. Two-level reconstruction of comminuted posterior-wall fractures of the acetabulum. *J. Bone Ji. Surg. - Br. Vol. 89-B*, 503-509 (2007).
18. Lingayat, M. B. Outcome of open reduction and internal fixation of fractures of posterior acetabulum. *Indian J. Basic Appl. Med. Res.* 3, 308-314 (2014).
19. Kim, H. T., Ahn, J.-M., Hur, J.-O., Lee, J.-S. & Cheon, S.-J. Reconstruction of acetabular posterior wall fractures. *Clin. Orthop. Surg.* 3, 114-20 (2011).
20. Kreder, H. J. et al. Determinants of functional outcome after simple and complex acetabular fractures involving the posterior wall. *J. Bone Jt. Surg. - Br. Vol. 88-B*, 776-782 (2006).
21. Pascarella, R. et al. Surgical results and factors influencing outcome in patients with posterior wall acetabular fracture. *Injury* 48, 1819-1824 (2017).