

## CONSERVATIVE MANAGEMENT OF SPONTANEOUS CHYLOTHORAX IN INFANTS

Pawan Rao Ambatpalli<sup>1</sup>, Anil Balraj<sup>2</sup>

<sup>1</sup>Assistant Professor, Department of Pediatric Surgery, Kakatiya Medical colleges / M.G.M hospital, Warangal, Telangana, India.

<sup>2</sup>Professor & HOD, Department of Pediatric Surgery, Kakatiya Medical colleges / M.G.M hospital, Warangal, Telangana, India.

Received : 25/11/2022  
Received in revised form : 30/12/2022  
Accepted : 11/01/2023

**Keywords:**  
Spontaneous chylothorax, pleural effusion, octreotide.

Corresponding Author:  
**Dr. Pawan Rao Ambatpalli,**  
Email: drpawanraoambatpalli@gmail.com  
ORCID: 0000-0002-9836-9433

DOI: 10.47009/jamp.2023.5.1.84

Source of Support: Nil,  
Conflict of Interest: None declared

*Int J Acad Med Pharm*  
2023; 5 (1); 407-410



### Abstract

**Background:** Spontaneous chylothorax is the most common cause of pleural effusion in the perinatal period. The etiology is unknown in the majority of the cases. However, in some cases, it can be associated with various syndromes and genetic conditions. The aim is to evaluate the role of octreotide in the management of spontaneous chylothorax. **Materials and Methods:** All patients who presented with spontaneous chylothorax to the department of Pediatric Surgery 5 infants were included in the study, those patients who had chylothorax due to any other pathology or post operatively were excluded from the study. Octreotide was given subcutaneously for all patients at a dose of 40 microgram/kg/day in 3 divided doses. Octreotide was stopped once the ICD output was less than 70-80 ml/day. ICD was inserted in all patients and removed once drainage was below 50 ml/day. **Result:** In present study 5 patients, 3 of whom were males and 2 of whom were females. Respiratory distress was seen in each of the 5 patients. All chest radiographs were taken, and 4 of the patients had large pleural effusions on the left side and 1 on the right. A milky white fluid was aspirated from the fluid and sent for biochemical testing. Triglycerides and chylomicrons, which are pathognomonic of chylothorax, were present in the fluid. Total parenteral nutrition was given to the patients to meet their caloric needs while they were kept nil by mouth. Once the diagnosis was made, octreotide was administered to all patients. Octreotide was administered subcutaneously in 3 separate doses at a rate of 40 micrograms/kg/day. Once the drain output was less than 50 ml per day, the chest drains were removed. All of the patients made full recovery and were discharged. The average age of presentation was 6.4 months. Average number of days a patient was kept nil per oral was 13 days. Octreotide was administered for an average of 14.2 days (8-23 days). The average duration of ICD was 19 days. **Conclusion:** Early diagnosis and intervention favours good outcome. Conservative management is usually successful. Early institution of oral feeds with octreotide preserves the child's nutrition.

## INTRODUCTION

Spontaneous Chylothorax is rare in children with incidence not known. Chylothorax is accumulation of chyle in pleural cavity due to injury to thoracic duct. In children, it is most commonly seen as a complication of cardiothoracic surgery. It can cause significant respiratory morbidity, as well as lead to malnutrition and immunodeficiency.<sup>[1,2]</sup> It can be unilateral or bilateral in origin secondary due to trauma.<sup>[2]</sup> The incidence of chylothorax in neonates is one in 20,000 live births with a mortality rate of 64%.<sup>[3]</sup> This trauma can be a result of thoracic or cardiovascular surgery, and in some patients, it is associated with lymphangiomatosis. The right lung

is more frequently involved and clinically, the patient presents with respiratory distress and diminished breath sounds on the affected side.<sup>[4]</sup> The prognosis is usually favorable; however, resolution can be protracted in severe cases with treatment depending upon the size and amount of the collected chyle. Octreotide was found to be effective in 53.6% of cases with no difference between preterm and term neonates. In recent years, octreotide, a synthetic analog of somatostatin, has been used in the management of acquired chylothorax. The proposed mechanism of octreotide and somatostatin for chylothorax is that they block lymph flow in the thoracic duct through exerting effects on both splanchnic circulation and gastrointestinal motility.

In addition, octreotide reduces hepatic venous pressure, intestinal lipid absorption, chyle concentrations in the thoracic duct, and splanchnic blood flow.<sup>[4]</sup> In comparison to somatostatin, octreotide has a longer half-life, greater potency, and the option of subcutaneous administration.<sup>[5,6]</sup> Either drug can be given as a continuous intravenous infusion or as an intravenous bolus twice daily. According to the 1999 Guidelines for Diagnosis and Management of Chylothorax in Children, the recommended treatment strategy is not fully established, and octreotide was not mentioned. However, several proposed treatment algorithms have suggested consideration of octreotide if chylothorax persists despite TPN or with TPN if patients have high volume drainage (>20 mL/kg/day).<sup>[4]</sup> In a prospective study conducted by Rosti et al,<sup>[7]</sup> octreotide was found to be more effective than conventional therapy for the treatment of chylothorax in pediatric patients following cardiac surgery. Patients who received octreotide had significantly reduced total fluid losses, duration of chest tube use, and postoperative length of stay. Paramés et al,<sup>[8]</sup> also published a retrospective study that demonstrated similar results for octreotide use in chylothorax. We report 5 neonate with spontaneous chylothorax successfully treated with continuous administration of octreotide.

## MATERIALS AND METHODS

All patients who presented with spontaneous chylothorax to the department of Pediatric Surgery, KMC/MGM Hospital from 2020-2022. A case series of these patients was done. All infants with spontaneous chylothorax were included in the study, those patients who had chylothorax due to any other pathology or post operatively were excluded from the study. All patients were nil per oral initially. Orals were resumed once the ICD output declined.

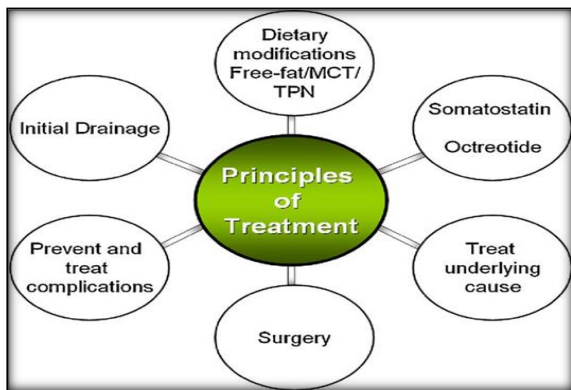
Octreotide was given subcutaneously for all at 40 microgram/kg/day in 3 divided doses. Octreotide was stopped once the ICD output showed declining trends and less than 70-80 ml/day. ICD was inserted in all patients and removed once drainage was below 50ml/ day.

## RESULTS

Over a three-year period, chylothorax was found in 5 patients, 3 of whom were males and 2 of whom were female infants. Respiratory distress was seen in each of the 5 patients. All chest radiographs were taken, and 4 of the patients had large pleural effusions on the left side and 1 on the right. A milky white fluid was aspirated from the fluid and sent for biochemical testing. Triglycerides and chylomicrons, which are pathognomonic of chylothorax, were present in the fluid. In order to alleviate the patients' respiratory distress, a chest drain was inserted, and extra oxygen was administered to them. Every day, the output of the chest drain was measured. Total parenteral nutrition was given to the patients to meet their caloric needs while they were kept nil by mouth. Once the diagnosis was made, octreotide was administered to all patients. Octreotide was administered subcutaneously in 3 separate doses at a rate of 40 micrograms/kg/day. The octreotide was continued until the output of the chest drain fell to less than 70 ml per day. The response was then documented after starting oral feeding. The output of chyle did not rise again. Once the drain output was less than 50 ml per day, the chest drains were removed. All of the patients made full recovery and were discharged. The average age of presentation was 6.4 months. Average number of days a patient was kept nil per oral was 13 days. Octreotide was administered for an average of 14.2 days (8-23 days). The average duration of ICD was 19 days.

**Table 1: Details of 5 cases in present study**

AGE	SEX	SIDE	Nil by mouth	Number of days octreotide was administered	Number of days drain in place
2 month	Female	Left	9 days	10 days	14 days
4 months	Male	Left	8 days	12 days	17 days
5 months	Male	Left	23 days	22 days	25 days
9 months	Female	Right	6 days	8 days	12 days
1 year	Male	Left	18 days	19 days	27 days



## DISCUSSION

Congenital chylothorax is rare and was first reported in 17th century. It is a common cause of neonatal pleural effusion. Trauma and post cardiothoracic surgery are considered as cause, but in newborn, it is commonly associated with lymphatic malformation like lymphangiectasia, infections including congenital cytomegalovirus, adenovirus, streptococcus, congenital goiter, aneuploidy like Turner and Down syndrome, Noonan syndrome and malignancies.<sup>[9,10]</sup>

**The characteristics of pleural chylous fluid are as follows:** triglyceride >100 mg/dl, protein >20 g/L, cells >100 per ml with lymphocytosis, cholesterol 65-220 mg/dl. High triglyceride level and lower cholesterol level differentiate true chylothorax from pseudochylothorax. Pleural fluid is sterile on culture. We had a similar findings. Congenital chylothorax was associated with high morbidities and mortality (50%) particularly in preterm and low birth weight babies (2.7), few cases also show spontaneous resolution.<sup>[11]</sup>

We postulate that earlier initiation of octreotide could have potentially shortened the duration of chylothorax. Though there are multiple studies with unclear benefits of octreotide multiple case reports and case serie demonstrated octreotide's effectiveness in treating chylothorax.<sup>[12,13]</sup> Some authors even suggested using octreotide as first-line therapy. Chan et al,<sup>[14]</sup> reported high success rate of octreotide therapy in 15/18 (83%) patients with chylothorax after cardiac surgery. However, treatment was initiated at a mean of 19.5 days after onset, which is much later in the course than this study. Statistical analysis provided similar results and suggested a potential benefit of octreotide use in chylothorax. If effective, the addition of octreotide to chylothorax management may potentially avoid more invasive therapies. However, if ineffective it may also potentially prolong the time until more definitive invasive therapies are performed thus potentially prolonging hospital stays. More controlled studies to investigate octreotide's role in chylothorax management are imperative. However, based on this study's analysis, we recommend initiating octreotide if drainage is above 40

mL/kg/day or if it fails to fall below 20 mL/kg/day by day 7.

A systematic literature review by Helin et al,<sup>[15]</sup> analyzed the use of octreotide for chylothorax in infants and children. The authors concluded that octreotide is relatively safe, even at very high doses and for as long as 3 weeks. In addition, initiating therapy early and using higher initial doses (3.3–4.2 mcg/kg/hr) rather than using a low initial dose with upward titration may reduce fluid and electrolyte complications of chylothorax, and may enable earlier removal of thoracostomy tubes. No consensus has been reached as to the optimal route of administration, dose, duration of therapy, or strategy for discontinuation of therapy.

In contrast to previous findings, the 2002 case report by Mikroulis et al,<sup>[16]</sup> detailed the use of octreotide for chylothorax after left pneumonectomy. They did not observe reduction in drainage, and octreotide was deemed to be ineffective for chylothorax treatment after a week of therapy. Church et al,<sup>[17]</sup> conducted a retrospective study to develop an evidence-based algorithm for chylothorax management. Authors concluded that octreotide has no advantage compared with TPN alone in infants with chylothorax.

From a safety standpoint, side effects of octreotide include hyperglycemia, hypothyroidism, cramps, nausea, diarrhea, renal impairment, and liver dysfunction. In addition, Mohseni-Bod et al<sup>[18]</sup> reported a possible link between postoperative chylothorax treated with octreotide and necrotizing enterocolitis (NEC) in an infant following aortic coarctation repair. The authors suggested that octreotide should be limited to patients with stable hemodynamic findings without recent history of compromised splanchnic perfusion.

Chylothorax can cause significant respiratory morbidity, as well as lead to malnutrition and immunodeficiency. Thus, the prompt initiation of chylothorax management could decrease morbidity, mortality, and improve quality of life in cardiac ICU patients. Literatures regarding the use of octreotide in acquired chylothorax after congenital heart surgery are sparse and have shown contradicting results.

Roehr et al,<sup>[19]</sup> performed a systematic literature review of the use of somatostatin and octreotide in 35 children with primary or secondary chylothorax. Most studies reported a significant decrease in chylous drainage within 5 to 6 days of starting octreotide or somatostatin. The use of octreotide in 20 neonates with chylothorax was described in a 2010 Cochrane report. Fourteen of the case reports described successful resolution of chylothorax, reported no resolution, and 1 reported equivocal results. No practice recommendation was made based on this evidence. Horvers et al,<sup>[12]</sup> reported on the use of octreotide in 7 patients with congenital chylothorax. Administration of 5 to 6 mg octreotide/kg per minute lead to a decrease in pleural effusions in all patients, but that decrease

might have been the natural history of congenital chylothorax and, hence, no clear, consistent effect of octreotide was identified. They noted that pulmonary hypertension was a common problem in the patient group.<sup>[6]</sup> Other agents used in the treatment of chylothorax include nitric oxide and etilefrine.

The limitation of this study was the small number of cases studied and larger studies were required for better understanding of the effects of octreotide in treatment of spontaneous chylothorax in infants.

## CONCLUSION

Spontaneous chylothorax is rare in infants. Conservative management is usually successful. Early institution of oral feeds with octreotide preserves the child's nutrition. There is an unmet need for curation of guidelines that consider a multidisciplinary approach for appropriate management of the condition. Further studies are needed to ascertain the etiology of neonatal chylothorax.

## REFERENCES

1. Chylothorax: aetiology, diagnosis and therapeutic options. McGrath EE, Blades Z, Anderson PB. *Respir Med.* 2010;104:1–8.
2. Congenital chylothorax: a unique presentation of nonimmune hydrops fetalis in a preterm infant. Brock WW, Bradshaw WT. *Adv Neonatal Care.* 2016;16:114–123.
3. Neonatal chylothoraces: A 10-year experience in a tertiary neonatal referral centre. White MK, Bhat R, Greenough A. *Case Rep Pediatr.* 2019;2019:3903598.
4. Congenital chylothorax: associations and neonatal outcomes. Downie L, Sasi A, Malhotra A. *J Paediatr Child Health.* 2014;50:234–238.
5. Helin RD, Angeles ST, Bhat R. Octreotide therapy for chylothorax in infants and children: a brief review. *Pediatr Crit Care Med.* 2006;7(6):576–579.
6. Panthongviriyakul C, Bines JE. Post-operative chylothorax in children: an evidence-based management algorithm. *J Paediatr Child Health.* 2008;44(12):716–721.
7. Rosti L, De Battisti F, Butera G et al. Octreotide in the management of postoperative chylothorax. *Pediatr Cardiol.* 2005;26(4):440–443.
8. Paramés F, Freitas I, Fragata J et al. Octreotide-additional conservative therapy for postoperative chylothorax in congenital heart disease. *Rev Port Cardiol.* 2009;28(7–8):799–807.
9. Soto-Martinez M, Massie J. Chylothorax: diagnosis and management in children. *Paediatr Respir Rev.* 2009;10:199–207.
10. Doerr CH, Miller DL, Ryu JH. Chylothorax. *Semin Respir Crit Care Med.* 2001;22(06):617–26.
11. St-Onge MP, Jones PJ. Physiological effects of medium-chain triglycerides: potential agents in the prevention of obesity. *J Nutr.* 2002;132:329–32.
12. Horvers M, Mooij CF, Antonius TA. Is octreotide treatment useful in patients with congenital chylothorax? *Neonatology.* 2012;101(3):225–231.
13. White SC, Seckeler MD, McCulloch MA et al. Patients with single ventricle anatomy may respond better to octreotide therapy for chylothorax after congenital heart surgery. *J Card Surg.* 2014;29(2):259–264.
14. Chan EH, Russell JL, Williams WG et al. Postoperative chylothorax after cardiothoracic surgery in children. *Ann Thorac Surg.* 2005;80(5):1864–1871.
15. Helin RD, Angeles ST, Bhat R. Octreotide therapy for chylothorax in infants and children: a brief review. *Pediatr Crit Care Med.* 2006;7(6):576–579.
16. Mikroulis D, Didilis V, Bitzikas G et al. Octreotide in the treatment of chylothorax. *Chest.* 2002;121(6):2079–2080.
17. Church JT, Antunez AG, Dean A et al. Evidence-based management of chylothorax in infants. *J Pediatr Surg.* 2017;52(6):907–912.
18. Mohseni-Bod H, Macrae D, Slavik Z. Somatostatin analog (octreotide) in management of neonatal postoperative chylothorax: is it safe? *Pediatr Crit Care Med.* 2004;5(4):356–357.
19. Roehr CC, Jung A, Proquitté H et al. Somatostatin or octreotide as treatment options for chylothorax in young children: a systematic review. *Intensive Care Med.* 2006;32(5):650–657.