

TUMOR INFILTRATING CD8 LYMPHOCYTES IN ADVANCED RENAL CELL CARCINOMA CASES – AN IMMUNOHISTOCHEMISTRY STUDY

Deepika Chandrasekaran¹, Balamurugan TD², Sandhya Sundaram³, Padmavathi. R⁴

Received : 28/11/2022
Received in revised form : 08/01/2023
Accepted : 25/01/2023

Keywords:

Renal cell carcinoma, Immunohistochemistry, Cluster Differentiation 8, Tumor microenvironment.

Corresponding Author:

Dr. Deepika Chandrasekaran,
Email: deepuchand15@gmail.com.

DOI: 10.47009/jamp.2023.5.1.215

Source of Support: Nil,
Conflict of Interest: None declared

Int J Acad Med Pharm
2023; 5 (1); 1036-1041



¹Department of Physiology, MAHER, Kanchipuram, Tamilnadu, India.

²Assistant Professor, Department of Surgical Oncology Govt. Arignar Anna Memorial Cancer Hospital and Research Institute, Regional Cancer Centre, Kanchipuram, Tamilnadu, India.

³Department of Pathology, SRMC & RI, SRIHER, India.

⁴Department of Physiology, SRMC & RI, SRIHER, India.

Abstract

Background: Renal cell carcinoma (RCC) is considered as an immunogenic tumor consisting of abundant tumor infiltrating lymphocytes (TILs). Many studies have proved its strong ability to inactivate the host antitumor immunity system. Understanding the immune escape mechanism of RCC might pave the way towards new immunotherapies. The composition of the tumor microenvironment (TME) being heterogeneous among patients and tumor types is becoming a robust tool to predict postsurgical recurrence and death. **Objective:** To study the expression of CD8 cells in renal tumor tissue and adjacent normal tissue in renal carcinoma cases. **Materials and Methods:** This retrospective study was conducted after obtaining the ethical clearance from SRIHER ethics committee. Histopathologically proven 150 RCC cases were chosen from the Pathology department during the period of Jan 2010 to Sep 2018. The CD8 expression within the tumor tissue was assessed using biotin streptavidin immunoperoxidase method. CD8 low RCCs (positive cells <25%) and CD8 high RCCs (positive cells >25%) were observed. **Statistical Analysis:** Chi-squared tests and Fischer exact tests were done to compare the distribution of the sub categories among high CD8 RCC cases. The receiver operating characteristic curve (ROC) was plotted to assess the sensitivity of CD8. **Results:** 41 % of the RCC cases expressed CD8 tumor infiltrating lymphocytes. CD8 infiltration was increased in the sarcomatous subtype (p=0.009) of RCC. Increased CD8 expression was seen in high grade (p=0.001) and advanced stage (p=0.001) RCC. In ROC curve analysis AUC for advanced stage=0.84 and the AUC for high grade=0.81. This clearly states the role of immunotherapy in advanced RCCs. **Conclusions:** The Immune mediators in the TME such as CD8 cells have a prognostic value to complement the TNM staging system and provide potential information for designing RCC therapy.

INTRODUCTION

GLOBOCCAN 2018 statistics show us that 87% of Kidney Cancers are Renal Cell Carcinomas. It is the 9th common malignancy in men and 14th common in women.^[1] The tumor microenvironment (TME) is an intricate and dynamic ecosystem containing the tumor, immune cells, fibroblasts, blood, and lymphatic vessels. One of the mechanisms by which RCC limits the formation of immune synapse is through the upregulation of programmed death-1 ligand (PD-L1).^[2] The 5-year survival for kidney cancer is 74.5%; while 65.2% of kidney cancers are diagnosed at the local stage, the 5-year survival for localized kidney cancer is 92.6%.^[3] Even when curative surgery is performed for localized RCC

patients, 20–30% experience recurrence or metastasis. The density and composition of the immune microenvironment is heterogeneous among patients and tumor types, and it is becoming a robust tool to predict postsurgical recurrence and death of various cancers.^[4]

The predictable prognosis for RCC after radical nephrectomy is based on the American Joint Committee on Cancers (AJCC), tumor-node-metastasis staging (TNM) system. Other variables include Fuhrman nuclear grade, necrosis and Eastern Cooperative Oncology Group (ECOG) score. The University of California Los Angeles Integrated Staging System (UISS), provided a risk stratification tool for localized RCC after combining all the variables.^[5] However the accuracy was still not

complete as it failed to include the host immune response, which is plays a major role in tumor progression.

Many studies have suggested that RCC being an immunogenic tumor and the presence of TILs in the subsets of RCC could be associated with prognosis. Disease progression in cancer patients is not only decided by the histologic and molecular features but also by host immune response.^[6] The presence of Cluster Differentiation 8 (CD8) cells in triple-negative and HER2 breast tumor cases prior to the commencement of neoadjuvant chemotherapy was found to predict the response to therapy. Studies in gastric cancer have shown that TILs may direct the patient selection for immunotherapy or checkpoint inhibitor therapy.^[7,8]

The emergence of immune checkpoint inhibitors has fuelled the interest in TILs as these cells are the biological engine underpinning this therapy. In the recent years, many researchers are interested in studying the presence of TILs especially CD8 cells and the mechanisms interfering their actions.^[9] The tumor infiltrating CD8 cells are unable to destroy the tumor as they are primed by the antigens expressed by tumors and hence become inactivated in the TME. This results in failure to control tumor progression. Many clinical trials are going on in the field of targeting the mechanisms favouring anti-CD8 functions. These indicate the role of CD8 cell manipulation becoming a potential tool in certain cancers.^[10]

Aim:

Our study aims to assess the expression of immune mediators - Cluster Differentiation 8 (CD8) in renal tumor tissue and the adjacent normal tissue in RCC patients.

MATERIALS AND METHODS

This retrospective study was conducted after obtaining the ethical clearance from SRIHER ethics committee. Initially all RCC patients admitted for nephrectomy during the period January 2010 to September 2018 in Sri Ramachandra Medical College Hospital were chosen. Finally, histopathologically proven 150 RCC cases were included in the study. The corresponding paraffin tissue blocks were selected carefully. The details of the cases included in the study were acquired from medical records department. WHO-ISUP grading system was used to grade the tumor and TNM staging system for staging the tumor.

Biotin Streptavidin Immunoperoxidase Immunohistochemistry method was performed to analyse the CD8 expression within the tumor tissue. Tissue blocks were sliced (4um thick) and fixed to a glass slide. The slide was then dewaxed and hydrated after which hydrogen peroxide was added. The slide was thoroughly rinsed in phosphate buffer saline and citrate buffer was added to it. It was then allowed to cool and again rinsed with phosphate buffer. CD8

mouse monoclonal antibody [CD8- α (C8/144B):sc-53212; Santacruz, 1:100 dilutions] was used for immunostaining. CD8 antibody was added to the slide in drops and overnight incubation at 4°C was followed. After rinsing with phosphate buffer DAB was added to visualize the main antibody. The slides were then counterstained with eosin and hematoxylin stains, dehydrated and sealed. The slide was now focused under x200 magnification. The cell membrane of the CD8 cells were brown stained indicating the presence of CD8 infiltrating tumor cells (Tom Donnem et al 2015).^[11] Then scoring was done to assess the expression of CD8 cells.

By light microscopy, the tissue sections were scored for the degree of infiltration of CD8 lymphocytes. The percentages of CD8 lymphocytes compared with the total amount of nucleated cells in the stromal compartments were assessed. Based on experiences from one of the previous studies, scoring cut off points at 5%, 25%, or 50% for each core according to the degree of cell densities were used in the training set (Tromso cohort): 0% to 5% = 0, 5% to 25% = 1, 25% to 50% = 2, and more than 50% = 3. Scores 0, 1 were considered as CD8 low RCCs (positive cells <25%) as shown in figure 2. Scores 2 and 3 were considered as CD8 high RCCs (positive cells >25%) as shown in figure 1.^[12]

Statistical Analysis

To compare the expression of CD8 with the tumor characteristics we used Chi-squared test and Fisher Exact test. R software was used for the analysis. pvalue <0.05 were considered statistically significant. Receiver operating characteristic curve (ROC) for assessing the sensitivity of CD8 as a potential marker for advanced stage and high-grade RCC was also used for the analysis.

RESULTS

Table 1 shows the baseline factors of the study subjects. 61 (41%) RCC cases expressed high CD8 count and 89 (59%) cases showed low CD8 count. The classical histological subtypes of RCC are clear cell (ccRCC), papillary, chromphobe, collecting duct and sarcomatous. Graph 1 explains the distribution of High CD8 count in the various subsets of RCC especially the sarcomatous type (100%). Graph 2 and Graph 3 explain the distribution of high CD8 count among the high grade RCCs and the advanced stage RCCs. Table 2, clearly shows us that the presence of high CD8 is significantly associated with the high grade and advanced stage RCCs. The ROC curve has shown in figure 4 the potential role of CD8 as a distinguishing factor for advanced stage and high grade RCCs. The curve for the advanced stage showed area under the curve [AUC] = 0.84 and the curve for high-grade showed AUC = 0.81. Hence, elevated CD8 can become a worthy marker for advanced RCCs.

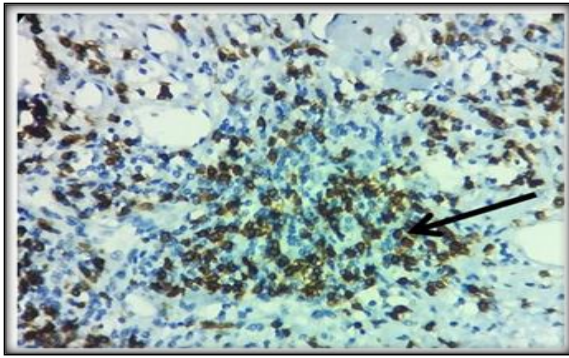


Figure 1: Immunohistochemical staining showing strong membranous positivity of CD8 cells infiltrating the tumor tissue (X200) with a score = 3 (70% cells) – High CD8

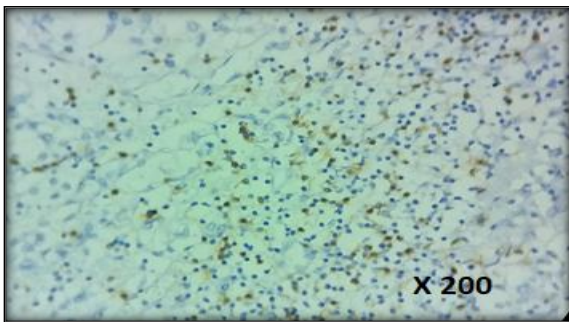


Figure 2: Immunohistochemical staining showing weak membranous positivity of CD8 cells infiltrating the tumor tissue (X200) with a score=1 (20% cells) – Low CD8

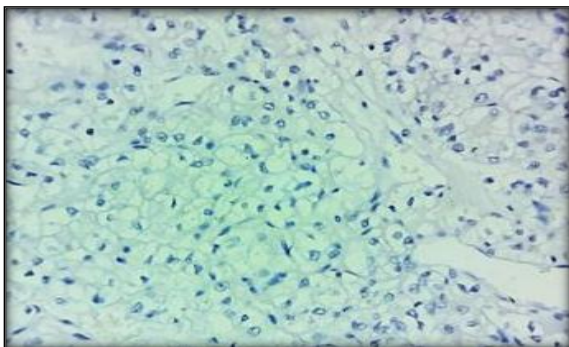
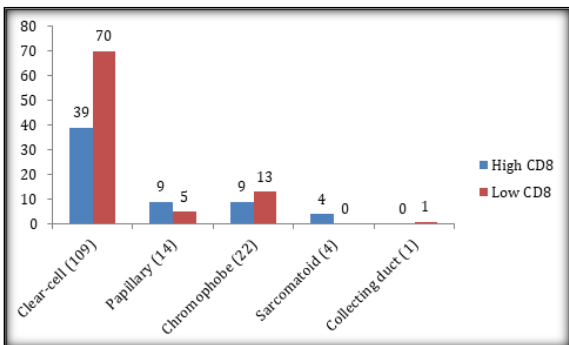
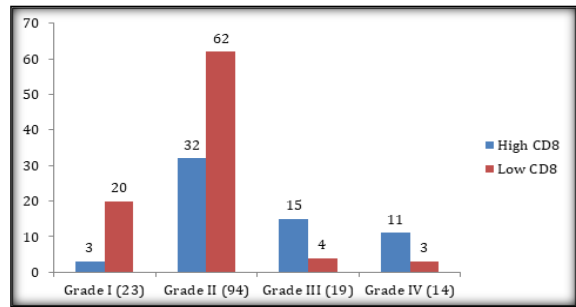


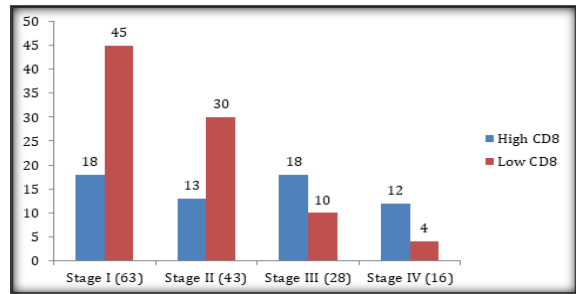
Figure 3: Immunohistochemical staining showing absence of CD8 cells infiltration in the tumor tissue, score=0



Graph 1: Distribution of high CD8 cases among the various subtypes of RCC. Sarcomatoid subtype (100%) of RCC expressed more CD8 cells



Graph 2: Distribution of high CD8 cases among the various grades of RCC. High grade RCCs (grade III-79%; grade IV-78.5%) expressed more CD8 cells



Graph 3: Distribution of high CD8 cases among the various stages of RCC. Advanced stage RCCs (stage III-64%; stage IV-75%) expressed more CD8 cells

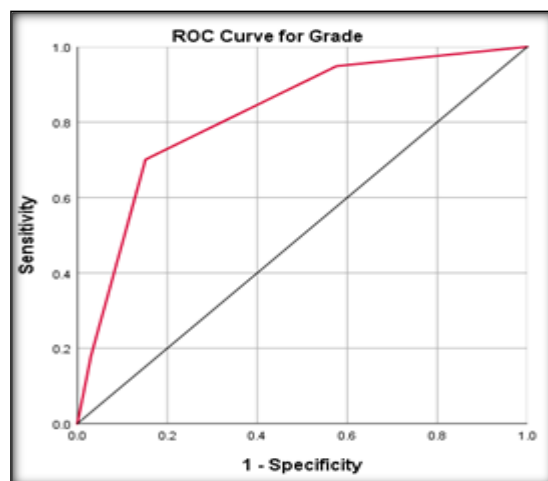
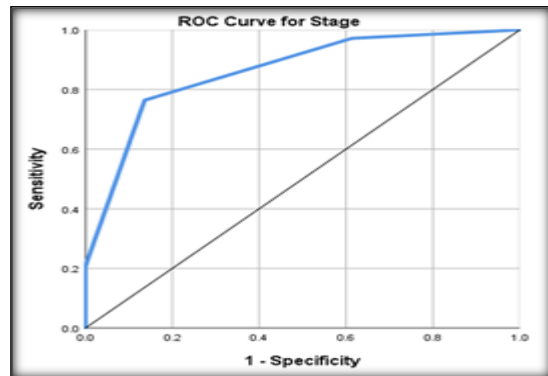


Figure 4: ROC analysis for advanced stage (a) and high grade (b) RCCs. The curve for the advanced stage showed area under the curve [AUC] = 0.84 and the curve for high-grade showed AUC = 0.81.

Table 1: Baseline Parameters of the study

Characteristics	Number of patients n(%)
Gender	
Males	111(74%)
Females	39(26%)
Age	
<=50yrs	47(31.3%)
>50yrs	103(68.7%)
Histology	
Clear cell	109(72.7%)
Papillary	14(9.3%)
Chromophobe	22(14.7%)
Collecting duct	1(0.7%)
Sarcomatoid	4(2.7%)
Grade	
I	23(15.3%)
II	94(62.7%)
III	19(12.7%)
IV	14(9.3%)
Stage	
I	63(42%)
II	43(28.7%)
III	28(18.7%)
IV	16(10.7%)
Age , years (mean±SD)	54 ± 12.43

Table 2: CD8 expression and the Clinical and pathologic features of Renal cell carcinoma patients

Parameters (n)	High CD8 61 (41%) n (%)	Low CD8 89 (59%) n (%)	p value
Age at surgery*			
<=50 (47)	16(26%)	31(35%)	0.264
>50 (103)	45(74%)	58(65%)	
Gender*			
Males (111)	51 (84%)	60(67%)	0.0263
Females (39)	10(16%)	29(33%)	
Sub-types*			
Clear-cell (109)	39 (64%)	70(79%)	0.009
Papillary (14)	9(15%)	5(6%)	
Chromophobe (22)	9(15%)	13(14%)	
Sarcomatoid (4)	4(6%)	0	
Collecting duct (1)	0	1(1%)	
Grade *			
I (23)	3(5%)	20(23%)	0.001
II (94)	32(52%)	62(70%)	
III (19)	15(25%)	4(4%)	
IV (14)	11(18%)	3(3%)	
Stage*			
I (63)	18(30%)	45(50%)	0.001
II (43)	13(21%)	30 (34%)	
III (28)	18(29%)	10(11%)	
IV (16)	12(20%)	4(5%)	

* Chi-squared tests and Fischer exact tests were done to compare the distribution of the parameters among the high CD8 RCC cases. pvalue <0.05 were considered statistically significant.

DISCUSSION

41 % of the RCC cases expressed CD8 tumor infiltrating lymphocytes. TILs form an ecosystem in the tumor microenvironment regulating cancer progression and have shown potential prognostic value. TILs (CD8cells) are the most widely studied populations among the Tumor Infiltrating Immune Cells. Cytotoxic CD8+ T cells can target the antigenic tumor cells to prevent their growth. A high level of activated CD8+ T cells is associated with prolonged prognosis in many cancers, including RCC.^[13]

Although the advent of targeted therapies has significantly improved survival in patients with

metastatic RCC in the past decade, the efficacy of these new drugs is limited in patients with sarcomatoid RCC (sRCC), as these patients experience the worst outcomes.^[14] In our study, the high CD8 expression was significantly associated with the aggressive subtype of RCC – the sarcomatoid RCC. This shows us that the CD8 cells could be helpful in deciding the treatment protocol for such cases.

Also the high grade and advanced stage RCC cases showed a significant increase in the CD8 cells compared to the early stages and grades of RCC. This very clearly states the role of immunotherapy in advanced RCC cases. Study conducted by Laurence

C. Menard., et al 2018 also stated the similar results.^[15]

The role of TILs in RCC is controversial as compared to breast and colorectal cancers. Although most studies of solid tumors found a positive correlation between the number of TILs and good prognosis, other studies have shown that high density of CD8+ TILs is correlated with poor outcome in RCC. Some studies of RCC indicate that lymphocytes within the tumor are dysfunctional, non-proliferative, and incapable of complete tumor destruction.^[16] Unfortunately these CD8 cells become ineffective while attempting to destroy the tumor. Few genetic studies have been conducted to profile the intra tumoral CD8 cells and understand the reason behind why these cells inspite of getting primed by the tumor antigen have failed to accomplish the tumor elimination. They have found the answer finally and it is because these immune mediators become inactivated in the tumor microenvironment.^[17] Thus lymphocytic infiltration into the tumor tissue does not specify the anti tumor immune response as their actions is curtailed by the aggressiveness of tumor. Our study showed the high expression of CD8 cells among the aggressive subtypes and the high grade, advanced stage RCCs which is consistent with Remark et al. (2013) who concluded that increase in intratumoral T cells was associated with advanced RCCs.^[18] This discrepancy in lymphocytic infiltration was concordant with previous studies. It could be attributed to the difference in cancer cells immunogenicity in each type.^[19]

The composition of TIIC differs greatly among the various subtypes, grades and stages of RCC. These differences may be important determinants for prognosis. The importance of immune infiltration for prognosis has been recognized. In colon cancer, immunohistochemical assessment of CD8+ T cells in the TME has been shown to more accurately predict patient outcome than traditional UICC staging and its utility as an adjunct to traditional UICC staging has been proposed.^[20] In the case of RCCs the proinflammatory milieu initiated by tumor cells induced the recruitment of CD8 T cells that became ineffective in mounting a strong antitumor immune response and expressed CD8 exhaustion. The expression of these CD8 cells is associated with a chronic inflammatory and highly suppressive process that is recruiting CD8 cells from the circulation, and overall is associated with a poor prognosis.^[21] This clarifies the concept that T-cell exhaustion/inhibition plays an important role in advanced stage and high grade RCCs.

Researchers have linked elevated levels of cytotoxic CD8+ T cells in the TME with positive anti-tumor effects with good prognosis in breast, colorectal, glioblastoma, and cervical cancers.^[22] In colorectal cancer, the presence of CD8 cytotoxic T cells seems to be a useful prognostic marker, and large ongoing studies aim at implementing a combination of Immunoscore with TNM classification in a routine clinical setting.^[23] Recently, several studies

independently described a significant association of TILs with better patient survival in primary NSCLC, melanoma and breast cancer. Some authors recommended including the grade of TILs in the pathological reports as the amount of TILs was even predictive for therapy response.^[24]

CONCLUSION

A thorough understanding of the various inflammatory and immune mediators in the tumor microenvironment may help the scientists to develop new plans for the treatment of RCC. This may improve the already existing strategies to facilitate CD8 mediated anti-tumor functions and thereby hinder T cell dysfunction and create a less immunosuppressive TME. Our findings are of importance in light of the recent advances that introduced immunotherapy as a major approach in advanced RCC. Cancer types with high densities of CD8 immune cells may be the best candidates for studies assessing the efficacy of immune checkpoint therapies and to improve immunotherapy.

Acknowledgement

We thank the management of SRIHER for providing the facilities to carry out our research successfully. Our study was funded by the Indian Council of Medical Research- Talent Search Scheme (ICMR-TSS fellowship). We are very thankful to the patients and technicians for providing their expertise that immensely aided the research.

Conflicts of interest: NIL

Funding: ICMR-TSS.

REFERENCES

1. Siegel RL, Miller KD, Jemal A. Cancer statistics, 2018. *CA Cancer J Clin.* 2018 Jan;68(1):7-30.
2. Chandrasekaran D, Sundaram S, N K, R P. Programmed Death Ligand 1; An Immunotarget for Renal Cell Carcinoma. *Asian Pac J Cancer Prev.* 2019 Oct 1;20(10):2951-2957.
3. Abraham GP, Cherian T, Mahadevan P, Avinash TS, George D, Manuel E. Detailed study of survival of patients with renal cell carcinoma in India. *Indian J Cancer.* 2016 Oct-Dec;53(4):572-574.
4. Jin, MZ., Jin, WL. The updated landscape of tumor microenvironment and drug repurposing. *Sig Transduct Target Ther* 5, 166 (2020).
5. Patard JJ, Kim HL, Lam JS, Dorey FJ, Pantuck AJ, Zisman A, Ficarra V, Han KR, Cindolo L, De La Taille A, Tostain J, Artibani W, Dinney CP, Wood CG, Swanson DA, Abbou CC, Lobel B, Mulders PF, Chopin DK, Figlin RA, Belldegrun AS. Use of the University of California Los Angeles integrated staging system to predict survival in renal cell carcinoma: an international multicenter study. *J Clin Oncol.* 2004 Aug 15;22(16):3316-22.
6. Diaz-Montero CM, Rini BI, Finke JH. The immunology of renal cell carcinoma. *Nat Rev Nephrol.* 2020 Dec;16(12):721-735.
7. Stanton SE, Disis ML. Clinical significance of tumor-infiltrating lymphocytes in breast cancer. *J Immunother Cancer.* 2016 Oct 18; 4:59.
8. Kim TS, da Silva E, Coit DG, Tang LH. Intratumoral Immune Response to Gastric Cancer Varies by Molecular and Histologic Subtype. *Am J Surg Pathol.* 2019 Jun;43(6):851-860.
9. Zappasodi R, Merghoub T, Wolchok JD. Emerging Concepts for Immune Checkpoint Blockade-Based Combination

- Therapies [published correction appears in *Cancer Cell*. 2018 Oct 8;34(4):690]. *Cancer Cell*. 2018;33(4):581-598.
10. Crispin JC, Tsokos GC. Cancer immunosurveillance by CD8 T cells. *F1000Res*. 2020;9: F1000 Faculty Rev-80. Published 2020 Feb 3.
 11. Mella M, Kauppila JH, Karihtala P, et al. Tumor infiltrating CD8+ T lymphocyte count is independent of tumor TLR9 status in treatment naïve triple negative breast cancer and renal cell carcinoma. *Oncoimmunology*. 2015;4(6): e1002726. Published 2015 May 22.
 12. Rozsypalova A, Rosova B, Filipova A, Nikolov DH, Chloupkova R, Richter I, Proks J, Zachoval R, Matej R, Melichar B, Buchler T, Dvorak J. Negative prognostic significance of primary cilia, CD8+ tumor infiltrating lymphocytes and PD1+ cells expression in clear cell renal cancer. *J BUON*. 2019 Jul-Aug;24(4):1644-1651.
 13. Zhang S, Zhang E, Long J, et al. Immune infiltration in renal cell carcinoma. *Cancer Sci*. 2019;110(5):1564-1572. doi:10.1111/cas.13996
 14. Shuch B, Bratslavsky G, Linehan WM, Srinivasan R. Sarcomatoid renal cell carcinoma: a comprehensive review of the biology and current treatment strategies. *Oncologist*. 2012;17(1):46-54.
 15. Menard LC, Fischer P, Kakrecha B, et al. Renal Cell Carcinoma (RCC) Tumors Display Large Expansion of Double Positive (DP) CD4+CD8+ T Cells with Expression of Exhaustion Markers. *Front Immunol*. 2018; 9:2728. Published 2018 Nov 26.
 16. Baine MK, Turcu G, Zito CR, et al. Characterization of tumor infiltrating lymphocytes in paired primary and metastatic renal cell carcinoma specimens. *Oncotarget*. 2015;6(28):24990-25002.
 17. Maimela NR, Liu S, Zhang Y. Fates of CD8+ T cells in Tumor Microenvironment. *Comput Struct Biotechnol J*. 2018; 17:1-13. Published 2018 Nov 22.
 18. Remark R, Alifano M, Cremer I, Lupo A, Dieu-Nosjean MC, Riquet M, Crozet L, Ouakrim H, Goc J, Cazes A, Fléjou JF, Gibault L, Verkarre V, Régnard JF, Pagès ON, Oudard S, Mlecnik B, Sautès-Fridman C, Fridman WH, Damotte D. Characteristics and clinical impacts of the immune environments in colorectal and renal cell carcinoma lung metastases: influence of tumor origin. *Clin Cancer Res*. 2013 Aug 1;19(15):4079-91.
 19. Kawakami F, Sircar K, Rodriguez-Canales J, et al. Programmed cell death ligand 1 and tumor-infiltrating lymphocyte status in patients with renal cell carcinoma and sarcomatoid dedifferentiation. *Cancer*. 2017;123(24):4823-4831.
 20. Ziai J, Gilbert HN, Foreman O, et al. CD8+ T cell infiltration in breast and colon cancer: A histologic and statistical analysis. *PLoS One*. 2018;13(1): e0190158. Published 2018 Jan 10.
 21. Zhang Z, Liu S, Zhang B, Qiao L, Zhang Y, Zhang Y. T Cell Dysfunction and Exhaustion in Cancer. *Front Cell Dev Biol*. 2020; 8:17.
 22. Durgeau A, Virk Y, Corgnac S, Mami-Chouaib F. Recent Advances in Targeting CD8 T-Cell Immunity for More Effective Cancer Immunotherapy. *Front Immunol*. 2018 Jan 22; 9:14.
 23. Galon J, Pagès F, Marincola FM, et al. Cancer classification using the Immunoscore: a worldwide task force. *J Transl Med*. 2012; 10:205.
 24. Hendry S, Salgado R, Gevaert T, et al. Assessing Tumor-infiltrating Lymphocytes in Solid Tumors: A Practical Review for Pathologists and Proposal for a Standardized Method from the International Immunooncology Biomarkers Working Group: *Adv Anat Pathol*. 2017;24(5):235-251.