

## ROLE OF ULTRASOUND GUIDED PERCUTANEOUS NEEDLE ASPIRATION IN MANAGEMENT OF LIVER ABSCESS

Singh Neeru Janeshwar<sup>1</sup>, Gaurav Patnayak<sup>1</sup>, Abhishek Kumar<sup>2</sup>, Mithilesh Pratap<sup>3</sup>

<sup>1</sup>Senior resident, Department of Radiodiagnosis, Bhagwan Mahavir Institute of Medical Sciences, Pawapuri, Bihar, India.

<sup>2</sup>Consultant Radiologist, ARL diagnostics, Bihar Sharif, Bihar, India.

<sup>3</sup>Associate Professor, Bhagwan Mahavir Institute of Medical Sciences, Pawapuri, Bihar, India.

Received : 10/10/2022  
Received in revised form : 07/11/2022  
Accepted : 20/11/2022

Keywords:  
Ultrasound guide, Liver abscess,  
Percutaneous aspiration.

Corresponding Author:  
**Dr. Mithilesh Pratap**  
Email: drneerusinghh@gmail.com  
ORCID: 0000-0001-5653-646X

DOI: 10.47009/jamp.2022.5.1.132

Source of Support: Nil,  
Conflict of Interest: Nondeclared

Int J Acad Med Pharm  
2023; 5 (1); 633-636



### Abstract

**Background:** The introduction of newer and potent antimicrobial agents together with diagnostic technology advancement is considered as a paradigm shift in the management of liver abscess.

**Aim:** To evaluate the safety and efficacy by ultrasound guided percutaneous needle aspiration in management of liver abscess. **Materials and Methods:** Lidocaine hydrochloride 2% was induced with 10 ml before aspiration. The ultrasound guided percutaneous needle aspiration was done by free hand technique using a USG machine with 3.5 MHz frequency. To localize the abscess and the needle, a continuous real time sonographic imaging was used.

**Result:** The mean age of these subjects was 58.9 years, though subjects of various age groups ranging from 15-78 years were enrolled. The highest incidence of liver abscess was observed in 41 to 70 years. The highest incidence of liver abscess was seen in the low income group and was least in high income group. Both the genders were affected, with the incidence being higher in Males. **Conclusion:** Ultrasound guided needle aspiration combined with antimicrobials remains the preferred therapeutic approach for treating liver abscess.

## INTRODUCTION

In tropical countries, Liver abscesses is an important reason for morbidity and mortality.<sup>[1]</sup> The introduction of newer and potent antimicrobial agents together with diagnostic technology advancement is considered as a paradigm shift in the management of liver abscess. An image guided percutaneous needle aspiration has become the treatment of choice for such cases.<sup>[2]</sup>

Prevalence of liver abscess in developing countries including India is alarming and is the major determinant of mortality and morbidity.

The traditional approach to treat liver abscess is either antimicrobial alone or in combination with blind percutaneous aspiration.

Recently, ultrasound guided aspiration and drainage has gained popularity. The new technique is also laden with its own limitation, but still is the treatment of choice because of ease and accuracy.

The technique of ultrasound guided percutaneous needle aspiration requires a long and wide bore needle. This needle is introduced into the abscess cavity to aspirate pus under ultrasound guidance by an interventional radiologist. As a routine, the

aspirated pus is then sent for microbiological examination. The use of ultrasound for diagnosing liver abscess and for guided percutaneous needle aspiration, has reduced the need of laparotomy.

The advantage of sonographic technique is real time imaging, that facilitates keeping an eye on the course of the needle as they traverse tissues plane.<sup>[3]</sup>

Therefore, the present study was conducted to evaluate the safety and efficacy by ultrasound guided percutaneous needle aspiration in management of liver abscess.

## MATERIALS AND METHODS

This prospective, observational, uni-centric study was conducted at department of Radiology, at Bhagwan Mahavir Institute of Medical Sciences, Pawapuri. The study was conducted over a period of 1 years from November 2021 to October 2022. The study was approved by the institutional research and ethical committee. An informed and written consent was obtained from the participating subjects before the commencement of the study.

The study samples included all the subjects of liver abscess who were diagnosed for liver abscess using

Ultrasound or Computer Tomography and referred to our department for ultrasound guided percutaneous needle aspiration.

Procedure: The procedure was conducted under complete aseptic precaution.

Lidocaine hydrochloride 2% was induced with 10 ml before aspiration. The ultrasound guided percutaneous needle aspiration was done by free hand technique using a USG machine with 3.5 MHz frequency. To localize the abscess and the needle, a continuous real time sonographic imaging was used. In case of multiple abscesses, the same needle was redirected under the same continuous real time sonographic imaging.

The subjects were then followed at an interval of 3 to 4 days each till the abscess cavity was reduced to below 20 ml or collapsed and no relapse of abscess.

The data was tabulated into a Microsoft excel spread sheet and subjected to statistical analysis using SPSS Software.

## RESULTS

The present study evaluated the safety and efficacy of ultrasound guided percutaneous needle aspiration in liver abscess cases. A total of 154 cases were enrolled, of which only 143 subjects reported for the subsequent visit, giving a response rate of 92.86 %. The mean age of these subjects was 58.9 years, though subjects of various age groups ranging from 15-78 years were enrolled. The highest incidence of liver abscess was observed in 41 to 70 years.

**Table 1: Distribution of subjects according to age. (n=143)**

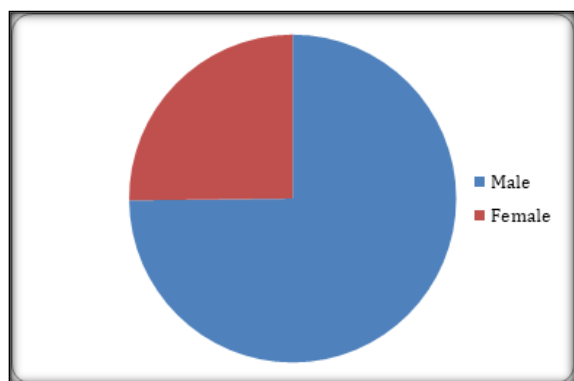
Age range	Number	Percentage
11-20	3	2.09
21-30	5	3.49
31-40	17	11.88
41-50	34	23.77
51-60	32	22.37
61-70	44	30.76
71-80	8	5.59
Total	143	100

The distribution of subjects according to the socioeconomic status is shown in table 2. The highest incidence of liver abscess was seen in the low income group and was least in high income group.

**Table 2: Distribution of subjects according to SOCIOECONOMIC STATUS. (n=143)**

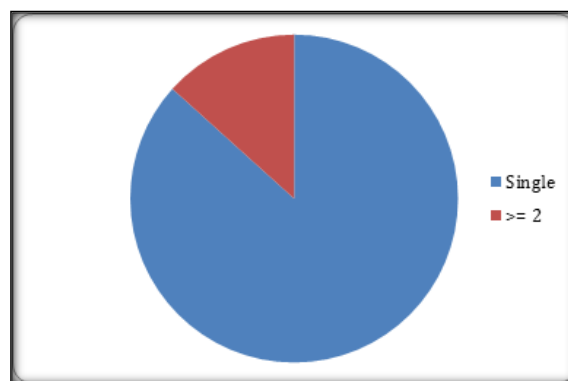
High	16	11.18
Medium	39	27.27
Low	88	61.53
Total	143	100

The infection and / or infestation of liver abscess was not restricted to any specific gender. Both the genders were affected with the incidence being higher in Males (n=107) [Figure1].



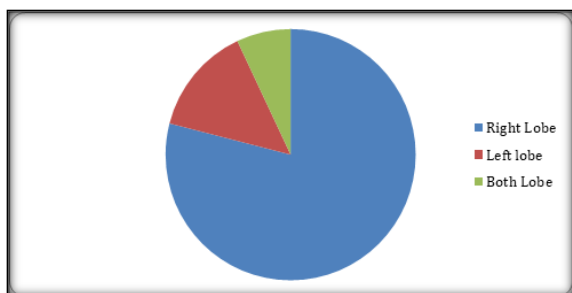
**Figure 1: Distribution of subjects according to symptoms**

A majority of subjects had single abscess (n=112) while only 31 subjects had two or more abscess cavity [Figure 2].



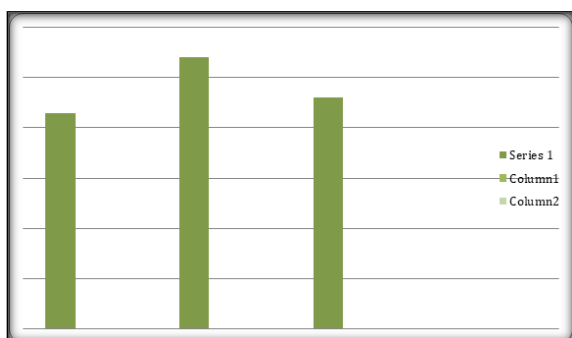**Figure 2: Distribution of subjects according to number of abscess cavity**

The majority of abscess cavity were located in right lobe (n=113), followed by left lobe (n=20), while only 10 subjects had abscess cavity in both lobes [Figure 3].



**Figure 3: Distribution of subjects according to location of abscess cavity**

Considering the number of visits required for aspiration, maximum subjects required two visits aspiration (n=54) followed by third visit (n=46), the single visit relief was observed in only 43 subjects [Figure 4].



**Figure 4: Distribution of subjects according to number of visits**

## DISCUSSION

Controversies between surgical drainage and ultrasound guided percutaneous needle aspiration has not been concluded.<sup>[4]</sup> Percutaneous drainages with an added systemic antibiotic is the preferred treatment regimen for the management of pyogenic abscess.<sup>[2,5]</sup> In contrast, for amoebic abscesses, the preferred mode of treatment varies depending on the presentation of the disease.<sup>[2]</sup>

The percutaneous needle aspiration for liver abscess is an easy and effective mode of treatment. The technique has replaced laparotomy which now has very limited indications. An additional benefit of needle aspiration is comparatively cost effective, no catheter related problem and limited hospital care. The percutaneous needle aspiration technique also offers multiple abscesses cavity to be aspirated in the same visit.

The current study evaluated the outcome of percutaneous needle aspiration combined with antiamebic and antibiotic treatment. Follow up USG were done at 3 to 4 days' interval after first visit. A second and third aspiration was done if required.

The highest incidence of liver abscess was observed in 41 to 70 years, of which maximum incidence was seen in 61-70 years. In contrast, the highest incidence of liver abscess was observed in 31 to 40 years by Mukhopadhyay et al.<sup>[6,7]</sup> Our study was in contrast with previous results.<sup>[8,9]</sup>

The present study results show that, both the genders were affected, with the incidence being higher in Males. This was in consonance with the previous studies.<sup>[6,9]</sup>

Our study results found, the highest incidence of liver abscess was seen in the low income group and was least in high income group. Most of the patient are economically poor and lives in rural area. Male predominance may be attributed to the lifestyle with men going out to work and consuming contaminated water, beverages and unhygienic food while the women are largely confined to their homes.

In our study, the majority of abscess cavity were located in right lobe (n=113), followed by left lobe (n=20), while only 10 subjects had abscess cavity in both lobes. this was similar to a previous report.<sup>[6, 9-11]</sup> The percutaneous drainage technique for liver abscess is still not getting desired popularity, possibly due to unavailability at all places, high set-up cost, specialized consultant required or non-willingness to change traditional method.<sup>[12]</sup>

The type of abscess was determined on the basis of amoebic serology and pus culture reports.<sup>[13]</sup> The major advantages of the current technique includes: 1) less invasive 2) cost effective 3) no catheter care; and 3) multiple abscess cavities can be aspirated in the same visit.<sup>[14]</sup> The success rate of percutaneous needle aspiration is reported to be 77-100%.<sup>[15]</sup>

## CONCLUSION

Ultrasound guided needle aspiration combined with antimicrobials remains the preferred therapeutic approach for treating liver abscess.

## REFERENCES

1. Sharma N, Sharma A, Varina S, Lal A, Singh V. Amoebic liver abscess in the medical emergency of a North Indian hospital. BMC Res Notes 2010; 3: 21.
2. Rajak CL, Gupta S, Jain S, Chawla Y, Gulati M, Suri S. Percutaneous treatment of liver abscesses: Needle aspiration versus catheter drainage. Am J Roentgenol 1998;170:1035-9.
3. Giorgio A, de Stefano G, Di Sarno A, Liorre G, Ferraioli G. Percutaneous needle aspiration of multiple pyogenic abscesses of the liver: 13-year single center experience. Am J Roentgenol 2006;187:1585-90.
4. Arshad Z, Saijad A. Amoebic liver abscess: A comparative study of needle aspiration versus conservative treatment. J Ayub Med Coll Abbottabad 2002;14:10-2.
5. Yu SC, Ho SS, Lau WY, Yeung DT, Yuen EH, Lee PS, et al. Treatment of pyogenic liver abscess: Prospective randomized comparison of catheter drainage and needle aspiration. Hepatology 2004; 39: 932-8
6. Singh S, Chaudhary P, Saxena N, Khandelwal S, Poddar DD and Biswal UC. Treatment of liver abscess: prospective randomized comparison of Catheter drainage and needle aspiration. Ann Gastroenterol 2013; 26: 332-9.
7. Mukhopadhyay M, Saha AK, Sarkar A, Mukherjee S. Amoebic liver abscess: Presentation and complications. Indian J Surg 2010; 72: 37-41.
8. Ghosh CK, Alam F, Mahmuduzzaman M, Kabir AKMS, Uddoula MS, Islam QT. Clinical Pattern of Liver Abscess among the Patients Admitted in Rajshahi Medical College Hospital. Bangladesh J Medicine Jul 2015; 26: 55-60.

9. Paik B, Sarkar SK, Chowdhury PK, Ahmed S. Clinical profile of amoebic liver abscess patients admitted in a tertiary care hospital. *Bang Med J Khulna* 2015; 48: 20-3.
10. Hughes MA, Petri WA., Jr Amebic liver abscess. *Infect Dis Clin North Am.* 2000;14: 565-82.
11. Sharma MP, Kumar A. Liver abscess in children. *Indian J Pediatr.* 2006; 73: 813-17.
12. Egba R, Asuquo M, Ugare GU, Udoh I. Closed drainage of liver abscesses: The UNICAL drain as an efficient and cost saving device in a tropical setting. *Niger J ClinPract.* 2008; 11: 396-9.
13. Khan R, Hamid S, Abid S, et al. Predictive factors for early aspiration in liver abscess. *World J Gastroenterol.* 2008; 14: 2089-93.
14. Giorgio A, Tarantino L, Mariniello N, et al. Pyogenic liver abscesses: 13 years of experience in percutaneous needle aspiration with US guidance. *Radiology.* 1995; 195: 122-24.
15. Dietrick RB. Experience with liver abscess. *Am J Surg.* 1984; 147: 288-91