

USEFULNESS OF ULTRASONOGRAPHY IN DIAGNOSIS OF TYPHOID FEVER

Pankaj Ajitkumar Badjate¹

¹Radio-Diagnosis, Swami Ramanand Tirth, Rural Medical College, Ambajogai, Dist Beed, Maharashtra, India

Received : 28/11/2022
Received in revised form : 03/01/2023
Accepted : 15/01/2023

Keywords:
Typhoid fever, Ultrasonography, Splenomegaly.

Corresponding Author:
Dr. Pankaj Ajitkumar Badjate,
Email: drpankajbarjate23@gmail.com
ORCID: 0000-0002-9920-5588

DOI: 10.47009/jamp.2023.5.1.128

Source of Support: Nil,
Conflict of Interest: None declared

Int J Acad Med Pharm
2023; 5 (1); 618-620



Abstract

Background: To assess usefulness of USG in the diagnosis of typhoid fever. **Materials and Methods:** One hundred eight typhoid fever of both genders were included in the study. All were subjected to USG using a convex transducer with a frequency of 4 MHz and a linear transducer with a frequency of 12 MHz. USG Murphy's sign along with pericholecystic edema and fluid collection were evaluated according to the graded compression method in suspected cases of acalculus cholecystitis. Parameters such as splenomegaly, mesenteric lymph nodes (MLNs), bowel thickening, perforation, ascites and hepatomegaly were recorded. **Result:** Out of 108 patients, males were 56 (51.8%) and females were 52 (48.2%). Out of 108 cases, 54 showed splenomegaly on 5th day which decreased to 12 on 10th day and 4 on 15th day. Mesenteric lymph nodes were involved in 60 patients on day 5, which decreased to 25 on day 10 and 7 on day 15. Bowel thickening was seen in 62 on day 5 which decreased to 18 on 10th day and 5 in day 15. Perforation was seen in 45 which decreased to 11 and 3 on day 5, 10 and 15 respectively. Ascites was seen in 56 on day 5, 16 on day 10 and 1 on day 15. 40 showed acalculous cholecystitis on day 5th, which decreased to 28 on day 10 and 0 on day 15. Hepatomegaly was present in 70 on day 5, which decreased to 42 on 10th day and 0 to 15th day. **Conclusion:** USG is one of the reliable diagnostic aids in the detection of typhoid fever. The clinical picture and ultrasound findings are almost diagnostic even when widal test is inconclusive and blood cultures are sterile or not available.

INTRODUCTION

Typhoid fever is caused by *Salmonella typhi* and paratyphi bacilli and is endemic in many parts of the world.^[1] In India, it is the fifth most common infectious disease. Symptoms may vary from mild to severe and usually begin six to thirty days after exposure. Often there is a gradual onset of a high fever over several days.^[2] Weakness, abdominal pain, constipation, and headaches also commonly occur. Some people develop a skin rash with rose colored spots. In severe cases there may be confusion. Without treatment symptoms may last weeks or months. There are high rates of complications.^[3] Atypical clinical findings make an early diagnosis difficult. Definitive diagnosis of typhoid fever is made by hemoculture and serological tests, namely Widal test, both requiring from some days to over a week to show positive results.^[4]

USG is a useful imaging modality for the evaluation of typhoid fever. It is noninvasive, non-ionizing and quick. USG examination of the abdomen is helpful in the diagnosis of typhoid fever during the 1st week

of onset of fever.^[5] The common US findings are hepatosplenomegaly, thickening of the walls of the terminal ileum, cecum and ascending colon, mesenteric lymphadenopathy, perforation, ascites and acute acalculus cholecystitis.^[6,7] Considering this, the present study assessed USG in the diagnosis of typhoid fever.

MATERIALS AND METHODS

A sum total of one hundred eight typhoid fever of both genders were included in the study. All agreed to participate in the study. Ethical approval was also obtained from institutional ethical & review committee.

Demographic data such as name, age, gender etc. was noted. A thorough physical and systemic examination was carried out. 5 ml venous samples of patients were taken for performing Widal test after 7 days of fever. All were subjected to USG using a convex transducer with a frequency of 4 MHz and a linear transducer with a frequency of 12 MHz. USG Murphy's sign along with pericholecystic edema and fluid collection were

evaluated according to the graded compression method in suspected cases of acalculus cholecystitis. Parameters such as splenomegaly, mesenteric lymph nodes (MLNs), bowel thickening, perforation, ascites and hepatomegaly were recorded. Results were subjected to statistical analysis using Mann Whitney U test. P value less than 0.05 was considered significant.

RESULTS

Out of 108 patients, males were 56 (51.8%) and females were 52 (48.2%). [Table 1]

Out of 108 cases, 54 showed splenomegaly on 5th day which decreased to 12 on 10th day and 4 on 15th day. Mesenteric lymph nodes were involved in 60 patients on day 5, which decreased to 25 on day 10 and 7 on day 15. Bowel thickening was seen in 62 on day 5 which decreased to 18 on 10th day and 5 in day 15. Perforation was seen in 45 which decreased

to 11 and 3 on day 5, 10 and 15 respectively. Ascites was seen in 56 on day 5, 16 on day 10 and 1 on day 15. 40 showed acalculus cholecystitis on day 5th, which decreased to 28 on day 10 and 0 on day 15. Hepatomegaly was present in 70 on day 5, which decreased to 42 on 10th day and 0 to 15th day. [Table 2]

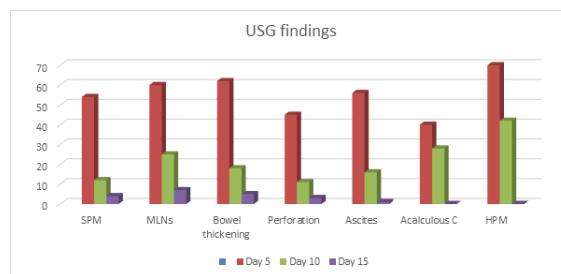


Figure 1: Assessment of USG findings

Table 1: Distribution of patients

Total- 108		
Gender	Males	Females
Number	56 (51.8%)	52 (48.2%)

Table 2: Assessment of USG findings

Follow up scan	SPM	MLNs	Bowel thickening	Perforation	Ascites	Acalculous C	HPM
Day 5	54	60	62	45	56	40	70
Day 10	12	25	18	11	16	28	42
Day 15	4	7	5	3	1	0	0

DISCUSSION

Typhoid fever is caused by the bacterium *Salmonella typhi*, also known as *Salmonella enterica* serotype Typhi, growing in the intestines and blood.^[8,9] Typhoid is spread by eating or drinking food or water contaminated with the feces of an infected person. Risk factors include poor sanitation and poor hygiene.^[10,11] Considering this, the present study assessed USG in the diagnosis of typhoid fever.

Our results demonstrated that out of 108 patients, males were 56 (51.8%) and females were 52 (48.2%). Nadhim et al,^[12] determined usefulness of abdominal ultrasound in the diagnosis of typhoid fever. The following ultrasound findings were reported: hepatomegaly (31.4%), prominent intrahepatic bile ducts (64.85%), splenomegaly (100%), mesenteric lymphadenopathy (42.85%), bowel wall thickening (35.71%), acalculus cholecystitis (16.28%), perforations (1.14%), and ascites in (3.4%).

We found that out of 108 cases, 54 showed splenomegaly on 5th day which decreased to 12 on 10th day and 4 on 15th day. Mesenteric lymph nodes were involved in 60 patients on day 5, which decreased to 25 on day 10 and 7 on day 15. Nakachi et al,^[13] found that 80 cases were found to be Widal positive and *Salmonella* culture was positive in 32

cases. The US findings were as follows: splenomegaly (n-26, 100%); Bowel wall thickening (n-22, 85%); mesenteric lymphadenopathy (n-20,77%); hepatomegaly with normal parenchymal echotexture (n-8, 31%); thickened gall bladder (n-16, 62%); biliary sludge (n-6, 23%); positive US Murphy's sign (n-7, 27%); pericholecystic edema with increased vascularity (n6, 23%); mucosal ulceration in the wall of the gall bladder (n-1, 3.8%). It was observed that bowel thickening was seen in 62 on day 5 which decreased to 18 on 10th day and 5 in day 15. Perforation was seen in 45 which decreased to 11 and 3 on day 5, 10 and 15 respectively. Tarantino et al,^[14] evaluated the clinical application of the signs of bowel wall thickening and/or enlarged mesenteric lymph nodes to diagnose typhoid fever by assessing the sensitivity (68%) and specificity (81%) of these findings in febrile patients. In these patients, mural thickening (4-9 mm) was observed in only 36.8% of patients with typhoid fever.

We found that ascites was seen in 56 on day 5, 16 on day 10 and 1 on day 15. 40 showed acalculus cholecystitis on day 5th, which decreased to 28 on day 10 and 0 on day 15. Hepatomegaly was present in 70 on day 5, which decreased to 42 on 10th day and 0 to 15th day. Johnson et al,^[15] found that 12 of 52 patients had calculus cholecystitis; these individuals as well as eight patients without

cholecystitis having hemocultures negative for *S. typhi* were excluded from the study. The rest of the cases (32) were included in this USG-based study for evaluation of features specific for typhoid fever. The following observations were recorded: splenomegaly in 32 patients, enlarged MLNs in 30 patients, bowel wall thickening in 25 patients, acalculus cholecystitis in 20 patients, and hepatomegaly in 10 patients. They concluded that these USG features hepatosplenomegaly, enlarged MLNs, bowel wall thickening, and acalculus cholecystitis should strongly favor the diagnosis of typhoid.

CONCLUSION

USG is one of the reliable diagnostic aids in the detection of typhoid fever. The clinical picture and ultrasound findings are almost diagnostic even when widal test is inconclusive and blood cultures are sterile or not available.

REFERENCES

1. Crump J, Luby S, Mintz E. The global burden of typhoid fever. *Bulletin of the World Health Organization*. 2004;82:346–353.
2. Enwere G, Biney E, Cheung Y, et al. Epidemiologic and clinical characteristics of community-acquired invasive bacterial infections in children aged 2–29 months in The Gambia. *The Pediatric Infectious Diseases Journal*. 2006;25:700705. [PubMed] [Google Scholar]
3. Feng YC. The epidemiology of typhoid fever in the Dong Thap Province, Mekong Delta region of Vietnam. *The American Journal of Tropical Medicine and Hygiene*. 2000;62:644–648. [PubMed] [Google Scholar]
4. Gordon M, Walsh A, Chaponda M, et al. Bacteraemia and mortality among adult medical admissions in Malawi—predominance of non-typhi salmonellae and *Streptococcus pneumoniae*. *The Journal of Infection*. 2001;42:44–49.
5. Germanier R, Furer E. Isolation and characterization of gal E mutant Ty 21a of *Salmonella typhi*: a candidate strain for a live, oral typhoid vaccine. *J Infect Dis*. 1975; 131: 55-58.
6. Puyleart JBMC, Kristjansdottir S, Golterman KL, Gerard MJ, Nelly MK. Typhoid fever: Diagnosis by using Sonography. *Am J Radiol*. 1989; 1: 745-746.
7. Lim JH, Ku YT, Lee DH et al. Sonography of inflammatory bowel diseases. *Am J Radiol* 1994; 163 : 343-347.
8. Lee DH. Sonographic findings of intestinal tuberculosis. *J Ultrasound Med*. 1993; 12: 537-540.
9. Sharma A, Qadri A. Vi polysaccharide of *Salmonella typhi* targets the prohibitin family of molecules in intestinal epithelial cells and suppresses early inflammatory responses. *Proc Natl Acad Sci*. 2004; 101: 174-77.
10. Mateen MA, Saleem S, Rao PC, et al. Ultrasound in the diagnosis of typhoid fever. *Indian J Pediatr*. 2006; 73: 68-70.
11. Cohen EK, Stringer DA, Smith CR, et al. Hydrops of the gallbladder in typhoid fever as demonstrated by sonography. *J Clin Ultrasound*. 1986; 14: 633.
12. Nadhim Younis Saeed, The role of abdominal ultrasound in the diagnosis of typhoid fever: An observational study, *Travel Medicine and Infectious Disease* (2013), <http://dx.doi.org/10.1016/j.tmaid.2013.09.004>.
13. Nakachi S, Nakamura T, Agha N, et al. Clinical features and early diagnosis of typhoid fever emphasizing usefulness of detecting mesenteric lymphadenopathy with ultrasound as diagnostic method. *Southeast Asian J Trop Med Public Health*. 2003; 34: 15-7
14. Tarantino L, Giorgio A. Value of bowel ultrasonography in the diagnosis of typhoid fever. *Eur J Ultrasound* 1997;5:77-83.
15. Johnson AO, Aderele WI. Enteric fever in childhood. *J Trop Med Hyg*. 1981; 84: 29-35.