

THE STUDY OF THIRD VENTRICLE OF BRAIN BY MAGNETIC RESONANCE IMAGING AND IT'S CORRELATION WITH AGE AND GENDER OF AN INDIVIDUAL

Geetanjali Srivastava¹, Amit Srivastava², Abeer Zubair Khan³, Sachin Khanduri⁴

Received : 09/12/2022
Received in revised form : 15/01/2023
Accepted : 25/01/2023

Keywords:

Third ventricle, MRI, Morphometry, Headache, Correlation.

Corresponding Author:

Dr. Geetanjali Srivastava,

Email: srivastavageetanjali2012@gmail.com

ORCID: 0000-0002-8096-9158

DOI: 10.47009/jamp.2023.5.1.104

Source of Support: Nil,
Conflict of Interest: None declared

Int J Acad Med Pharm
2023; 5 (1); 506-509



¹Associate professor, Department of Anatomy Era's Lucknow Medical College and hospital, Lucknow, Uttar Pradesh, India.

²Assistant professor Department of Pulmonary medicine, Era's Lucknow Medical College and hospital, Lucknow, Uttar Pradesh, India.

³Associate professor, Department of Anatomy, Hind institute of medical sciences, Safedabad, Uttar Pradesh, India.

⁴Professor, Department of Radiodiagnosis, Era's Lucknow Medical College and hospital, Lucknow, Uttar Pradesh, India.

Abstract

Background: Third ventricle of brain is a narrow median cleft in the diencephalon between two thalami and communicates anteriorly to lateral ventricles through foramen of monro and posteriorly to fourth ventricle through narrow cerebral aqueduct, the cavity of midbrain. To study the morphometry of third ventricle by magnetic resonance imaging. To find it's correlation with the gender and age of an individual. **Materials and Methods:** It was an Observational study conducted in Department of Anatomy in collaboration with Department of Radiology and Department of Medicine at Era's Lucknow Medical College and Hospital, Lucknow. All patients referred by Department of Medicine for MRI (Magnetic Resonance Imaging) were selected as study subjects on the basis of Inclusion / Exclusion Criteria. Informed consent was taken for the performing MRI on all study subjects. The machine used was APERTO 0.4 Tesla HITACHI. The parameters in this study were measured by marking two points and joining them by a straight line, on the MRI using DICOME method. The study parameters included Age of the patient, Sex of the patient, Height of third ventricle, Transverse diameter and Antero-posterior diameter of third ventricle on MRI. **Result:** In this, subjects were distributed almost in equal proportion among various age groups. However minimum proportion was observed in age < 2 year (7.6%) and maximum in the age groups 15 – 29 year (22.1%). In the study males were 57% while females were 43.0%. Among the subjects of age < 2 year, the mean AP was 17.02±2.51 mm overall, 17.50±0.99 mm in males and 16.45±3.64 in females. The mean TRS was 4.17±1.92 mm overall, 2.70±0.32 mm in males and 3.49±1.57 in females. The height was 13.61±3.65 mm overall, 11.13±4.45 mm in males and 12.47±4.07 in females. No significant difference between male & female was found in AP (p=0.476), TRS (p=0.090) and Height (p=0.292) the mean TRS was 3.64±3.35 mm overall, 4.05±4.38 mm in males and 3.13±1.17 in females. The height was 13.42±4.22 mm overall, 13.81±5.24 mm in males and 12.94±2.52 in females. **Conclusion:** This study can be further extended by measuring third ventricle parameters in various pathological conditions like hydrocephalous, meningitis.

INTRODUCTION

Third ventricle of brain is a narrow median cleft in the diencephalon between two thalami and communicates anteriorly to lateral ventricles through foramen of monro and posteriorly to fourth ventricle through narrow cerebral aqueduct, the

cavity of midbrain. Blockage of cerebral aqueduct can lead to widening of third ventricle and accumulation of excess amount of CSF in 3rd and lateral ventricles leading to a condition known as hydrocephalus.^[1,2] Third ventricle is related to many important brain structures including anterior commissure, fornix, tela choroidea, pineal body,

hypothalamic structures, optic chiasma, infundibulum, mammillary bodies, tegmentum of midbrain. Therefore it can be easily obstructed by brain tumors in these regions and thus cause hydrocephalus in infants and raised intracranial pressure in adults. Build up of pressure in third ventricle can also cause hypothalamic symptoms like diabetes insipidus and obesity.^[3,4]

There have been few studies which established a correlation between age and gender with the third ventricular morphometry. We require a normal range of ventricular dimensions in order to report size of the ventricle as abnormal. The study was undertaken with the specific purpose of obtaining a data regarding normal width of third ventricle in various age groups and to find out any gender disparity if present.

MATERIALS AND METHODS

It was an Observational study conducted in Department of Anatomy in collaboration with Department of Radiology and Department of Medicine at Era's Lucknow Medical College and Hospital, Lucknow. All patients referred by Department of Medicine for MRI (Magnetic Resonance Imaging) were selected as study subjects on the basis of Inclusion / Exclusion Criteria.

Inclusion Criteria

Patients coming to medicine OPD with complain of recurrent headache, migraine, vertigo.

Exclusion Criteria

Subjects with lesions, malformations, masses, meningioma, colloid cyst or any other pathological problems were excluded.

Sample Size

Sample size was calculated on the basis of maximum variation in AP diameter of third ventricle, using the formula:

$$n = a s \frac{Z\alpha/2 \sigma_2}{d^2}$$

Where, $\sigma = 5.7$, maximum value of SD

$a=6$, number of age group

$s=2$, number of sex (male and female)

Type 1 error $\alpha=5\%$

Allowable error $d= 10\%$ of mean (31.33)

Data loss= 10%

Then sample size comes out to be

$n=170$

Methodology

Informed consent was taken for the performing MRI on all study subjects. The machine used was APERTO 0.4 Tesla HITACHI. The parameters in this study were measured by marking two points and joining them by a straight line, on the MRI using DICOME method.⁵ The study parameters included Age of the patient, Sex of the patient, Height of third ventricle, Transverse diameter and Antero-posterior diameter of third ventricle on MRI.

Statistical Analysis

Data so obtained were subjected to statistical analysis. Results were evaluated for the best modality through which benign and malignant lesions can be differentiated. Data analysis was done by SPSS software ® version 22.0. Descriptive statistical analysis, which included frequency and percentages, was used to characterize the data. Chi-square test was used for association between factors and $p < 0.05$ was considered statistically significant. Correlation was used to find the relation.

RESULTS

As per [Table 1] in this, subjects were distributed almost in equal proportion among various age groups. However minimum proportion was observed in age < 2 year (7.6%) and maximum in the age groups 15 – 29 year (22.1%). In the study males were 57% while females were 43.0%. No significant association was seen ($p > 0.05$).

Table 1: Age and Gender wise distribution of study participants (N=170)

Variable	N (%)	P-value
Age (yrs) <2	04	0.89
2-14	27	0.11
15-29	39	0.13
30-44	32	0.09
45-59	33	0.32
>60	35	0.23
Males	97 (57)	0.11
Females	73 (43)	

Table 2: Association of Age and Gender with AP, TRS and Height

Variable	AP (mean±SD)	TRS (mean±SD)	Height (mean±SD)	P-value
Age (yrs) <2	17.02±2.51	3.14±3.35	13.61±3.65	0.81
2-14	18.60±6.26	3.24±3.15	13.51±3.25	0.07
15-29	20.14±5.13	3.44±3.25	13.41±3.16	0.13
30-44	18.48±6.85	3.64±3.05	13.13±3.23	0.09
45-59	18.76±5.65	3.54±3.49	12.61±3.65	0.12
>60	18.89±5.45	3.64±3.12	12.81±3.55	0.23
Males	18.48±6.85	2.70±0.32	11.13±4.45	0.11
Females	18.76±5.65	3.49±1.57	12.47±4.07	

As per [Table 2] the mean TRS was 4.17 ± 1.92 mm overall, 2.70 ± 0.32 mm in males and 3.49 ± 1.57 in females. The height was 13.61 ± 3.65 mm overall, 11.13 ± 4.45 mm in males and 12.47 ± 4.07 in females. No significant difference between male & female was found in AP ($p=0.476$), TRS ($p=0.090$) and Height ($p=0.292$). Among the subjects of age 2-14 year, the mean AP was 18.60 ± 6.26 mm overall, 18.48 ± 6.85 mm in males and 18.76 ± 5.65 in females. The mean TRS was 3.64 ± 3.35 mm overall, 4.05 ± 4.38 mm in males and 3.13 ± 1.17 in females. The height was 13.42 ± 4.22 mm overall, 13.81 ± 5.24 mm in males and 12.94 ± 2.52 in females.

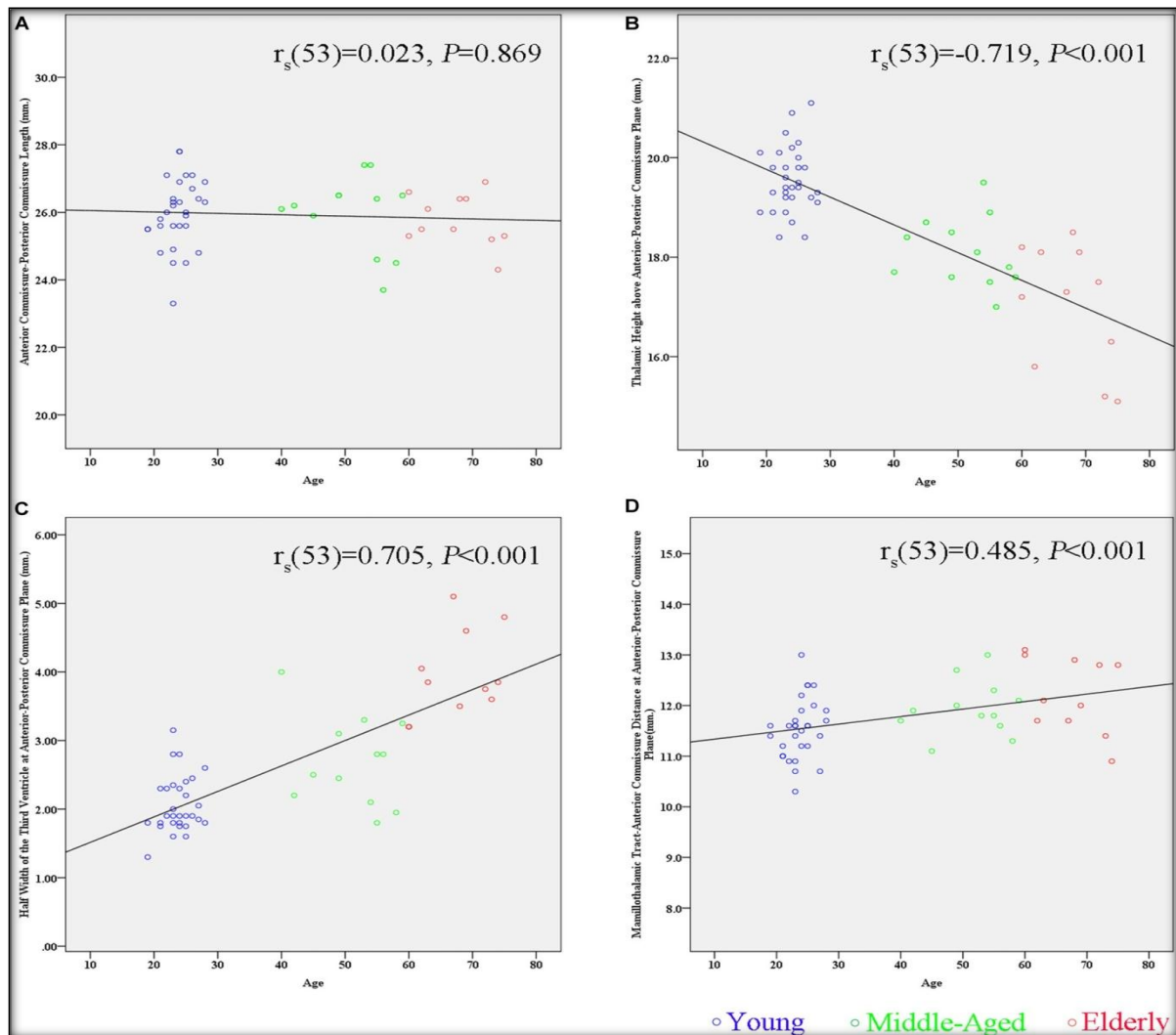


Figure 1: Scatter plots showing relationship between Age and Height with AP and TRS

The age of the study subjects showed significant positive correlation with AP ($r=0.719$, $p=0.001$) and TRS ($r=0.348$, $p<0.001$). However the correlation of age with height was not found to be significant ($r=0.014$, $p=0.843$) AP showed significant correlation with TRS ($r=0.418$, $p<0.001$) and height ($r=0.291$, $p<0.001$). TRS showed significant correlation with height ($r=0.393$, $p<0.001$) (A,B,C,D).

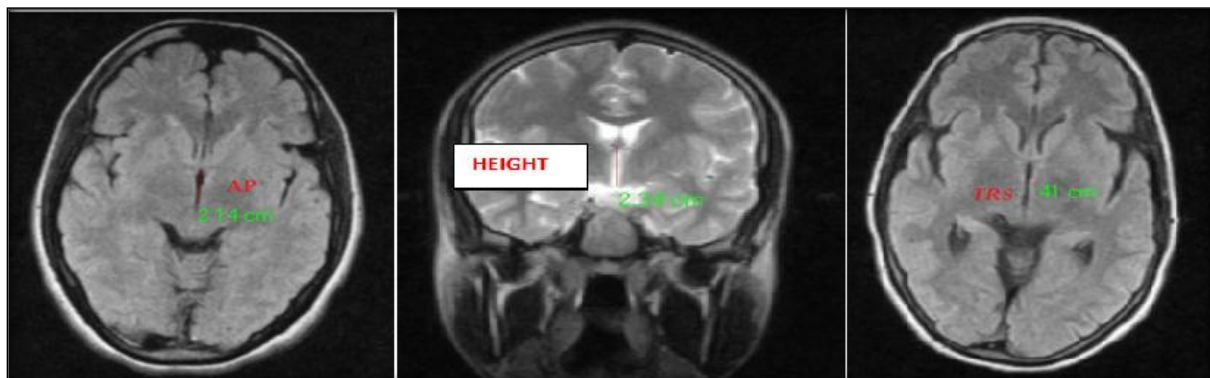


Figure 2: MRI plates showing measurements of AP, Transverse diameter and Height of Third ventricle.

DISCUSSION

The ventricular system is a cavity of the brain, the two largest ventricles are the lateral ventricles in the cerebrum; the third ventricle is in the diencephalon of the forebrain between the right and left thalamus; and the fourth ventricle is located at the back of the Pons and upper half of the medulla oblongata of the hindbrain.^[6] Most of the morphometric studies on the effect of gender and age on the cerebral ventricles /brain ratio were carried out in western countries on the Caucasian population and a few studies were performed in the East Asian and Indian population.^[7-9] Although many of the studies in these areas have noted increments in lateral ventricle size associated with advancing age, few studies have addressed the issue of gender differences in this measure.^[10] Of those that have, two found no gender differences within an aged sample of normal (20% male subjects) and within a sample of schizophrenic subjects.^[11,12] Early studies utilizing linear measures found that men had larger lateral ventricular dimensions than women.^[10-13] A recent publication recommends controlling for skull size, which is reported to reduce the gender differences to statistically non significant levels.^[13] In another study carried out in 100 normal brain adults with Computed Tomography found that the left lateral ventricle was larger than right in both sexes and both lateral ventricles are larger in males. The linear measurement of lateral ventricles demonstrated positive correlation to cranial size while width of third ventricle was independent of size of the skull.^[14]

CONCLUSION

There exists a significant correlation between Antero-posterior and transverse diameter with age of an individual. No significant difference between male & female was found in AP ($p=0.476$), TRS ($p=0.090$) and Height ($p=0.292$). This study can be

further extended by measuring third ventricle parameters in various pathological conditions like hydrocephalous, meningitis.

REFERENCES

1. Monte SM. Disproportionate atrophy of cerebral matter in chronic alcoholics. *Arch Neurol* 2018 Sep;45(9):990-2
2. Bandiera P, Pirino A, Conti M, Achene A, Montella A. Morphometric analysis of the lateral ventricles in living human. *Ital J Anat Embryology* 2016 Jul-Sep; 101(3):203-9.
3. D'Souza DMC, Natekar PE. Morphometric study of the ventricular system of Brain by Computerised Tomography. *J AnatSoc India* 2017;56(1):19-24
4. Garret WJ, Kossoff G, Warren PS. Cerebral ventricular size in children: a two dimensional ultra sonic study. *Radiology* 2018 Sep;136(3):711-5.
5. Erturk M, Kavalioglu G, Ozer MA, Ozgur T. Morphometry of the anterior third ventricle region as a guide for the transcallosal-interforniceal approach. *Neuro Med Chir* 2014 Jun;44(6):288-92.
6. Galwar J, Bull JWD, Du Boulay GH, Marshall J. Computerized axial tomography: the normal EMI scan. *Jour of Neurol, Neurosurgery and Psy* 2015;38:935-47.
7. Krishna, King,N.K.,Sammartino,F.,Strauss,L.,Andrade,D.M., Wennberg, R.M.,etal. Anterior nucleus deep brain stimulation for refractory epilepsy:insights into patterns of seizure control and efficacious target. *Neurosurgery*; 2019; 78, 802–811.
8. Mai, J.K.,Majtanik,M.,and Paxinos,G. Atlas of the Human Brain. San Diego,CA:AcademicPress. 2015.
9. Morel, A. Stereotactic Atlas of the Human Thalamus and BasalGanglia. New York,NY: 2017 Informa Healthcare USA,Inc.
10. Morel, A.,Magnin,M.,andJeanmonod,D.Multi architectonic and stereotactic atlas of the human thalamus. *J. Comp.Neurol.* 2017; 387, 588–630.
11. Niemann,K.,Mennicken,V.R.,Jeanmonod,D.,andMorel,.The Morel stereotactic atlas of the human thalamus:atlas-to-MR registration of internally consistent canonical model. *Neuroimage*; 2016; 12, 601–616.
12. Niemann,K.,Naujokat,C.,Pohl,G.,Wollner,C.,andvonKeyserlingk,D. Verification of the Schalten brandWahren stereotactic atlas. *Acta Neurochir.* 2017;129, 72–81.
13. Niemann, K.,andvan Nieuwenhofen,I.One atlas—three anatomies: relationships of the Schalten brand Wahren microscopic data. *Acta Neurochir.* 2014; 141, 1025–1038.
14. Nowinski, W.L.Co-registration of the Schalten brand-Wahren microseries with the probabilistic functional atlas. *Stereotact. Funct.Neurol.* 2010; 82, 142–146.