

COMPARISON OF TAPP REPAIR WITH A 12/15 CM MESH AND 06/11 CM MESH FOR AVERAGE BUILT INDIAN POPULATION IN TERTIARY CARE PUBLIC HOSPITAL

Prasenjit Mukhopadhyay¹, Dheeraj Anchlia², Golam Sarwar³, Shubho Chowdhuri⁴

Received : 22/09/2022
Received in revised form : 20/10/2022
Accepted : 31/10/2022

Keywords:

TAPP, polypropylene mesh, recurrence rate.

Corresponding Author:

Dr. Shubho Chowdhuri,
Email: chowdhurishubho@gmail.com
ORCID: 0000-0003-0381-9639

DOI: 10.47009/jamp.2022.4.5.72

Source of Support: Nil,
Conflict of Interest: None declared

Int J Acad Med Pharm
2022; 4 (5); 359-362



¹Associate Professor, Department of General Surgery, Murshidabad Medical College and Hospital, West Bengal, India.

²Assistant Professor, Department of General Surgery, Rampurhat Government Medical College and Hospital, West Bengal, India.

³Senior Resident, Department of General Surgery, Murshidabad Medical College and Hospital, West Bengal, India.

⁴Junior Resident, Department of General Surgery, Murshidabad Medical College and Hospital, West Bengal, India.

Abstract

Background: Conventionally a 15/15 mesh trimmed into 12/15 mesh is used for TAPP repair. Due to the ample supply of 6/11 cm mesh in tertiary care government hospitals, we started doing TAPP with smaller size 6/11 mesh with the idea in mind that it should be adequate for smaller built Indian population. To demonstrate the adequacy of a 6/11 cm polypropylene mesh in TAPP repair without any increase in recurrence rate for a small built Indian population. **Materials and Methods:** The study includes persons who have undergone TAPP with 6/11 cm mesh in R.G. Kar Medical College from November 2011 to February 2016 and Murshidabad Medical College from March 2016 to February 2020. Data were prospectively entered and analysed. **Result:** A total of 78 patients underwent TAPP by us in this period, out of which 32 patients received 6/11 cm mesh while 46 received conventional 12/15 cm mesh. Mean follow up was 30.48 months. No recurrence has been observed in both the groups to date. **Conclusion:** TAPP with a smaller 6/11 cm mesh is adequate for a smaller built Indian population without any increase in recurrence rate.

INTRODUCTION

Though a common problem, the exact incidence of inguinal hernias is unknown.^[1] Inguinal hernia repair is one of the most commonly performed operations, with about 20 million of hernia repairs annually.^[2] Minimally invasive inguinal hernia repairs are getting their recognition over the last two decades. Laparoscopic preperitoneal inguinal hernia repairs (TAPP and TEP) are other methods of tension-free mesh repair. Over the past few decades, there has been tremendous progress and improvisation in hernia repair techniques to reduce intraoperative and postoperative complications.^[3,4,5,6]

Three procedures are accepted internationally for uncomplicated groin hernia repair-open tension-free mesh repair, TAPP & TEP. (1) TAPP is widely practised and popular throughout the world. (2) Conventionally a 15/15 mesh trimmed to 12/15 mesh is used to cover all the defects and is associated with a very low recurrence rate if

performed with proper technique. During the initial days of our journey of TAPP repair, we didn't have a free supply of larger 15/15 cm mesh in our government hospitals but 6/11 cm mesh was readily available. Hence we started doing TAPP repair with 6/11 cm mesh aiming that it may be adequate for repair without any increase in recurrence for our Indian population.^[7,8,9,10,11,12,13,14]

MATERIALS AND METHODS

Study Design: A prospective non-randomized study.

Study Location

This prospective non-randomized study has been conducted in R.G. Kar Medical College, Kolkata and Murshidabad Medical College, Berhampore, West Bengal.

Study Duration: November 2011 to February 2020 for around 8.3 years.

Inclusion Criteria

Inclusion criteria were uncomplicated unilateral inguinal hernia, age above 20 years below 60 years and informed consent to participate in the study.

Exclusion Criteria

Bilateral and recurrent inguinal hernia, complicated inguinal hernia, age above 60 and below 20 years and comorbidities like cardiac and uncorrected prostatism. Those who denied informed consent were also not included in our study.

This prospective non-randomized study has been conducted in R.G. Kar Medical College, Kolkata and Murshidabad Medical College, Berhampore, West Bengal from November 2011 to February 2020 for around 8.3 years. Inclusion criteria were uncomplicated unilateral inguinal hernia, age above 20 years below 60 years and informed consent to participate in the study. Exclusion criteria were bilateral and recurrent inguinal hernia, complicated inguinal hernia, age above 60 and below 20 years and comorbidities like cardiac and uncorrected prostatism. Those who denied informed consent were also not included in our study.

6/11 cm was used for 32 patients and conventional 15/ 15 cm into 12/15 CM was used in the rest of the 46 patients. All the operations were performed under general anaesthesia. (5) Amoxycylav (1.2 gm) was used intravenously as the prophylactic antibiotic in all the patients. Pneumoperitoneum was established by the supraumbilical 10 mm port by open technique and maintaining a pressure of 12 to 15 mm of Hg. The peritoneum was closed in a continuous manner using 2-0 prolene in both groups. No fixation of mesh was done in either of the groups.

Patients were examined on the second postoperative day before discharge, on the 10th post-op day in OPD, after 6 months, 1 year, 2 years & 3 years. Mean follow up was 30.48 months. Patients were followed up focusing on recurrence rate and pain. VAS was used to assess pain; this scale has a range of pain from 1 (best) to 10 (worst).^[15,16,17,18,19]

RESULTS

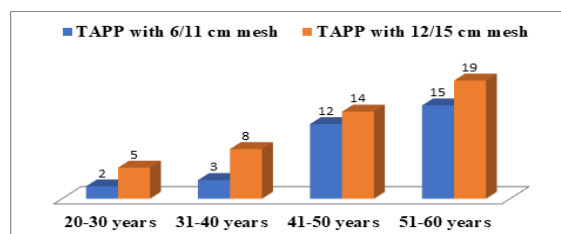


Figure 1: Age distribution

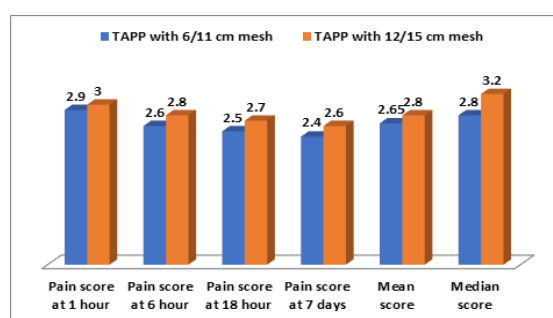


Figure 2: Pain score distribution

The mean Post-OP pain score was 2.65 in the 6/11 cm group and 2.8 in the 12/15 cm group. Recurrence- No recurrence has been detected to date in either of the groups.

Table 1: Age distribution

S. NO	Age group	TAPP with 6/11 cm mesh	TAPP with 12/15 cm mesh
1	20-30 years	2	5
2	31-40 years	3	8
3	41-50 years	12	14
4	51-60 years	15	19
5	Total	32	46

Table 2: Pain score distribution

S.NO	Parameters	TAPP with 6/11 cm mesh	TAPP with 12/15 cm mesh
1	Pain score at 1 hour	2.9	3.0
2	Pain score at 6 hour	2.6	2.8
3	Pain score at 18 hour	2.5	2.7
4	Pain score at 7 days	2.4	2.6
5	Mean score	2.65	2.8
6	Median score	2.8	3.2

Table 3: Complications

S. NO	Complications	TAPP with 6/11 cm mesh	TAPP with 12/15 cm mesh
1	Intra-operative complications	3.125% (1)	4.347% (2)
2	Severe postoperative pain	3.125% (1)	6.521% (3)
3	Seroma	0%(0)	2.173% (1)
4	Hematoma	0%(0)	0%(0)
5	Wound infection	0%(0)	0%(0)
6	Recurrence	0%(0)	0%(0)

DISCUSSION

TAPP is a standard procedure for hernia repair via a laparoscopic approach.^[2,4,20] Ideally it is done using 15/15 cm mesh trimmed into 12/15 cm mesh. We have tried to use 6/11cm mesh in our Indian population to see the outcome. Early complications are those which occur within one month of surgery like seroma, wound infection, & hematoma and long-term complications are those which are assessed at three months like testicular atrophy, inguinal pain & recurrence.^[21,22,23,24] Both early and late complications were almost comparable in both groups. No recurrence was noted in approximately 30.48 months of follow-up in either of the groups. The total laparoscopic preperitoneal (TAPP) approach in the present study significantly reduced the final chronic pain score per patient in comparison with the anterior transinguinal approach and our data came in concordance with studies of same interest. The postoperative complications of hernia repair were estimated regarding the rate and traced regarding the type in similar previous studies as early and delayed forms. Early complication, defined as that occurring within 1 month of surgery, are wound seroma, sepsis, scrotal edema and hematoma formation while the long-term complications, assessed at 3 months are testicular atrophy and recurrence.^[22,23,24] In our study, the overall complication rate was 18%. Bilateral inguinal hernia is an ideal indication for laparoscopic preperitoneal. TAPP with a smaller 6/11 cm mesh is adequate for a smaller built Indian population without any increase in recurrence rate. It is safe, comfortable for patients, and cost effective, without increased morbidity or recurrence risk.^[25] Long term complications include testicular atrophy and recurrence. Our study observed 0% incidence for recurrence of hernia. Many researchers who reported 0% incidence for testicular atrophy and 0% or very low incidence (1.5%) for recurrence in their studies.^[26,27] Recurrence after hernia repair is poorly understood. Recurrence can occur at any stage following hernia surgery. Patients' risk factors such as higher BMI, smoking, diabetes and postoperative surgical site infections increase the risk of recurrence and can be modified.^[28,29] Amongst the surgical factors, surgeon's experience, larger mesh with better tissue overlap and careful surgical techniques to reduce the incidence of seroma or hematoma help reduce the recurrence rate. Other factors including type of mesh and fixation of mesh have not shown any difference in the incidence of recurrence.^[30,31]

CONCLUSION

TAPP repair using 6/11 cm mesh if done with proper technique is not associated with an increase in recurrence rate or complications.

REFERENCES

1. Bittner R, Schwarz J. Primary unilateral not complicated inguinal hernia: our choice of TAPP, why, results and review of literature. *Hernia*. 2019;23(3):417-428. doi: 10.1007/s10029-019-01959-z.
2. Chen DC, Morrison J. State of the art: open mesh-based inguinal hernia repair. *Hernia*. 2019;23(3):485-492. doi: 10.1007/s10029-019-01983-z.
3. Köckerling F, Bittner R, Kofler M, Mayer F, Adolf D, Kuthe A, et al. Lichtenstein Versus Total Extraperitoneal Patch Plasty Versus Transabdominal Patch Plasty Technique for Primary Unilateral Inguinal Hernia Repair: A Registry-based, Propensity Score-matched Comparison of 57,906 Patients. *Ann Surg*. 2019;269(2):351-357. doi: 10.1097/SLA.0000000000002541.
4. Mancini R, Pattaro G, Spaziani E. Laparoscopic trans-abdominal pre-peritoneal (TAPP) surgery for incarcerated inguinal hernia repair. *Hernia*. 2019;23(2):261-266. doi: 10.1007/s10029-018-1828-7.
5. Zhang D, Zhou C, Wei D, Ge L, Li Q. Dexamethasone added to local anesthetics in ultrasound-guided transversus abdominis plain (TAP) block for analgesia after abdominal surgery: A systematic review and meta-analysis of randomized controlled trials. *PLoS One*. 2019;14(1):e0209646. doi: 10.1371/journal.pone.0209646.
6. Techapongsatorn S, Tansawet A, Kasetsermwiriya W, McEvoy M, Attia J, Wilasrusmee C, et al. Mesh fixation technique in totally extraperitoneal inguinal hernia repair - A network meta-analysis. *Surgeon*. 2019;17(4):215-224. doi: 10.1016/j.surge.2018.09.002.
7. Baloyiannis I, Perivoliotis K, Sarakatsianou C, Tzovaras G. Laparoscopic total extraperitoneal hernia repair under regional anesthesia: a systematic review of the literature. *Surg Endosc*. 2018;32(5):2184-2192. doi: 10.1007/s00464-018-6083-6.
8. Taylor C, Layani L, Liew V, Ghun M, Crampton N, White S. Laparoscopic inguinal hernia repair without mesh fixation, early results of a large randomised clinical trial. *Surg Endosc*. 2008;22(3):757-62. doi: 10.1007/s00464-007-9510-7.
9. Siddaiah-Subramanya M, Ashrafi D, Memon B, Memon MA. Causes of recurrence in laparoscopic inguinal hernia repair. *Hernia*. 2018;22(6):975-986. doi: 10.1007/s10029-018-1817-x.
10. Ahmed MA, Tawfic QA, Schlachta CM, Alkhamesi NA. Pain and Surgical Outcomes Reporting After Laparoscopic Ventral Hernia Repair in Relation to Mesh Fixation Technique: A Systematic Review and Meta-Analysis of Randomized Clinical Trials. *J Laparoendosc Adv Surg Tech A*. 2018;28(11):1298-1315. doi: 10.1089/lap.2017.0609.
11. Eriksen JR. Pain and convalescence following laparoscopic ventral hernia repair. *Dan Med Bull*. 2011;58(12):B4369.
12. Katri KM. Open preperitoneal mesh repair of recurrent inguinal hernia. *Hernia*. 2009;13(6):585-9. doi: 10.1007/s10029-009-0520-3.
13. Peitsch WK. A modified laparoscopic hernioplasty (TAPP) is the standard procedure for inguinal and femoral hernias: a retrospective 17-year analysis with 1,123 hernia repairs. *Surg Endosc*. 2014;28(2):671-82. doi: 10.1007/s00464-013-3208-9.
14. Bracale U, Melillo P, Pignata G, Di Salvo E, Rovani M, Merola G, et al. Which is the best laparoscopic approach for inguinal hernia repair: TEP or TAPP? A systematic review of the literature with a network meta-analysis. *Surg Endosc*. 2012;26(12):3355-66. doi: 10.1007/s00464-012-2382-5.
15. Ahonen-Siirtola M, Nevala T, Vironen J, Kössi J, Pinta T, Niemeläinen S, et al. Laparoscopic versus hybrid approach for treatment of incisional ventral hernia: a prospective randomized multicenter study of 1-month follow-up results. *Hernia*. 2018;22(6):1015-1022. doi: 10.1007/s10029-018-1784-2.
16. Rauh KH, Andersen RS, Rosenberg J. Visual analogue scale for measuring post-operative pain. *Ugeskr Laeger*. 2013;175(24):1712-6.

17. Chiu LYL, Sun T, Ree R, Dunsmuir D, Dotto A, Ansermino JM, Yamold C. The evaluation of smartphone versions of the visual analogue scale and numeric rating scale as postoperative pain assessment tools: a prospective randomized trial. *Can J Anaesth.* 2019;66(6):706-715. English. doi: 10.1007/s12630-019-01324-9.
18. Le May S, Ballard A, Khadra C, Gouin S, Plint AC, Villeneuve E, et al. Comparison of the psychometric properties of 3 pain scales used in the pediatric emergency department: Visual Analogue Scale, Faces Pain Scale-Revised, and Colour Analogue Scale. *Pain.* 2018;159(8):1508-1517. doi: 10.1097/j.pain.0000000000001236.
19. Chiarotto A, Maxwell LJ, Ostelo RW, Boers M, Tugwell P, Terwee CB. Measurement Properties of Visual Analogue Scale, Numeric Rating Scale, and Pain Severity Subscale of the Brief Pain Inventory in Patients With Low Back Pain: A Systematic Review. *J Pain.* 2019;20(3):245-263. doi: 10.1016/j.jpain.2018.07.009.
20. Hamza Y, Gabr E, Hammadi H, Khalil R. Four-arm randomized trial comparing laparoscopic and open hernia repairs. *Int J Surg.* 2010;8(1):25-8. doi: 10.1016/j.ijso.2009.09.010.
21. Demetrashvili Z, Qerqadze V, Kamkamidze G, Topchishvili G, Lagvilava L, Chartholani T, et al. Comparison of Lichtenstein and laparoscopic transabdominal preperitoneal repair of recurrent inguinal hernias. *Int Surg.* 2011;96(3):233-8. doi: 10.9738/cc53.1.
22. Scheuermann U, Niebisch S, Lyros O, Jansen-Winkeln B, Gockel I. Transabdominal Preperitoneal (TAPP) versus Lichtenstein operation for primary inguinal hernia repair - A systematic review and meta-analysis of randomized controlled trials. *BMC Surg.* 2017;17(1):55. doi: 10.1186/s12893-017-0253-7.
23. Tolver MA, Strandfelt P, Forsberg G, Hjørne FP, Rosenberg J, Bisgaard T. Determinants of a short convalescence after laparoscopic transabdominal preperitoneal inguinal hernia repair. *Surgery.* 2012;151(4):556-63. doi: 10.1016/j.surg.2011.08.020.
24. Millat B; Fédération de Recherche EN Chirurgie (FRENCH). Inguinal hernia repair. A randomized multicentric study comparing laparoscopic and open surgical repair. *J Chir (Paris).* 2007;144(2):119-24. French. doi: 10.1016/s0021-7697(07)89483-x.
25. Johansen N, Vyrdal CD, Bisgaard T. Nationwide Results on Chronic Pain After Bilateral Transabdominal Preperitoneal Inguinal Hernia Repair. *Scand J Surg.* 2020;109(4):289-294. doi: 10.1177/1457496919874483.
26. Timișescu L, Turcu F, Munteanu R, Gîdea C, Drăghici L, Ginghină O, et al. Treatment of bilateral inguinal hernia -- minimally invasive versus open surgery procedure. *Chirurgia (Bucur).* 2013;108(1):56-61.
27. Farooq O, Batool Z, Din AU, Ullah AA, Butt Q, Kibryia RI. Anterior tension - free repair versus posterior preperitoneal repair for recurrent hernia. *J Coll Physicians Surg Pak.* 2007;17(8):465-8.
28. Lundström KJ, Holmberg H, Montgomery A, Nordin P. Patient-reported rates of chronic pain and recurrence after groin hernia repair. *Br J Surg.* 2018;105(1):106-112. doi: 10.1002/bjs.10652.
29. Martin-Del-Campo LA, Miller HJ, Elliott HL, Novitsky YW. Laparoscopic ventral hernia repair with and without defect closure: comparative analysis of a single-institution experience with 783 patients. *Hernia.* 2018;22(6):1061-1065. doi: 10.1007/s10029-018-1812-2.
30. Bisgaard T, Kaufmann R, Christoffersen MW, Strandfelt P, Gluud LL. Lower Risk of Recurrence After Mesh Repair Versus Non-Mesh Sutured Repair in Open Umbilical Hernia Repair: A Systematic Review and Meta-Analysis of Randomized Controlled Trials. *Scand J Surg.* 2019;108(3):187-193. doi: 10.1177/1457496918812208.
31. Nahid AK, Rahman S, Veerapatherar K, Fernandes R. Outcomes on mesh fixation vs non-fixation in laparoscopic totally extra peritoneal inguinal hernia repair: a comparative study. *Turk J Surg.* 2021;37(1):1-5. doi: 10.47717/turkjsurg.2021.4962.