

EVALUATION OF APOPTOTIC INDEX IN VARIOUS GRADES OF ORAL EPITHELIAL DYSPLASIA

M.Sumathi¹, P.Kalaivani²

¹Associate Professor, Department of Pathology, Coimbatore Medical College & Hospital, Tamil Nadu, India.

²Assistant Professor, Department of Pathology, Coimbatore Medical College & Hospital, Tamil Nadu, India.

Received : 30/09/2022
Received in revised form : 04/11/2022
Accepted : 20/11/2022

Keywords:
Apoptosis, Squamous cell carcinoma,
Potentially malignant disorder.

Corresponding Author:
Dr. P. Kalaivani,
Email: vanipraka@yahoo.com
ORCID: 0009-0007-6761-6466

DOI: 10.47009/jamp.2022.4.5.178

Source of Support: Nil,
Conflict of Interest: None declared

Int J Acad Med Pharm
2022; 4 (5); 855-858



Abstract

Background: To evaluate apoptotic index in various grades of oral epithelial dysplasia. **Materials and Methods:** 72 histopathologically diagnosed cases of hyperkeratosis with varying degree of dysplasia and different grades of oral squamous cell carcinomas of both genders were studied. The apoptotic cells ratio was calculated as: Apoptotic Index (AI) = Total no. of apoptotic cells/ Total no. of cells in 10 HPF. **Results:** Out of 72 cases, 48 were of males and 24 were of females. The mean dysplasia in normal cells was 0.0012, mild dysplasia was 0.004, moderate dysplasia was 0.003, severe dysplasia was 0.012 and no dysplasia was 0.001. A significant difference was obtained ($P < 0.05$). The mean difference of different grades in normal cells was 0.013, in well differentiated SCC was 0.016, in moderately differentiated SCC was 0.017 and in poorly differentiated SCC was 0.003. A significant difference was obtained ($P < 0.05$). **Conclusion:** There was significant significance of apoptosis in determining disease progression in oral potentially malignant disorders.

INTRODUCTION

Squamous cell carcinoma (SCC) is a type of skin cancer that originates from the squamous cells, which are thin, flat cells found on the surface of the skin.^[1] Squamous cell carcinoma can also occur in other tissues, such as the lining of the respiratory tract, oesophagus, cervix, and other areas of the body.^[2] The primary cause of squamous cell carcinoma is prolonged exposure to ultraviolet (UV) radiation from the sun or tanning beds. Other risk factors include fair skin, a history of sunburns, a weakened immune system, exposure to certain chemicals or toxins, and a history of precancerous skin lesions.^[3]

Among malignancies, oral squamous cell carcinomas (OSCC) are some of the most aggressive. Because of the late stage of tumor diagnosis, the reported 5-year survival rate for some areas of the oral cavity is as low as 9%.^[4] The OSCC survival rate dramatically rises from 66% to 85% in cases of early identification and treatment. It has been stated in the past that treatment and diagnosis at the "precancerous" stage would increase survival rates even more. Oral epithelial dysplasia (OED), a variety of tissue and cellular changes that are associated with carcinoma, is frequently seen before OSCC.^[5] These alterations frequently show up as a clinical mucosal lesion. Loss of basal cell polarity, basilar hyperplasia, increased nuclear

cytoplasmic ratio, drop-shaped rete ridges, abnormal mitotic figures, strange mitoses, hyperchromatic nucleus, loss of cohesion, cellular and nuclear pleomorphism, nuclear hyperchromatism, and other histopathological findings are all signs of dysplasia.^[6] By enabling the build up of proliferating cells and by impeding the elimination of genetic variations with increased malignant potential, an ineffective apoptotic pathway can aid in the development of cancer.^[7] We performed this study to evaluate apoptotic index in various grades of oral epithelial dysplasia.

MATERIALS AND METHODS

The study was conducted in the pathology department in a tertiary care hospital, Tamilnadu for a period of 2 years. A sum total of seventy- two histopathologically diagnosed cases of hyperkeratosis with varying degree of dysplasia and different grades of oral squamous cell carcinomas of both genders were selected for the study. Ethical consideration was taken into account before conduction of study.

Data such as name, age, gender etc. was recorded in case history performa. Apoptotic cells were distinguished morphologically as shrunken cells with a highly eosinophilic cytoplasm and a compact, segregated, and clearly defined mass of chromatin. The counting also included cells with broken nuclei.

Apoptotic cell/bodies were tallied against the total number of tumour cells in each of the five high power areas that were examined for each instance in order to calculate the apoptotic index. Apoptotic index (AI) = Total no. of apoptotic cells/ total no. of

cells in 10 HPF was used to calculate the ratio of Apoptotic Cells. Results of the study obtained were analyzed statistically with p value < 0.05 considered significant.

RESULTS

Table 1: Distribution of patients

Total- 72		
Gender	Male	Female
Number	48	24

Out of 72 cases, 48 were of males and 24 were of females (Table 1).

Table 2: Hyperkeratosis & Apoptosis index

Dysplasia	Apoptosis index (AI)	P value
Normal cells	0.0012	0.001
Mild dysplasia	0.004	
Moderate dysplasia	0.003	
Severe dysplasia	0.012	
No dysplasia	0.001	

The mean dysplasia in normal cells was 0.0012, mild dysplasia was 0.004, moderate dysplasia was 0.003, severe dysplasia was 0.012 and no dysplasia was 0.001. A significant difference was obtained ($P < 0.05$) (Table 2, graph 1).

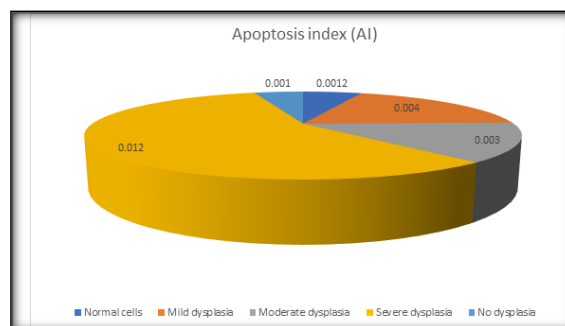


Figure 1: Hyperkeratosis & Apoptosis index

Table 3: Mean difference of different grades of oral squamous cell carcinoma

Dysplasia	Apoptosis index (AI)	P value
Normal cells	0.013	0.001
Well differentiated SCC	0.016	
Moderately differentiated SCC	0.017	
Poorly differentiated SCC	0.003	

The mean difference of different grades in normal cells was 0.013, in well differentiated SCC was 0.016, in moderately differentiated SCC was 0.017 and in poorly differentiated SCC was 0.003. A significant difference was obtained ($P < 0.05$) (Table 3, graph 2).

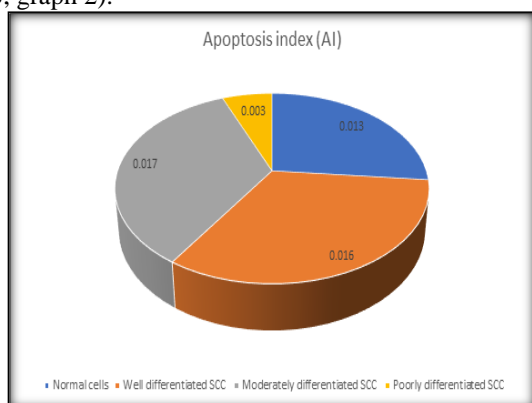


Figure 2: Mean difference of different grades of oral squamous cell carcinoma.

DISCUSSION

Localized oral squamous cell carcinoma (OSCC) metastasizes in various lymph node pathways. Public health issues with this chronic illness exist in both industrialized and developing nations.^[8] Due to the serious consequences of oral squamous cell carcinoma, such as permanent disability and high mortality, the burden is significant. Asia, particularly Southeast Asia, has a high prevalence of oral squamous cell carcinoma.^[9]

The tongue is the place that is most usually afflicted, according to many nations. Clinical TNM classification is the primary basis for prognostic evaluation for oral squamous cell carcinoma (OSCC), although this staging approach is insufficient for the best prognostication and must be augmented by other trustworthy techniques.^[10] Highly, moderately, and poorly differentiated are the descriptive categories used to analyze and

classify OSCC's biological activity. This quantitative grading of cancer was primarily created by Broder in 1920.^[11,12] We performed this study to assess apoptotic index in various grades of oral epithelial dysplasia.

In our study, out of 72 cases, 48 were of males and 24 were of females. Suhasini et al.^[13] in haematoxylin and eosin-stained (H&E) sections, assessed the apoptotic index (AI), mitotic index (MI), and apoptotic to mitotic index ratio (AI: MI) in various degrees of oral epithelial dysplasia (OED) and oral squamous cell carcinoma (OSCC). With higher grades of dysplasia, AI rose, while with higher grades of OSCC, it fell. As OED and OSCC grades rose, MI rose as well. With rising OED grades, AI/MI rose, whereas rising OSCC grades declined.

Our results showed that the mean dysplasia in normal cells was 0.0012, mild dysplasia was 0.004, moderate dysplasia was 0.003, severe dysplasia was 0.012 and no dysplasia was 0.001. The influence of the apoptotic index (AI), MI, and turnover index (TI) to assess the lesion's behavior was demonstrated by Singh et al.^[14] Over the course of a year, 68 cases of premalignant and malignant squamous cell carcinoma with histological proof were examined. The grade of the oral lesion with AI, MI, and TI was assessed and correlated with the biopsy specimen's hematoxylin and eosin-stained sections. Premalignant and malignant exhibited a significant difference in statistical analysis, although mild, moderate, and severe dysplasia show no significant difference.

In our study, the mean difference of different grades in normal cells was 0.013, in well differentiated SCC was 0.016, in moderately differentiated SCC was 0.017 and in poorly differentiated SCC was 0.003. Oral epithelial dysplasia (OED) in varying degrees was previously diagnosed in 30 cases, according to Pwar et al.^[15] AI was computed as the proportion of total cells counted divided by the number of apoptotic bodies/cells in each case. Between mild and severe dysplasia, there was a statistically significant difference ($P = 0.002$). With higher OED grades, the mean AI rose steadily.

Studying apoptosis in premalignant and malignant squamous cell lesions of the oral cavity and assessing its predictive significance in oral cancers were the objectives of the study by Jain et al.^[16] The largest mean AI was found in well-differentiated (WD) squamous cell carcinomas, and a decline was seen as the grades advanced. The mean AI increased gradually with increasing dysplasia. There was a significant difference between WD SCC and SCC with poor differentiation ($P < 0.05$). Mean AI values were considerably ($P < 0.05$) lower in cases with lymph node metastases.

Nambiar et al.^[17] in their study each H and E-stained slide from 50 patients with OED and OSCC with prior diagnoses was included. AI was determined by dividing the total number of nonapoptotic tumor/dysplastic cells counted in each case by the

number of apoptotic bodies/cells. From OED to OSCC, AI increased statistically significantly. Sharma et al in their study a total of 130 participants (108 men and 22 women) made up the sample. The tissues were divided into three groups: normal oral mucosa ($n = 10$), leukoplakia with dysplasia ($n = 60$), and OSCC ($n = 60$) using formalin-fixed and paraffin-embedded tissues. Following MGP staining and standard H & E stained slides, the quantity of apoptotic cells and the apoptotic index (AI) were measured. Apoptotic cells' condensed chromatin was stained with MGP. There was a statistically significant difference ($P = 0.001$) in the number of AI and apoptotic cells across the different study groups. Additionally, AI rose with increasing dysplasia grades, peaking in well-differentiated OSCC. In both H & E and MGP stained sections, the findings were statistically significant ($P = 0.001$). A strong link between MGP and found between MGP and H & E staining results.

CONCLUSION

There was significant significance of apoptosis in determining disease progression in oral potentially malignant disorders.

REFERENCES

1. Macluskey M, Chandrachud LM, Pazouki S, Green M, Chisholm DM, Ogden GR, et al. Apoptosis, proliferation, and angiogenesis in oral tissues possible relevance to tumour progression. *J Pathol* 2000;191:368-75.
2. Kesarwani P, Choudhary A, Gupta R. Apoptosis: A prognostic marker in oral epithelial dysplasia and oral squamous cell carcinoma. *Int J Dent Health Concern* 2016;1:1-4.
3. Angela CC. Epithelial pathology. In: Neville BW, Damm DD, Allen CM, Bouquot JE, editors. *Oral and Maxillofacial Pathology*. 3rd ed. Missouri: Saunders Elsevier; 2009. p. 362-425.
4. Ranganathan K, Kavitha L. Oral epithelial dysplasia: Classifications and clinical relevance in risk assessment of oral potentially malignant disorders. *J Oral Maxillofac Pathol* 2019;23:19-27.
5. Barnes L, Eveson JW, Reichart P, Sidransky D, editors. *World Health Organization Classification of Tumours: Pathology and Genetics of Head and Neck Tumours*. Lyon, France: IARC Press; 2005.
6. Van Der Waal I. Potentially malignant disorders of the oral and oropharyngeal mucosa; Terminology, classification and present concepts of management. *Oral Oncol* 2009;45:317-23.
7. Rajendra R, Shivpathsundaram B. Shafer's Textbook of Oral Pathology 7th ed. Elsevier Publications; 2011. p. 889.
8. Roy R. Assessment of Apoptotic Index in Potentially Malignant Pathologies and Squamous Cell Carcinoma of Oral Cavity-An In Vitro Study. *RGUHS Journal of Medical Sciences*. 2019 May 1;9(2):24-31.
9. Sciubba JJ. Oral cancer: The importance of early diagnosis and treatment. *Am J Clin Dermatol* 2001;2:239-51.
10. Gomez I, Seoane J, Varela Centelles P, Diz P, Takkouche B. Is diagnostic delay related to advanced stage oral cancer? A meta analysis. *Eur J Oral Sci* 2009;117:541-6.
11. McCullough MJ, Prasad G, Farah CS. Oral mucosal malignancy and potentially malignant lesions: An update on the epidemiology, risk factors, diagnosis and management. *Aust Dent J* 2010;55(Suppl 1):61-5.
12. Macluskey M, Chandrachud LM, Pazouki S, Green M, Chisholm DM, Ogden GR, et al. Apoptosis, proliferation and

- angiogenesis in oral tissues, possible relevance to tumor progression. *J Pathol* 2000;199:368-75.
13. Suhasini PD, Mulki S, Supriya H. Apoptotic and mitotic indices in oral epithelial dysplasia and squamous cell carcinoma: A comparative study. *J Oral Maxillofac Pathol* 2022;26:598-9.
 14. Singh P, Kumar V, Singh G, Singh A, Singh A. Significance of the apoptotic index, mitotic index, and turnover index in premalignant and malignant squamous cell lesion of the oral cavity: How much is their diagnostic and prognostic role? *J Sci Soc* 2019;46:49-52.
 15. Pawar RB, Palaskar SJ, Kalavankar SS. Assessment of apoptotic index in various grades of oral epithelial dysplasia: A cross-sectional study. *Indian J Pathol Microbiol* 2020;63:534-7.
 16. Jain A, Maheshwari V, Alam K, Mehdi G, Sharma SC. Apoptosis in premalignant and malignant squamous cell lesions of the oral cavity: A light microscopic study. *Indian J Pathol Microbiol* 2009;52:164-6.
 17. Nambiar S, Hegde V. Apoptosis in oral epithelial dysplastic lesions and oral squamous cell carcinoma: A prognostic marker. *Indian J Pathol Microbiol* 2016;59:284-6.