

EVALUATION OF HISTOPATHOLOGICAL SPECTRUM OF VARIOUS GASTRODUODENAL LESIONS

N.Vani¹, M.Sumathi²¹Assistant Professor, Department of Pathology, Coimbatore Medical College & Hospital, Tamil Nadu, India.²Associate Professor, Department of Pathology, Coimbatore Medical College & Hospital, Tamil Nadu, India.

Received : 15/09/2022
 Received in revised form : 28/10/2022
 Accepted : 09/11/2022

Keywords:

Chronic gastritis, duodenal ulcer,
 gastro-duodenal disorders.

Corresponding Author:

Dr. M. Sumathi,
 Email: sumathipath@gmail.com
 ORCID: 0009-0006-2281-4971

DOI: 10.47009/jamp.2022.4.5.176

Source of Support: Nil.
 Conflict of Interest: None declared

Int J Acad Med Pharm
 2022; 4 (5); 847-850

**Abstract**

Background: To determine histopathological spectrum of various gastroduodenal lesions. **Materials and Methods:** Eighty patients with upper GI symptoms referred for endoscopy of both genders were studied and mucosal findings in the stomach, and duodenum were observed. Endoscopic mucosal biopsies of suspicious lesions were taken. **Results:** Age group 11-20 years had 7, 21-30 years had 12, 31-40 years had 38 and 41-50 years had 23 patients. The difference was significant ($P < 0.05$). Gastroduodenal lesions were benign gastric ulcer + chronic gastritis in 14, chronic gastritis in 36, duodenitis + chronic gastritis in 8, benign duodenal ulcer + chronic gastritis in 12, MAL Toma in 6 and gastric carcinoma in 4 patients. The difference was significant ($P < 0.05$). *H. pylori* positivity in gastroduodenal lesions was seen in benign gastric ulcer + chronic gastritis in 6, chronic gastritis in 18, duodenitis + chronic gastritis in 2, benign duodenal ulcer + chronic gastritis in 3, MAL Toma in 2 and gastric carcinoma in 4 patients. The difference was significant ($P < 0.05$). **Conclusion:** It was observed that the most often identified gastroduodenal lesion was chronic gastritis, which was followed by duodenitis, duodenal ulcers, and gastric cancer.

INTRODUCTION

The most prevalent diseases among adults worldwide may be gastro-oesophageal disorders. Clinical illness is frequently caused by disorders of the stomach and duodenum, with inflammatory and neoplastic diseases being especially prevalent.^[1] The symptoms of gastroduodenal lesions range from dyspepsia to abnormal bowel movements, dysphagia to GI bleeding.^[2]

One of the most prevalent and significant infections in terms of medicine is *H. pylori*, which lives in the gastric pits and mucin layer on the mucosa's surface.^[3] The etiology of the development of peptic ulcer disease has been determined to be infection with this microaerobic, gram negative bacterium.^[4] Additionally, the emergence of gastric neoplasias including gastric adenocarcinoma and gastric mucosa associated lymphoid tissue lymphoma (MAL Toma) has solidly proven *H. pylori* infection. It is a major cause of morbidity in infected patients as it is associated with 90% of duodenal ulcers and 80% of gastric ulcers.^[5] *H. pylori* infection is also associated with gastric mucosa associated lymphoid tissue (MALT) lymphoma and gastric adenocarcinoma. The rate of *H. pylori* infection in north India is high and the spectrum of *H. pylori*

associated gastroduodenal diseases has not been systematically investigated.^[6]

Patients with abnormalities of the upper GI tract, who frequently report with dyspepsia, are thought to benefit most from upper GI endoscopy as a diagnostic tool. Additionally, it provides the chance for biopsy for histology in a variety of gastroduodenal lesions, including cancer, and histology, culture, and urease test in *H. pylori* infection.^[7] The potential to link clinical information, endoscopic observations, and pathological abnormalities through biopsy is excellent for the clinician and pathologist.^[8] The present study determined histopathological spectrum of various gastroduodenal lesions.

MATERIALS AND METHODS

The study was conducted in the pathology department in a tertiary care hospital, Taminadu for a period of 2 years. A sum total of eighty patients with upper GI symptoms referred for endoscopy of both genders were enrolled in this study. Ethical consideration was taken into account before commencing the study.

Data such as name, age, gender etc. was recorded. A thorough general physical examination was

carried out. Following an overnight fast, an upper GI endoscopy utilizing a Fujinon EG-265WR fiberoptic gastroscope was carried out while the patient was under local anesthesia with 10% xylocaine spray. Mucosal findings in the stomach, and duodenum were observed. Endoscopic mucosal biopsies of suspicious lesions were taken. Additionally, gastric mucosal biopsies from the body and antrum were taken to look for *H. pylori*.

The biopsy samples were placed in a little, clearly marked vial filled with 10% buffered formalin. Following processing, the biopsies were divided into sections with a 4 micrometers thickness and stained using modified Giemsa and Haematoxylin and Eosin (H&E) methods. Statistical analysis using Mann Whitney U test was performed. P value < 0.05 was considered significant.

RESULTS

Table 1: Age wise distribution of patients

Age group (years)	Number	P value
11-20	7	0.01
21-30	12	
31-40	38	
41-50	23	

Age group 11-20 years had 7, 21-30 years had 12, 31-40 years had 38 and 41-50 years had 23 patients. The difference was significant (P< 0.05).

Table 2: Type of gastroduodenal lesions

Gastroduodenal lesions	Number	P value
Benign gastric ulcer + chronic gastritis	14	0.02
Chronic gastritis	36	
Duodenitis + chronic gastritis	8	
Benign duodenal ulcer + chronic gastritis	12	
MAL Toma	6	
Gastric carcinoma	4	

Gastroduodenal lesions were benign gastric ulcer + chronic gastritis in 14, chronic gastritis in 36, duodenitis + chronic gastritis in 8, benign duodenal ulcer + chronic gastritis in 12, MAL Toma in 6 and gastric carcinoma in 4 patients. The difference was significant (P< 0.05) (Table 2).

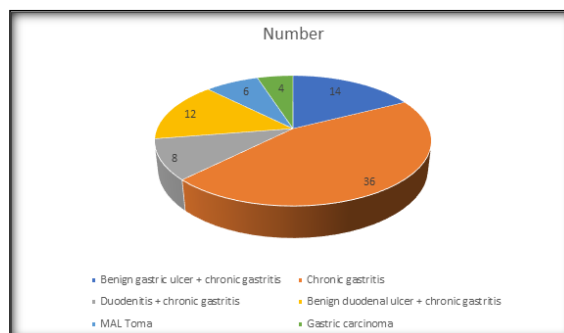


Figure 1: Type of gastroduodenal lesions

Table 3: Assessment of *H. pylori* positivity in gastroduodenal lesions

Gastroduodenal lesions	H. Pylori	P value
Benign gastric ulcer + chronic gastritis	6	0.05
Chronic gastritis	18	
Duodenitis + chronic gastritis	2	
Benign duodenal ulcer + chronic gastritis	3	
MAL Toma	2	
Gastric carcinoma	4	

H. pylori positivity in gastroduodenal lesions was seen in benign gastric ulcer + chronic gastritis in 6, chronic gastritis in 18, duodenitis + chronic gastritis in 2, benign duodenal ulcer + chronic gastritis in 3, MAL Toma in 2 and gastric carcinoma in 4 patients. The difference was significant (P< 0.05) (Table 3).

DISCUSSION

A vascular pattern, oedema, rugal hypertrophy, nodularity, rugal atrophy, erythema with reddish streaks omitted, flat erosions, and exudates are endoscopic characteristics linked to *H. pylori* infection.^[9] It has been proven, nonetheless, that the

endoscopic results in *H. pylori* gastritis do not correspond with histological alterations.^[10] With the onset of peptic ulcer, chronic active gastritis, chronic persistent gastritis, atrophic gastritis, and gastric neoplasia, including gastric adenocarcinoma and gastric mucosa related lymphoid tissue lymphoma, *H. pylori* infection has become firmly

established.^[11,12] The present study determined histopathological spectrum of various gastroduodenal lesions.

In our study, age group 11-20 years had 7, 21-30 years had 12, 31-40 years had 38 and 41-50 years had 23 patients. In a study by Kadam et al.^[13] 100 patients with acid peptic disease symptoms were assessed and endoscopic biopsies from the gastroduodenal location were taken. The average age of presentation for the 100 patients was between 31 and 40 years old, with a male to female ratio of 1.78:1. On histological investigation, chronic gastritis (33 instances), duodenal ulcer (21 cases), gastric ulcer (12 cases), and gastric neoplastic lesion (14 cases) were the most frequent lesions. The most frequent neoplastic lesion found was adenocarcinoma. *H. pylori* was detected by a rapid urease test in 61% of cases and by histopathology in 63% of cases. The etiology of acid peptic disease, of which gastritis was the most prevalent disorder, is significantly influenced by *H. pylori* infection.

It was observed that gastroduodenal lesions were benign gastric ulcer + chronic gastritis in 14, chronic gastritis in 36, duodenitis + chronic gastritis in 8, benign duodenal ulcer + chronic gastritis in 12, MAL Toma in 6 and gastric carcinoma in 4 patients. Godkhindi et al.^[14] found that 31-40 years old were the most frequently affected age group, accounting for 38 (34.54%) cases, followed by 21-30 years old with 24 (21.87%). Additionally, there were 1.89 times as many men as women present, with a mean age of 40.6 years. The presenting symptoms were varied, but abdominal (epigastric) pain was the most prevalent complaint, reported by 89 respondents (80.90%), followed by nausea in 62 cases (56.36%), dyspepsia in 40 cases (36.36%), weight loss in 20 cases (18.18%), reflux in 18 cases (16.36%), hematemesis in 12 cases (10.90%), and malaena in 7 cases (6.36%).

We found that *H. pylori* positivity in gastroduodenal lesions was seen in benign gastric ulcer + chronic gastritis in 6, chronic gastritis in 18, duodenitis + chronic gastritis in 2, benign duodenal ulcer + chronic gastritis in 3, MAL Toma in 2 and gastric carcinoma in 4 patients. On upper gastro-intestinal (GI) endoscopic biopsies, Sharma et al.^[15] evaluated the range of gastroduodenal lesions and the presence of *H. pylori* in the stomach mucosa in these lesions. A male to female ratio of 1.86:1 and an age range of 17 to 80 years were noted. The largest number of cases occurred in the fourth decade. The lesions that were most frequently seen were chronic gastritis, duodenitis, duodenal ulcers, and stomach cancer. In 5% of instances, the mucosa was unremarkable. In 47% of patients, *H. pylori* positive was noted. *H. pylori* infection was present in 80% of instances of duodenal ulcer, 68.75% of cases of duodenitis, 50.56% of cases of chronic gastritis, 50% of cases of gastric ulcer, and 40% of cases of gastric cancer.

Kothari et al.^[16] in their study, out of 200 cases of endoscopic biopsies received, 114 were males and 86 were females (M:F- 1.3:1). Majority were non-

neoplastic lesions comprising of 153 (76.5%) cases. Out of 38 (19%) malignant cases, oesophagus was the most common site comprising 78.9% and duodenum was the least common site comprising 10.5% of total malignancy. In duodenum 25% cases of celiac disease were also identified. Aprajita et al.^[17] in their study endoscopic biopsies from individuals who had an upper gastrointestinal tract lesion that required a biopsy were included in the current investigation. Twelve (16.66%) of the 72 upper GI endoscopic biopsy samples examined during a two-year period came from the oesophagus, 57 (79.17%) from the stomach, and three (4.17%) from the duodenum. Between the ages of 51 and 60, upper GI endoscopic lesions were most common. In the current study, the male to female ratio was 2.6:1, indicating a male predominance.

CONCLUSION

It was observed that the most often identified gastroduodenal lesion was chronic gastritis, which was followed by duodenitis, duodenal ulcers, and gastric cancer.

REFERENCES

1. Mustapha SK, Ajayi NA, Nggada HA, Pindiga UH, Bolori MT, Ndahi A, et al. Endoscopic findings and the frequency of *Helicobacter pylori* among dyspeptic patients In North-Eastern Nigeria. *Highland Med Res J.* 2007;5(1):78-81.
2. Bhaty SA, Shaikh NA, Zahir N, Akhter SS, Vaswani AS, Manzoor H. Histopathologic spectrum of upper GI endoscopies. *Med Channel.* 2009;15(4):11-4.
3. Jones DM, Lessels AM, Elridge J. *Campylobacter* like organisms on the gastric mucosa: culture, histological and serological studies. *J Clin Pathol.* 1984 Sep;37(9):1002-6.
4. Versalovic J. *Helicobacter pylori*. Pathology and diagnostic strategies. *Am J Clin Pathol.* 2003 Mar;119(3):403-12.
5. Blackstone MO. Endoscopic interpretation. In: Blackstone MO, eds. *Normal and Pathologic Appearances of the GI Tract.* 1st ed. New York: Raven Press; 1984: 13-15.
6. Godkhindi VM, Meshram DP, Deshpande SA, Kadam PN, Chavan YH. The histopathological study of various gastro-duodenal lesions and their association with *Helicobacter pylori* infection. *IOSR-JDMS.* 2013 Jan-Feb;4(3):51-5.
7. Kumar R, Bano G, Kapoor B, Sharma S, Gupta Y. Clinical profile in *H. pylori* positive patients in Jammu. *JK Sci.* 2006;8(3):148-50.
8. Adibfar P, Mirsalehian A, Ghofrani H, Alavi M, Ragabi A. The association of *Campylobacter pylori* (*Helicobacter pylori*) with gastritis and peptic ulcer. *Med J Islam Repub Iran (MJIRI).* 1991;5(1,2):19- 22.
9. Shah Sattar Khan, Asim Zulfiqar, K. F. Danish, Masood Sauwal, Shahid Bashir, Sharif-UZaman. *Rawal Med J* 2008; 33: 88-90.
10. Mustapha SK, Bolori MT, Ajayi NA, Nagada HA, Pindiga UH, Gashau W et al. Endoscopic findings and the frequency of *Helicobacter Pylori* among dyspeptic patients in North Eastern Nigeria, *The Internet Journal of Gastroenterology* 2007;1.
11. Ahsan K, Hossain MZ, Uddin MR. Role of crush cytology for the detection of *Helicobacter pylori* in gastroduodenal diseases. *J Dhaka Med Coll.* 2008;17(2):88-92.
12. Gulia SP, Chaudhury M, Noorunnisa N, Balakrishnan CD, Balagurunathan K. Interpretation of upper GI tract endoscopic mucosal biopsies - A study conducted in teaching hospital in Puducherry, India. *Int J Med Health Sci.* 2012 July;1(3):17-24.

13. Kadam P.N, R. Chavan Y.H, Shinde Aparna, Hanmante R.D. The histopathological study of gastroduodenal Biopsies and Helicobacter Pylori Infection in acid Peptic Disease Patients. *Journal of Evolution of Medical and Dental Sciences* 2013; 4883-4889.
14. Godkhindi VM, Meshram DP, Deshpande SA, Kadam PN, Chavan YH. The histopathological study of various gastroduodenal lesions and their association with Helicobacter pylori infection. *IOSR-JDMS*. 2013 Jan-Feb;4(3):51-5.
15. Sharma P, Kaul KK, Mahajan M, Gupta P. Histopathological Spectrum of various gastroduodenal lesions in North India and prevalence of Helicobacter pylori infection in these lesions: A prospective study. *Int J Res Med Sci* 2015;3:1236-41.
16. Kothari SL, Dayal A, Patel SM. Interpretation of Upper Gastrointestinal Tract Mucosal Biopsies–A Tertiary Care Centre Experience. *Annals of Pathology and Laboratory Medicine*. 2018;5(8).
17. Aparajita A, Mohanty RC, Sahu AA, Mohanty R, Satpathy PK, Bhuyan T. Histomorphological study of upper GI endoscopic biopsies. *Int J Health Sci Res*. 2016;6(12):59-64..