

A CROSS SECTIONAL STUDY ON MORPHOLOGIC VARIATIONS OF CORPUS CALLOSUM & ITS EMBRYOLOGICAL CORRELATION IN NORTH KARNATAKA REGION

Manisha Sachin Chougule¹, Drakshayini B Kokati¹, Preetam Patil², Pooja Nimbal³

Received : 31/08/2022

Received in revised form : 05/10/2022

Accepted : 18/10/2022

Keywords:

Agenesis, dysgenesis, lipoma, intracranial cyst, glial cells, midline sling.

Corresponding Author:

Dr. Manisha Sachin Chougule,
Email: drmanishasc23@gmail.com
ORCID: 0000-0001-6352-5945

DOI: 10.47009/jamp.2022.4.5.172

Source of Support: Nil,
Conflict of Interest: None declared

Int J Acad Med Pharm
2022; 4 (5); 828-832



¹Associate Professor, Department of Anatomy, KLE's JGMM Medical College, Hubli, Karnataka, India.

²Professor, Department of Radiodiagnosis, SDM college of Medical Sciences & Hospital, SDM University, Dharwad, India

³Post Graduate Student, SDM college of Medical Sciences & Hospital, SDM University, Dharwad, India.

Abstract

Background: Corpus callosum links the wide areas of cerebral cortex of two hemispheres & consist of approximately 2-3% of all cortical fibers. Glial cell has a significant role in the development of corpus callosum. Migratory neurons will form a midline sling so that callosal axons grow to reach the contralateral hemisphere. Absence or damage to glial cells & midline sling can result in agenesis of corpus callosum. The present study is done to find out association between the corpus callosum abnormalities with other brain anomalies and enlist the different morphological variations of corpus callosum. **Materials and Methods:** We searched through medical records from 2013 to 2022 for magnetic resonance imaging (MRI) images of patients with labelled diagnosis of agenesis of corpus callosum (Ag CC) of 0-78 years age groups. Out of 31 patients, 23 patients were meeting inclusion criteria and were included in the study. **Result:** Partial agenesis was observed in 16 cases & complete agenesis in 7 cases. Ag CC associated with suboccipital meningoencephalocele (N=1, 4.6%), lipoma (N=2, 8.6%), cyst (N=3, 13%), Dandy- Walker malformation (N=1, 4.3%), hippocampal malformation (N=1, 4.3%), colpocephaly (N=2, 8.6%) & white matter abnormalities (N=1, 4.3%). **Conclusion:** Approximately 50% cases of agenesis of corpus callosum were associated with some intracranial brain anomalies while other 50% were having isolated agenesis of corpus callosum.

INTRODUCTION

The Corpus callosum is one of the largest neo pallial commissure.^[1] It links the wide areas of cerebral cortex of two hemispheres, except the fibers from the primary visual area and hand & foot somesthetic area.^[2] It consists of about 300 million myelinated fibers, approximately 2-3% of all cortical fibers.^[2,3] Corpus callosum (CC) keeps the two hemispheres of brain working together and allows transfer of learning process, speech function and also integrates the sensory, motor & cognitive information.^[4] Anatomically it has four components. The rostrum fibers connecting the orbital surfaces of frontal lobes, the genu fibers forms forceps minor connecting lateral & medial surfaces of frontal lobes. The trunk fibers intersect projection fibers & connect wide neocortical areas. The splenium fibers forms forceps major connecting occipital lobes.^[1]

At 6 weeks of gestation formation of corpus callosum takes place, during which axons destined to cross the midline can be seen growing medially within the hemisphere. The fibers cross the midline through mass commissuralis at 11-12 weeks of gestation to form corpus callosum. Generally, axon tracts form according to a conserved ontogenic sequence. They develop under the guidance of non-neural substrate cells like glia. Glial cell populations mainly "Midline Zipper Glial" & "Glial Wedge" are identified and found to have a significant role in the development of corpus callosum.^[5,6,7,8] A structure called "midline sling" consisting of migratory neurons will form a midline bridge so that callosal axons grow to reach the contralateral hemisphere.^[9] Hence the development of corpus callosum depends on series of highly regulated complex development events which begins at time of gestation & continues to adulthood.^[10,11] Any disturbances in one or more of these events and absence or damage

to glial cells, midline sling can result in agenesis of corpus callosum.^[12] Among the congenital brain defects, agenesis of corpus callosum is the most common with occurrence of 1.4 - 1.8 per 10,000 live births.^[13,14] Morphologically two types of agenesis of CC have been identified. In type 1- corpus callosal axons are formed, but do not cross the midline, they form aberrant fiber bundles of Probst and in type 2- corpus callosal axons are not formed.^[3] Based on Mid sagittal M R imaging three morphological variants have been described like complete agenesis, partial agenesis and hypoplastic corpus callosum. Complete agenesis – in this type all components of corpus callosum are lacking. Partial agenesis – in this type absence of some components of corpus callosum is seen. Hypoplastic corpus callosum – in this type it is thin but structurally intact.^[15]

Disorders of corpus callosum can occur as an isolated case or may be associated with cranial (brain) and extracranial malformations with context of a congenital syndrome. About 10% of cases cause of Ag CC is associated with genetic disorder and 20-35% have specific monogenic or polygenic disorders related to teratogenic infectious, toxic or metabolic exposures.^[16] Despite gross anatomical consequences the spectrum of neurological manifestations varies from severe intellectual disability to normal intelligence.^[17] In individuals with isolated Ag CC subtle neuropsychological alterations happen when the cognitive demand increases as the age advances.^[18,19] Hence requiring long term follow up with essential neuropsychological screening. The present study is done to find out association between the corpus callosum abnormalities with other brain anomalies and enlist the different morphological variations of corpus callosum.

MATERIALS AND METHODS

The present cross-sectional study was conducted by collecting and observing brain MRI images from medical records of hospital. Institutional Ethical Committee approval was taken to conduct the study. MRI images of patients visited between 2013 to 2021 were collected from medical records. All images of patients were stored in PAX database, which can be accessed for conduction of any clinical research study.

Inclusion criteria

All patients with age ranged from 0-78 years with recorded diagnosis of AgCC were included in the study.

Exclusion criteria

Patients with secondary causes of callosal anomalies like congenital hydrocephalus, stroke & metabolic disorders were excluded.

RESULTS

Suitable descriptive and inferential statistics were used. Data is represented in the form of frequencies and percentages. 31 cases with labelled diagnosis of Ag CC were obtained from records. Out of which, 8 were excluded; 5 cases excluded due to non-availability of MRI images, one case was excluded because AgCC was secondary to ventriculomegaly, in two cases holoprosencephaly was the cause for AgCC. Remaining 23 cases were included in the study. In 23 cases images were reviewed. Partial agenesis was observed in 16 cases & complete agenesis in 7 cases. Ag CC associated with suboccipital meningoencephalocele (N=1, 4.6%), lipoma (N=2, 8.6%), cyst (N=3, 13%), Dandy-Walker malformation (N=1, 4.3%), hippocampal malformation (N=1, 4.3%), colpocephaly (N=2, 8.6%) & white matter abnormalities (N=1, 4.3%).

Table 1: shows pie frequency of results

| | Frequency | percentage |
|---------------------------|-----------|------------|
| Meningoencephalocele | 1 | 9.1 |
| Lipoma | 2 | 18.2 |
| Cyst | 3 | 27.3 |
| Dandy walker malformation | 1 | 9.1 |
| Hippocampal malformation | 1 | 9.1 |
| Colpocephaly | 2 | 18.2 |
| White matter malformation | 1 | 9.1 |
| | 11 | 100.0 |

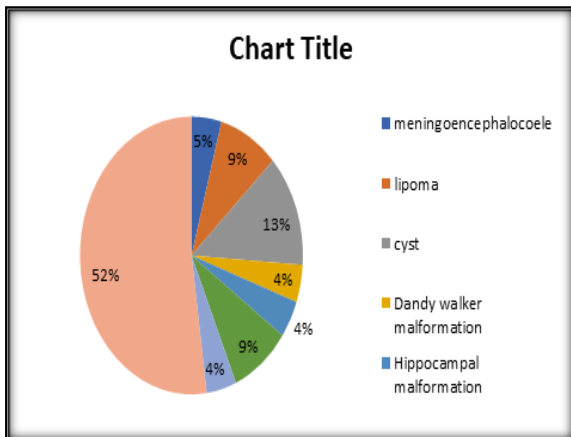


Figure 1: shows pie chart of results

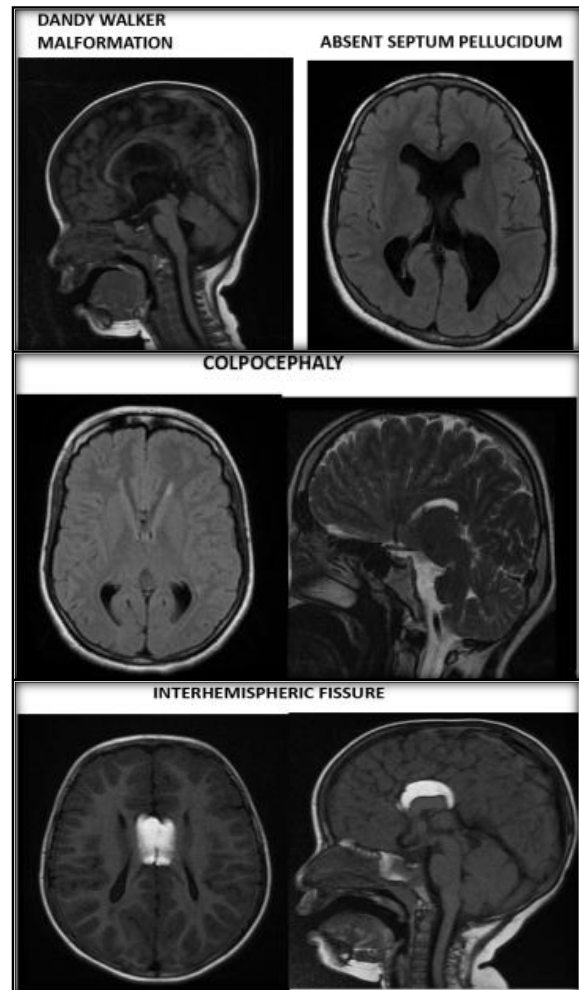
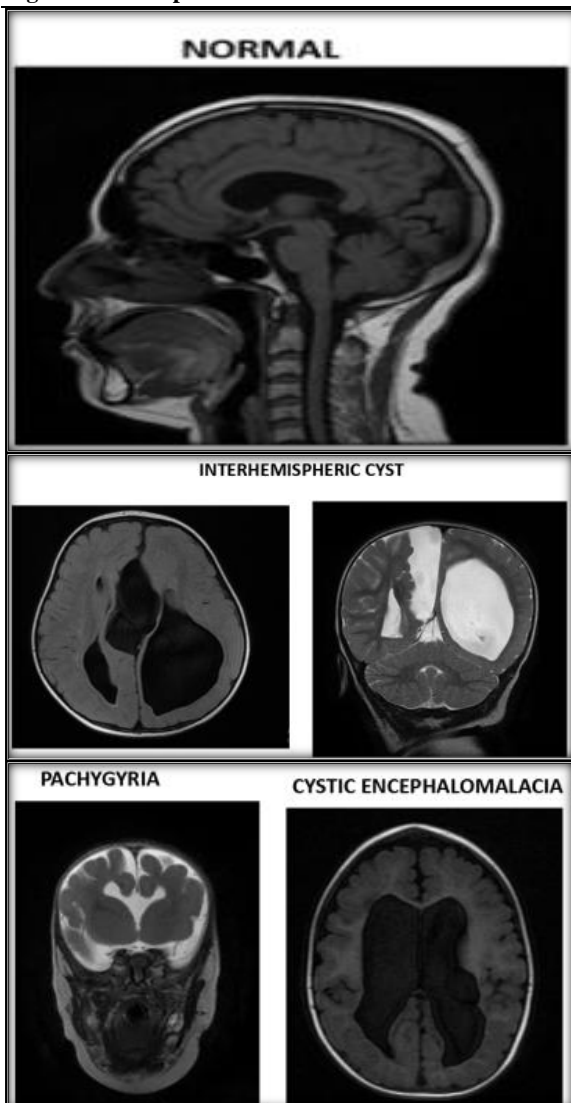


Figure 2: shows pictures of normal and different conditions

DISCUSSION

The most common congenital malformations observed in humans is agenesis of corpus callosum.^[12]

The estimated prevalence is 3-7 per 1000 birth in general population, & 2-3 per 100 in children with development disabilities.^[20] Most of the cases of AgCC were discovered by chance while investigating some other related disorders.^[21] The preponderance of male: female ratio in adults is 2:1, in children it is 3:2.^[22] In about 70% of cases of complete isolated agenesis of corpus callosum, the causative condition remains unknown. In 10% of cases of Ag CC have chromosomal anomalies mainly trisomies 8, 13, & 18, while in 7% of Ag CC are due to foetal alcohol syndrome. About 20-35% have specific monogenic or polygenic disorders.^[16] Congenital CNS anomalies commonly associated with Ag CC are holoprosencephaly, grey matter heterotopia, Arnold Chiari II malformation & Dandy-walker syndrome.^[23] Other development disorders found associated with Ag CC are interhemispheric cysts, cleft palate, Andermann syndrome & Apert syndrome.^[24,25] Tang et al described apparent delayed sulcation in review of 29

cases of foetal Ag CC. They also described sulcal delay in fetuses before 30 weeks of gestation & no such detectable sulcal delay in more than 30 weeks of gestation. They presented a case of sulcal delay at 26.4 weeks which eventually turn out to be normal for age.^[26] According to clinical & neurocognitive characteristics, patients with Ag CC can be classified into three groups. In first group patients have severe neurocognitive symptoms & very low IQ. In second group Ag CC play a major role as a causative factor for neurodevelopmental diseases. In third group patients are neurologically asymptomatic with normal IQ.^[17] Diagnostic approach to Ag CC during prenatal period by performing USG between 18 & 22 weeks. Ideally this can be supplemented with structural USG & prenatal MRI of brain. In addition to this repeat Brain MRI & amniocentesis for screening chromosomal disorder & congenital infections.^[17] During post-natal period approach by multidisciplinary team with complete medical history, physical examination & imaging of all systems like cardiovascular, respiratory, gastrointestinal & urinary system. Asymptomatic cases of Ag CC require follow up as they are bound to develop mild behavioral & cognitive deficits during early adulthood.^[18] Symptomatic cases require rehabilitation. According to recent studies on sigmoid bundle found out that interhemispheric connections can be rerouted.^[27,28] In a recent study it is been confirmed that Ag CC has better outcome if it is not associated with other congenital brain malformations.^[29] Some studies have reported worse outcomes in cases of Ag CC where as multiple studies reported no difference in behavioral & medical outcomes on comparing partial & complete Ag CC.^[16,30,31] Advantage of rehabilitative treatment is on long run it may modify neurological pathways through CNS plasticity. Rehabilitative treatment can give a special specific exercise & a suitable environment to improve structural & functional brain adaptation. Parents & teachers of affected children should be counselled to help them overcome neuropsychological deficits with adequate strategies.^[20]

CONCLUSION

Even though most of the cases of Ag CC are asymptomatic but requires regular follow up to track the late manifestations. As Ag CC is not always associated with other brain anomalies early recognition of problems and timely intervention can be done with appropriate rehabilitative measures.

REFERENCES

- Velut S, Destrieux C, Kakou M. Morphologic anatomy of the corpus callosum. *Neurochirurgie*. 1998;44(1 Suppl):17-30.
- Ota M, Obata T, Akine Y, Ito H, Ikehira H, Asada T, Suhara T. Age-related degeneration of corpus callosum measured with diffusion tensor imaging. *Neuroimage*. 2006;31(4):1445-52. doi: 10.1016/j.neuroimage.2006.02.008.
- Schell-Apacik CC, Wagner K, Bihler M, Ertl-Wagner B, Heinrich U, Klopocki E, et al. Agenesis and dysgenesis of the corpus callosum: clinical, genetic and neuroimaging findings in a series of 41 patients. *Am J Med Genet A*. 2008;146A(19):2501-11. doi: 10.1002/ajmg.a.32476.
- Wahl M, Lauterbach-Soon B, Hattingen E, Jung P, Singer O, Volz S, et al. Human motor corpus callosum: topography, somatotopy, and link between microstructure and function. *J Neurosci*. 2007;27(45):12132-8. doi: 10.1523/JNEUROSCI.2320-07.2007.
- Holley JA. Early development of the circumferential axonal pathway in mouse and chick spinal cord. *J Comp Neurol*. 1982;205(4):371-82. doi: 10.1002/cne.902050406.
- Nordlander RH, Singer M. Spaces precede axons in *Xenopus* embryonic spinal cord. *Exp Neurol*. 1982; 75:221-228.
- Norris CR, Kalil K. Guidance of callosal axons by radial glia in the developing cerebral cortex. *J Neurosci*. 1991;11(11):3481-92. doi: 10.1523/JNEUROSCI.11-11-03481.1991.
- Shu T, Richards LJ. Cortical axon guidance by the glial wedge during the development of the corpus callosum. *J Neurosci*. 2001;21(8):2749-58. doi: 10.1523/JNEUROSCI.21-08-02749.2001.
- Silver J. Glia-neuron interactions at the midline of the developing mammalian brain and spinal cord. *Perspect Dev Neurobiol*. 1993;1(4):227-36.
- Silver J, Lorenz SE, Wahlsten D, Coughlin J. Axonal guidance during development of the great cerebral commissures: descriptive and experimental studies, in vivo, on the role of preformed glial pathways. *J Comp Neurol*. 1982;210(1):10-29. doi: 10.1002/cne.902100103.
- Rakic P, Yakovlev PI. Development of the corpus callosum and cavum septi in man. *J Comp Neurol*. 1968;132(1):45-72. doi: 10.1002/cne.901320103.
- Dobyns WB. Absence makes the search grow longer. *Am J Hum Genet*. 1996;58(1):7-16.
- Jeret JS, Serur D, Wisniewski K, Fisch C. Frequency of agenesis of the corpus callosum in the developmentally disabled population as determined by computerized tomography. *Pediatr Neurosci*. 1985-1986;12(2):101-3. doi: 10.1159/000120229.
- Glass HC, Shaw GM, Ma C, Sherr EH. Agenesis of the corpus callosum in California 1983-2003: A population-based study. *Am J Med Genet Part A*. 2008;146(19):2495 – 500.
- Hetts SW, Sherr EH, Chao S, Gobuty S, Barkovich AJ. Anomalies of the corpus callosum: an MR analysis of the phenotypic spectrum of associated malformations. *AJR Am J Roentgenol*. 2006;187(5):1343-8. doi: 10.2214/AJR.05.0146.
- Bedeschi MF, Bonaglia MC, Grasso R, Pellegri A, Garghentino RR, Battaglia MA, et al. Agenesis of the corpus callosum: clinical and genetic study in 63 young patients. *Pediatr Neurol*. 2006;34(3):186-93. doi: 10.1016/j.pediatrneurol.2005.08.008.
- Guadarrama-Ortiz, P., Choreño-Parra, J.A. & de la Rosa-Arredondo, T. Isolated agenesis of the corpus callosum and normal general intelligence development during postnatal life: a case report and review of the literature. *J Med Case Reports* 14, 28 (2020).
- Brown WS, Paul LK. The Neuropsychological Syndrome of Agenesis of the Corpus Callosum. *J Int Neuropsychol Soc*. 2019;25(3):324-330. doi: 10.1017/S135561771800111X.
- Lábadi B, Beke AM. Mental State Understanding in Children with Agenesis of the Corpus Callosum. *Front Psychol*. 2017;8:94. doi: 10.3389/fpsyg.2017.00094.
- Chiappedi, M., Bejor, M. Corpus callosum agenesis and rehabilitative treatment. *Ital J Pediatr* 36, 64 (2010).
- Taylor M, David AS. Agenesis of the corpus callosum: a United Kingdom series of 56 cases. *J Neurol Neurosurg Psychiatry*. 1998 Jan;64(1):131-4. doi: 10.1136/jnnp.64.1.131. PMID: 9436744; PMCID: PMC2169913.
- Serur D, Jeret JS, Wisniewski K. Agenesis of the corpus callosum: clinical, neuroradiological and cytogenetic studies.

- Neuropediatrics. 1988;19(2):87-91. doi: 10.1055/s-2008-1052407.
23. Coakley FV, Glenn OA, Qayyum A, Barkovich AJ, Goldstein R, Filly RA. Fetal MRI: a developing technique for the developing patient. *AJR Am J Roentgenol.* 2004;182(1):243-52. doi: 10.2214/ajr.182.1.1820243.
 24. Landin-Romero R, Amann BL, Sarró S, Guerrero-Pedraza A, Vicens V, Rodriguez-Cano E, et al. Midline Brain Abnormalities Across Psychotic and Mood Disorders. *Schizophr Bull.* 2016;42(1):229-38. doi: 10.1093/schbul/sbv097.
 25. Renier D, Arnaud E, Cinalli G, Sebag G, Zerah M, Marchac D. Prognosis for mental function in Apert's syndrome. *J Neurosurg.* 1996;85(1):66-72. doi: 10.3171/jns.1996.85.1.0066.
 26. Tang PH, Bartha AI, Norton ME, Barkovich AJ, Sherr EH, Glenn OA. Agenesis of the corpus callosum: an MR imaging analysis of associated abnormalities in the fetus. *AJNR Am J Neuroradiol.* 2009;30(2):257-63. doi: 10.3174/ajnr.A1331.
 27. Brown WS, Jeeves MA, Dietrich R, Burnison DS. Bilateral field advantage and evoked potential interhemispheric transmission in commissurotomy and callosal agenesis. *Neuropsychologia.* 1999;37(10):1165-80. doi: 10.1016/s0028-3932(99)00011-1.
 28. Tovar-Moll F, Moll J, de Oliveira-Souza R, Bramati I, Andreuolo PA, Lent R. Neuroplasticity in human callosal dysgenesis: a diffusion tensor imaging study. *Cereb Cortex.* 2007;17(3):531-41. doi: 10.1093/cercor/bhj178.
 29. Sztriha L. Spectrum of corpus callosum agenesis. *Pediatr Neurol.* 2005;32(2):94-101. doi: 10.1016/j.pediatrneurol.2004.09.007.
 30. Goodyear PW, Bannister CM, Russell S, Rimmer S. Outcome in prenatally diagnosed fetal agenesis of the corpus callosum. *Fetal Diagn Ther.* 2001;16(3):139-45. doi: 10.1159/000053898.
 31. Volpe P, Paladini D, Resta M, Stanziano A, Salvatore M, Quarantelli M, et al. Characteristics, associations and outcome of partial agenesis of the corpus callosum in the fetus. *Ultrasound Obstet Gynecol.* 2006;27(5):509-16. doi: 10.1002/uog.2774.