

COMPARATIVE STUDY OF PRIMARY ASARP WITH STAGED ASARP WITH PROTECTIVE COLOSTOMY, IN FEMALE PATIENTS WITH VESTIBULAR FISTULAS

Vikram Dantoori¹, K. V. Sathyanarayana², M. Santhi³, Mandakini K.T⁴

¹Assistant Professor, Department of Pediatric Surgery, Osmania Medical College, Hyderabad, Telangana, India.

²Associate Professor, Department of Pediatric Surgery, Osmania Medical College/ Niloufer Hospital for women and children, Hyderabad, Telangana, India.

³Associate Professor, Department of General Surgery, Osmania Medical College/Osmania general hospital, Koti, Hyderabad, Telangana, India.

⁴Assistant Professor, Department of Pediatric Surgery, Osmania Medical College, Hyderabad, Telangana, India.

Received : 30/03/2022
Received in revised form : 08/07/2022
Accepted : 19/07/2022

Keywords:

Vestibular Fistulas, Female Anorectal Malformations Limited PSARP, ASARP, Single stage repair, Two Stage repair.

Corresponding Author:

Dr. Mandakini K.T.

Email:

drsathyanarayanmbbsmdped@gmail.com

ORCID: 0000-0003-3977-3003

DOI: 10.47009/jamp.2022.4.3.57

Source of Support: Nil.

Conflict of Interest: None declared

Int J Acad Med Pharm,
2022; 4 (3); 251-255



Abstract

Background: Anorectal malformation is a common congenital anomaly found in the pediatric population. A number of surgical procedures have been devised for the correction of the anomaly. The aim is to design a selection criterion to choose primary ASARP or staged repair with protective colostomy and ASARP in females with low Anorectal Malformation by comparing the results in both approaches. **Materials and Methods:** This is a Prospective study done over 2yrs, in the department of Pediatric Surgery in all cases of Low Anorectal Malformations in female children. Sample size is 30 cases, and all cases documented based on age, clinical examination, site of the fistula/anus, DE compressibility, Perineal skin excoriation and routine blood investigations. **Result:** 30 cases of female low ARM Vestibular Fistulas. Out of 30 (n=30) cases, primary ASARP performed in 20 patients and staged ASARP in 10 patients. In Primary ASARP Vestibular fistula in 8 cases were neonates; 3 cases were infants and 1 case is of >1year, anteriorly placed anus / ectopic anus in all 8 cases are infants. In staged ASARP Vestibular fistula in 4 cases were neonates and 3 cases were infants. Anteriorly placed anus / ectopic anus in 2 cases are infants and 1 case >1year age. In primary procedure vaginal trauma occurred in 4cases that comes to 20% and rectal trauma in 2cases i.e. 10%. both injuries repaired with 4-0 vicryl sutures. Postoperatively in primary ASARP cases wound infection occurred in 3 cases (15%), 1case healed spontaneously, 2cases had wound dehiscence in which, 1 case required secondary suturing and 1 case went for colostomy as diversion procedure. Mucosal ectropion seen in 1 case of staged ASARP which got reduced spontaneously. In both procedures, 1 case (5%) each had soiling which is GARDE 1 according to Pena grading. Only 3 cases (15%), postoperatively had constipation out 20 cases of primary procedure. One case (10%) had constipation in staged ASARP. Three cases (15%) of primary and 1(10%) of staged ASARP had perineal excoriation. **Conclusion:** Primary ASARP is simple one stage procedure for low ARM in females irrespective of age at presentation, including the newborn babies if selected appropriately.

INTRODUCTION

Anorectal malformation is a common cause of intestinal obstruction in children and newborn. The incidence is 1:4000-5000 live births worldwide, could vary in Indian patients.^[1] Vestibular fistula is a type of perineal fistula, that constitutes the commonest Anorectal Malformation (ARM) in the

female children. Pediatric patients with recto/anovestibular fistula have good prognoses in terms of bowel function when properly treated. The bowel opens immediately behind the hymen in the vestibule of the female genitalia. Immediately above the fistula, rectum and vagina are separated by a thin common wall. These patients usually have well-developed muscles and a normal sacrum and nerves.

The conventional surgical treatment has not always been satisfactory which include, perineal anal transplant, YV-plasty, sacro-perineal repair, and colostomy followed by minimal posterior sagittal ano-rectoplasty (PSARP). These procedures have been limited by incomplete anatomic exposure, blind tunneling of the perineum, lack of reconstruction of the perineal body, need for a colostomy, and anterior migration of the anus in the long term. These limitations have been well countered by ASARP.

The optimal surgical repair should allow easy access to the fistula, minimize the dissection to spare pelvic nerves, guide the rectal pouch through all the muscles of continence, restore a physiological anorectal angle, create good anal opening and take advantage of all existing structures. Most contemporary techniques attempt to preserve the major elements of continence, often at the cost of "Lesser" factors, increased dissection or poorer exposure.^[2]

By the reference to the idea of this operative procedure, devised a new approach, Anterior Sagittal Ano-Rectoplasty (ASARP) for repair of a vestibular fistula, with the patient in lithotomy position, sphincter muscles are divided from the anterior aspect sagittally through a median perineal skin incision and then the rectum is passed through the central portion of the sphincter muscle.^[3] A number of pediatric surgeons repair this defect, primarily without a protective colostomy.^[4] This study was planned to analyze the results of ASARP as single stage procedure without the need of colostomy, at the same time comparing the results of ASARP done with a protective colostomy, in the management of low ARM in female children.

MATERIALS AND METHODS

This is a Prospective study done between 2015 December to 2017 November over 2yrs, in the department of Pediatric Surgery, Niloufer hospital, Institute women and child health. Osmania Medical College, Hyderabad, Telangana State. Target Population is all cases of Low Anorectal Malformations in female children. Sample size is 30 cases, and all cases documented based on age, clinical examination, site of the fistula/anus, DE compressibility, Perineal skin excoriation and routine blood investigations.

Contrast enema X-rays were done in all cases to look for bowel ectasia and fistula track with water soluble contrast. Two X-rays, AP and Lateral views are taken. Ectasia was defined as dilatation of the pelvic portion of the colon when compared to the caliber of proximal bowel, and described as mild, moderate, and severe. moderate ectasia is described when dilatation is less than half of pelvis and, gross when occupying entire pelvis. Depending up on the bowel ectasia and perineal excoriation, decision was taken regarding Primary vs Staged ASARP. Primary

ASARP done in 20 cases (67%) with no bowel ectasia and no perineal excoriation. Staged ASARP done in 10 cases (33%) with mild/mod ectatic bowel or/and perineal excoriation, who underwent initial diversion left pelvic loop colostomy at the time of presentation to Niloufer hospital. Later ASARP done after 3months and colostomy closure after further 3 more months consequently.

All cases were evaluated for associated anomalies and syndromes. Intra operative, postoperative complications are taken into study. All cases were kept on anal calibration and dilatation programme as per the standard norms from 2nd week on wards. All cases were followed up with timely intervals and looked for stool pattern, soiling, anus, constipation, frequency of stools and perineal excoriation.

This study is done to design a selection criterion in choosing primary over staged procedure in females with low ARM Vestibular Fistulas in order to achieve better results.

RESULTS

This prospective study was done at the Department of Pediatric Surgery, Niloufer Hospital, Osmania Medical College over a period of 24 months i.e. from December 2015 to November 2017, that includes 30 cases of female low ARM Vestibular Fistulas. Out of 30 (n=30) cases, primary ASARP performed in 20 patients and staged ASARP in 10 patient.

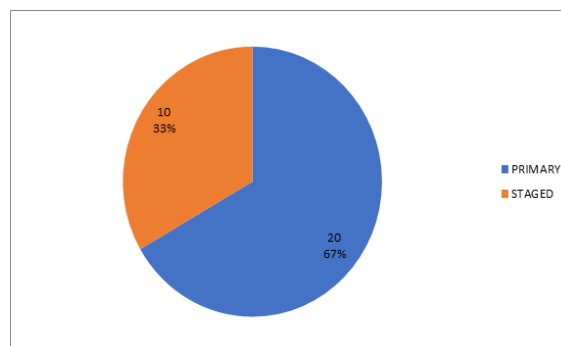


Figure 1: ASARP done in primary and staged bowel perineal skin excoriation in present study

Primary ASARP done in 20 cases (67%) with no bowel ectasia and no perineal skin excoriation.

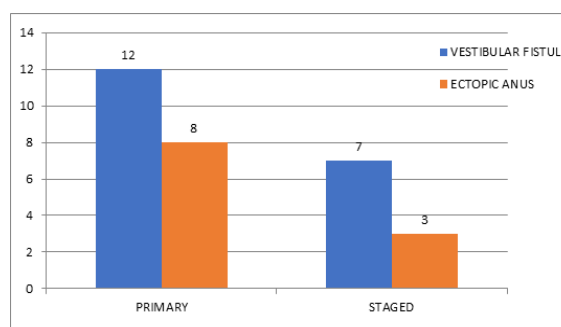


Figure 2: Primary ASARP and staged procedure having vestibular fistula and ectopic anus.

Staged ASARP done in 10 cases (33%) with mild/mod ectatic bowel with or without perineal skin excoriation, who underwent initial pelvic loop diversion colostomy at time of presentation to Niloufer hospital. Later ASARP after 3months and colostomy closure after 3month consequently. In total of 20 cases operated as primary ASARP 12(60%) had vestibular fistula and 8(40%) cases are of anteriorly placed anus/ ectopic anus In case of staged procedure 10 cases were operated, in which 7(70%) had vestibular fistula and 3(30%) cases are of anteriorly placed anus/ ectopic anus.

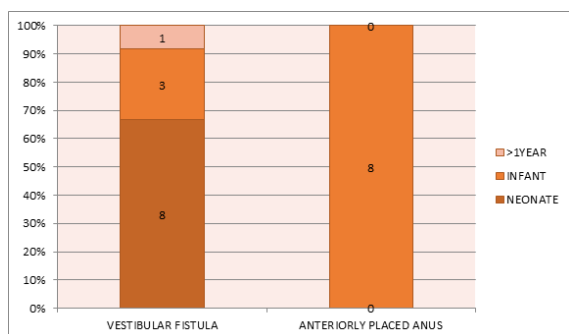


Figure-3: Age at presentation: primary ASARP

Vestibular fistula: 8 cases were neonates; 3 cases were infants and 1 case is of >1year Anteriorly placed anus / ectopic anus: all 8 cases are infants.

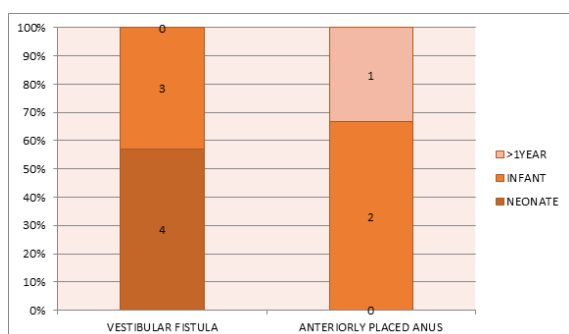


Figure 4: Age at presentation staged

Vestibular fistula: 4 cases were neonates and 3 cases were infants Anteriorly placed anus / ectopic anus: 2 cases are infants and 1 case >1year age

Table 1: Intra Operative and Post-Operative Complications

ASARP	Vaginal Injury	Rectal Injury
Primary	4	2
Staged	0	0
Post Operative Complications		
Wound Infection	3	0
Wound Dehiscence	2	0
Stoma	1	0
Mucosal Ectropion	0	1

In primary procedure vaginal trauma occurred in 4cases that comes to 20% and rectal trauma in 2cases i.e. 10%. both injuries repaired with 4-0

vicryl sutures. Postoperatively in primary ASARP cases wound infection occurred in 3 cases (15%), 1case healed spontaneously, 2cases had wound dehiscence in which, 1 case required secondary suturing and 1 case went for colostomy as diversion procedure. Mucosal ectropion seen in 1 case of staged ASARP which got reduced spontaneously.

Table 2: Soiling With Stools and Perineal Skin Excoriation

Soiling With Stools	Primary	Staged
Soiling	1(<2/Week)	1(<2/Week)
Perineal Skin Excoriation	3	1

In both procedures, 1 case (5%) each had soiling which is GARDE 1 according to Pena grading. Only 3 cases (15%), postoperatively had constipation out of 20 cases of primary procedure. One case (10%) had constipation in staged ASARP. Three cases (15%) of primary and 1(10%) of staged ASARP had perineal excoriation.

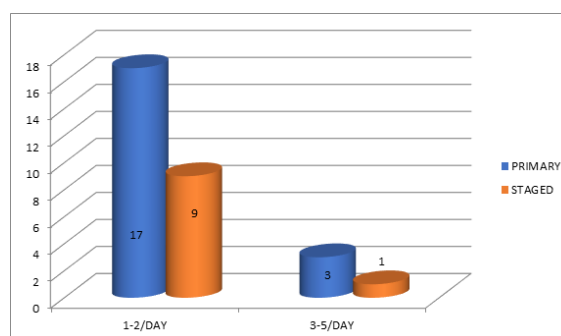


Figure 5: Frequency of stools

In primary procedure 17 cases (85%) and 9 cases (90%) of staged had 1-2 stools/day. Three cases (15%) of primary and 1 case (10%) of staged ASARP had 3-5 stools/day.

DISCUSSION

Although the pathological anatomy of infra-levator anorectal malformations has been well described, the conventional treatment has not always been satisfactory. The previously used surgical techniques include cutback (Stephens and Smith), perineal anal transplantation, Y-V and X-Z plasty (Chatterjee), colostomy followed by minimal PSARP (Pena and deVrie), and sacro-perineal repair (Stephens and Smith'). These procedures were limited by incomplete anatomical exposure, blind tunneling of the perineum, lack of reconstruction of the perineal body, need for a colostomy, and a displeasing appearance of the perineum, with anterior migration of the anus in the long term.^[1] These disadvantages have been offset by Anterior Sagittal Ano-Recto-Plasty (ASARP), colostomy is obviated, mobilization of the rectum is under vision, only the anterior aspect of the sphincteric muscle complex is divided, and the continence mechanism is well preserved. Additionally, the operation allows

placement and anchoring of the mobilized rectum within the muscle complex; the sphincteric muscle and the perineal body are accurately approximated, and a normal perineum is reconstructed. ASARP can be performed even in neonates. In children older than 1 year, blood loss may require replacement. The extensive preoperative and postoperative measures advocated by Okada et al have not been required for any of our patients.^[5,6,7]

Chaterjeel advocates use of a colostomy if the patient is over 5 years of age or in cases of megarectum or a small fistula that prevents adequate bowel preparation.^[5] Preliminary colostomies were used in 10 of our patients, who had mild to moderate ectatic bowel and/or perineal excoriation. The other 20 cases underwent primary ASARP. The management of perineal ectopic anus is controversial. It has been suggested that a posterior ledge is responsible for the intractable constipation. Potts et al described the widely used technique of anal transplantation, and a two-flap technique was described by Abeyrante.

Upadhyaya⁸ proposed that the middle loop of the external sphincter was absent in these patients. Bulging of the unsupported posterior wall of the anal canal at this location during defecation caused fecal impaction and constipation. He advised complete division of the posterior wall of the anal canal, up to the level of the normal thickness of the bowel. We believe that the posterior ledge and the constipation from fecal impaction behind it are caused by the anterior shift in the position of the anus. We have not found any deficiency in the posterior wall of the anal canal during ASARP. It has been proven conclusively that the sphincter muscle complex, although made up of individual muscles, is a continuous sheet. It is difficult to explain the absence of the middle loop of the external sphincter in this context.

ASARP is simpler in these cases, and all our patients had a normal perineum and bowel habits after surgery. The results of ASARP have been gratifying in the present series. It appears that ASARP provides consistently good results in the treatment of vestibular fistula, perineal ectopic anus and other low ARM in females

In primary ASARP 4(20%) cases had vaginal injury and 2(10%) cases had rectal injury. postoperatively none of these cases had complications which shows that by keeping the child nil per oral for 5days, these injuries can be healed without any further complications.

Postoperatively 3(15%) cases had wound infection. Of which 2cases had wound dehiscence, 1 superficial and the other 1 had complete disruption of perineal body for which diversion colostomy with irrigation and re-suturing pf perineal body was performed. But no case required redo surgery. Wound healed well in both the cases even for the child who had colostomy as anoplasty was intact. After 3 months colostomy closure done in that child.

Table 3: Complications in comparison to other studies

Complications	Present Study	Shrivasthava Study, ^[9]	Wahklu Study, ^[10]
Wound Infection	20(4)	24(3)	414(2)
Wound Dehiscence	20(2)	24(2)	414(2)
Constipation	20(3)	24(3)	-

Mucosal ectropion in 1(10%) case of staged ASARP managed conservatively with no other complications.

All 30 children were continent, 28 children had no soiling, GRADE1 soiling was seen in 2 cases. 1case (5%) aged 11months of primary ASARP and 1case (10%) aged 2yr staged ASARP with ectopic anus had constipation with soiling which was managed with laxatives and anal dilatation and responded well without surgical intervention.

Three (15%) cases of primary ASARP had fibrotic anus post op which became supple on gradual dilatation with steroid cream

No true incontinence was seen in the study. Constipation was seen in 4 children,3 with vestibular fistula and 1 ectopic anus. Among which 3 underwent primary and 1 staged ASARP. Grade1 fecal soiling was seen in 2 cases, all of them responded well to dietary modification and stool softeners.

Our study also compared the results between the primary ASARP an staged ASARP with protective colostomy. The preoperative preparation and postoperative need of nil by mouth are very specific for primary cases. A 24hr NBM status and bowel preparation, and 4-5 days of postoperative NBM is mandatory for all primary cases. But these same requirements are even more demanding for closure of colostomy for those cases with protective colostomy and staged ASARP. Moreover with primary approach all the disadvantages, complications and social stigma of colostomy are negated by primary approach. There are no life threatening complications with primary repair except in one case of wound dehiscence, which needed diversion colostomy.

The criterion taken for selecting the cases for primary approach i.e., bowel ectasia and preoperative skin excoriation gave very good results when cases were selected carefully. The results of primary approach is similar to that of staged repair, preventing the need of two more surgeries of colostomy making and colostomy closure, and also free from all the colostomy associated complications.

The incidence of wound infection, dehiscence and constipation in our study is similar to that of Shrivasthav et al,^[9] complications such as recurrence of fistula leading to iatrogenic perineal canal, anal stenosis retraction of rectum, fecal impaction were not seen in our study as opposed to Serrano et al.^[10]

CONCLUSION

Primary ASARP is simple one stage procedure for low ARM in females irrespective of age at presentation, including the newborn babies if selected appropriately. The criterion taken for selecting the cases for primary procedure have given us an indication and confidence that these criterion can be standardized if done with larger case series. The overall outcome is similar in primary as compared staged ASARP. Primary ASARP obviates multiple admissions, surgeries and hospital stay. But in order to say one procedure is better than other one we need to have bigger clinical samples than this with longer follow up data analysis.

REFERENCES

1. Stephens FD, Smith ED. Classification, identification and assessment of treatment of anorectal anomalies. *Pediatr Surg Int.* 1986;1:200-5.
2. Pena A, Devries PA. Posterior sagittal anorectoplasty: important technical consideration and new applications. *J Pediatr Surg.* 1982;17:796-811.
3. Pena A, Hong A. Advances in the management of anorectal malformation. *Am J Surg.* 2000;108:370-6.
4. Holschneider AM, Jesch NK, Stragholz E, et al. Surgical methods for anorectal malformation from rehbein to pena: critical assessment of score systems and proposal for a new classification. *Eur J Pediatr Surg.* 2002;12:7382.
5. Ghosh S. Neonatal pustular dermatosis: an overview. *Indian J Dermatol.* 2015;60(2):211. doi: 10.4103/0019-5154.152558.
6. Okada A, Kamata S, Imura K, et al. Anterior sagittal anorectoplasty for rectovestibular and anovestibular fistula. *J Pediatr Surg.* 1992;27:85-8.
7. Okada A, Tamada H, Tsuji H, et al. Anterior sagittal anorectoplasty as a redo operation for imperforate anus. *J Pediatr Surg.* 1993;28:933-8.
8. Upadhyaya P. Mid anal sphincteric malformation, The cause of constipation in anterior perineal anus. *J Pediatr Surg.* 19:183- 196.1984.
9. Shrivastava D. Anorectal malformation female children one stage procedure ASARP. *J Evolution Med Dent Sci.* 2016;5(25):1339-1341.
10. Serrano Falcón B, Barceló López M, Mateos Muñoz B, Álvarez Sánchez A, Rey E. Fecal impaction: a systematic review of its medical complications. *BMC Geriatr.* 2016;16:4. doi: 10.1186/s12877-015-0162-5.